

Letters to the Editor

TIPS treatment in a patient with severe lower gastrointestinal bleeding with a misdiagnosis of cirrhotic portal hypertension

Key words: Abernethy malformations. Rectorrhagia. TIPS. Misdiagnosis.

Dear Editor,

We present a case of a 44-year-old man, with alcoholic habit and without other clinical data of interest. He was admitted into the hospital for repeated major rectal bleeding. His blood pressure was 100/65 mmHg with a heart rate of 115 bpm. Patient's medical history would suggest history of hepatic encephalopathy. The gastroscopy showed gastroesophageal varices grade I without active bleeding, and colonoscopy showed submucosal varices with bleeding in cecal region performing a sclerotherapy procedure. Despite the sclerotherapy, the patient kept bleeding from rectum. An abdominal CT revealed blood in the cecum, dilated superior mesenteric vein (SMV) and varices in cecal region. The patient had successive bleedings worsening his hemodynamic status; thereby a TIPS was performed. The hemodynamic study showed a portosystemic gradient pressure of 14 mmHg. One multipurpose 5 Fr catheter was used to embolize cecal varices with multiple Nester type oversize coils (Cook Medical Bloomington, USA) for SMV total occlusion.

Two days after the procedure the patient had rectal bleeding recurrence and a right hemicolectomy was performed with a liver biopsy. The pathological findings from the hepatic biopsy revealed mild inflammatory activity and centrilobular fibrosis

without cirrhosis. The AP from hemicolectomy reported angiodysplasia/venous hemangiomas in the colon wall. The patient recovered from the LGIB, and an intra-TIPS venography and angioCT were performed. A shunt side to side was observed from the SMV directly, or through the jejunal veins and the left renal vein, to the IVC (Fig. 1). Final diagnosis of type II Abernethy malformation was established.

Discussion

Congenital extrahepatic portosystemic shunts (CEPS) are a rare anomaly of the splanchnic vasculature in which portal venous blood has an anomalous drainage into systemic veins, most commonly the inferior vena cava (IVC). This malformation is also known as Abernethy malformation, in recognition of the English surgeon John Abernethy. He first described a case of a girl of 10 months of age with a congenital porto-systemic shunt with agenesis or atresia of the portal vein (1). Morgan and Suprina classified CEPS as type I and II (2). Lautz et al. established

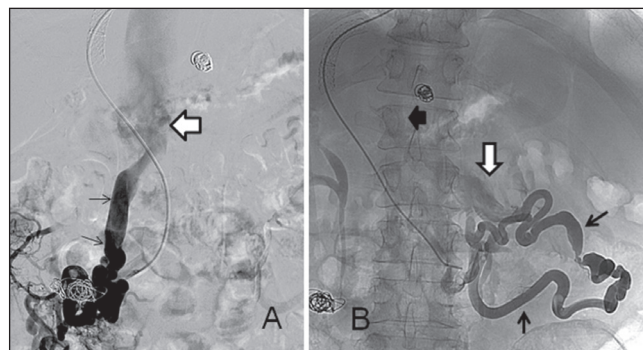


Fig. 1. A. Venography from SMV. The mesenteric-caval shunt (thin black arrows) is seen arriving to the IVC (black hollow arrow) B. Venography, also from the SMV (catheter). The mesenteric-renal shunt can be seen (black arrows) reaching the IVC (thick black arrow). The white arrow indicates the renal vein.

two groups type I CEPS without intrahepatic portal flow and type II CEPS preservation of at least some hepatic portal flow. They have subclassified type II as: Type IIa (the shunt arises from the portal vein), type IIb (the shunt arises from main portal vein, bifurcation or splenoportal confluence), and type IIc (the shunt arises from mesenteric, splenic or gastric veins) (3).

Ectopic varices, defined by large portosystemic venous collaterals occurring anywhere in the gastrointestinal tract, are less common and account for between 1% and 5% of all variceal bleeding (4,5). Bleeding from ectopic varices, which is rare in patients with portal hypertension, is generally massive and life threatening. The most common sites of colorectal varices are the rectum and the cecum. The treatment of colonic varices is not well defined. Several therapies, including percutaneous transhepatic obliteration (PTO), colonic resection, portacaval shunt construction, endoscopic procedures, TIPS, variceal embolization, and balloon-occluded retrograde transvenous obliteration (BRTO), have been reported.

Alicia Laborda, José Andrés Guirola, Joaquín Medrano,
Miguel Ángel Simón, Ignatios Ioakeim and
Miguel Ángel de-Gregorio

Grupo de Investigación en Técnicas de Mínima Invasión (GITMI). Universidad de Zaragoza. Zaragoza, Spain

References

1. Alhambra C, Morales VJ, Picazo J et al. Appendicitis granulomatosa: Abernethy J, Banks J. Account of two instances of uncommon formation in the viscera of the human body. *Phil Trans R Soc* 1793;83:59-66. DOI: 10.1098/rstl.1793.0010
2. Morgan G, Superina R. Congenital absence of the portal vein: Two cases and a proposed classification system for portosystemic vascular anomalies. *J Pediatr Surg* 1994;29:1239-41. DOI: 10.1016/0022-3468(94)90812-5
3. Lautz TB, Tantemsapya N, Rowell E, et al. Management and classification of type II congenital portosystemic shunts. *J Pediatr Surg* 2011;46:308-14. DOI: 10.1016/j.jpedsurg.2010.11.009
4. Sato T, Akaike J, Toyota J, et al. Clinicopathological features and treatment of ectopic varices with portal hypertension. *Int J Hepatol* 2011;960720. DOI: 10.4061/2011/960720
5. Alonso-Gamarra E, Parrón M, Pérez A, et al. Clinical and radiologic manifestations of congenital extrahepatic portosystemic shunts: A comprehensive review. *Radiographics* 2011;31:707-22. DOI: 10.1148/rg.313105070