

Follow-up of a new titanium-coated polyetheretherketone cage for the cervical spine

Ricardo Arregui,¹ José Aso,¹
 José-Vicente Martínez Quiñones,¹
 Cristina Sebastián,² Fabián Consolini,¹
 Alberto Aso Vizán^{3,4}

¹Department of Neurosurgery and Neurology, Hospital MAZ, Zaragoza;

²Department of Radiology, Hospital MAZ, Zaragoza; ³Department of Traumatology and Orthopedic Surgery, Hospital General de la Defensa, Zaragoza; ⁴Facultad de Medicina, University of Zaragoza, Spain

Abstract

Poly-ether-ether-ketone (PEEK) cages have lower modulus of elasticity when compared with Titanium (TTN) cages. This suggests that PEEK-cages could show a lower rate of subsidence after anterior cervical discectomy-fusion (ACDF) and might lead to a lower loss of correction. We investigated the one to five year-results of stand-alone PEEK-TTN-porous coated cages in a patient cohort from 2014 to 2017. The patients underwent single-level ACDF for disc herniation and degenerative discopathy. Clinical and radiological outcome were assessed in 50 eligible patients after a mean of 27 months. Results: Solid arthrodesis was found in 84%. Neck disability index (NDI), and visual analogue scale (VAS) of neck and arm show comparable results to the literature. Conclusions: Clinical and radiological outcomes of ACDF with PEEK-body-cages with a porous coated surface show good bony integration. The modulus of elasticity, design, shape, size, cage surface architecture, as well as bone density, endplate preparation, radical microdiscectomy and distraction during surgery should be considered as important factors influencing the clinical results. One main advantage, over titanium cages, is the absence of MRI artifacts, allowing an excellent postoperative follow-up.

Introduction

Cervical poly-ether-ether-ketone (PEEK) cages, as well as TTN cages for intervertebral disc space reconstruction, are generally accepted grafts for anterior cervical discectomy and fusion (ACDF).¹⁻⁷ TTN-cages have been criticized to produce an

inferior clinical outcome compared with bone grafts due to a higher elasticity modulus, which could result in cage subsidence.⁸ Nevertheless, due to structural properties, TTN implants are likely to provide a good osseo-integration⁹ and several clinical studies demonstrate successful results after implantation of TTN-cages.¹⁰⁻¹³ PEEK-cages have a modulus of elasticity closely resembling that of cortical bone, which might lead to advantages in load sharing and stress distribution. This might reduce the subsidence rate with an improved segmental correction in the long term and a potentially higher fusion rate.¹⁴⁻¹⁶ A direct comparison of cervical TTN- and PEEK-cages in a clinical setting is very rarely found in the literature,^{16,17} and even less studies consequently compare the radiological results.^{16,17} The latter studies showed the PEEK-implants being superior in maintaining cervical interspace height and achieving radiographic fusion,^{16,17} even suggesting to cease the application of TTN-cages in cervical spine surgery.¹⁶

A solution in-between are newer cages that combine the benefit of both materials: PEEK-body cages plasma-sprayed with a porous titanium surface which is tightly bonded to the PEEK surface.^{18,19} On TTN alloy substrates, osteoblasts exhibit a more differentiated phenotype and increased bone morphogenetic protein production than on poly-ether-ether-ketone.²⁰ A group of Japanese surgeons found that TTN-coated PEEK cages exhibit radiographic signs of bone on-growth, as represented by vertebral cancellous condensation around the cage, compared with that around the uncoated PEEK cage.²¹ Therefore, a TTN-coated PEEK cage may have the potential to promote solid fusion and to improve clinical outcomes in cervical interbody fusion surgery. This keeps the ideal elasticity modulus close to a bonelike elasticity modulus and offers a highly biocompatible surface that is well tolerated by bone and allows its ongrowth to the porous surface. The aim of the present study is to assess clinical and radiological results of CeSpace XP[®], a titanium-coated PEEK cage.

Materials and Methods

Objectives

We intended to assess the minimum one-year up to the maximum possible results of the described cage concept of a PEEK body with a plasma-sprayed porous titanium coating, the CeSpace XP[®] (Aesculap AG, Tuttlingen), in patients operated at our Institution.

Correspondence: José Aso Escario, Servicio de Neurocirugía. Hospital MAZ. Avenida de la Academia general Militar, 74, 50015 Zaragoza, Spain.
 Tel. +34.976748000 - Fax: +34976748044.
 E-mail: jaso@maz.es

Key words: Titanium cages; Cervical disc herniation; Microdiscectomy; Osseointegration.

Acknowledgments: The authors would like to thank María Pilar Gracia Bernad for her help in identifying, finding and contacting patients, and resolving all patient issues during their examination in the hospital. She also supported in completing the documentation.

Contributions: the authors contributed equally.

Conflict of interest: the authors declare no potential conflict of interest.

Funding: None.

Availability of data and materials: The authors confirm that the data supporting the findings of this study are available within the article.

Ethics approval and consent to participate: All procedures performed were in accordance with the ethical standards of the institutional and/or national research committee.

Informed consent: Written informed consent was not required for this study.

Received for publication: 30 October 2019.
 Accepted for publication: 14 February 2020.

This work is licensed under a Creative Commons Attribution NonCommercial 4.0 License (CC BY-NC 4.0).

©Copyright: the Author(s), 2020

Licensee PAGEPress, Italy
 Orthopedic Reviews 2020;12:8359
 doi:10.4081/or.2020.8359

Cases

A patient cohort of 62 patients who received this implant between August 2013 and September 2017, in one- or two-level ACDF, was identified. We tried to contact all of these for clinical and radiological follow-up. The local institutional ethics committee gave consent to this follow-up study and approved conformity of the study to the Helsinki Declaration and to the local legislation. The study is registered under ClinicalTrials.gov ID: NCT03565224. All the patients were preoperatively informed about the procedure and implant characteristics, and they signed a consent form containing extensive and detailed information about these two subjects. The patients were asked to come to the hospital between November 2017 and September 2018 to

report on their results. The residual twelve patients were either not accessible, lived abroad, or were not interested to come to the hospital for a follow-up examination. The 50 patients experienced radiculopathy and neck pain as main symptoms.

Surgical procedure

ACDF was performed in supine position by a transverse skin incision from the right side after induction of general anesthesia. The surgical approach followed the classical Smith-Robinson procedure.²² In all cases, a radical microsurgical discectomy was performed, including resection of posterior osteophytes, when they existed and extraction of any disc extrusion as well as preparation of the endplates with a high speed drill and decompression of the nerve structures. The posterior longitudinal ligament was opened transversely, until the dura was exposed. The cage is then introduced under distraction (3.5 Kg applied to the head). The appropriate implant dimension can be determined with the aid of the of the trial implants. Once the cage is positioned, the distraction is removed, allowing both vertebral bodies to progressively compress the cage, in order to achieve an adequate anchorage of the rough titanium surface into both vertebral endplates.

The placement of the implant was controlled by means of static intraoperative radioscopy and flexo-extension. The cage was placed close to the anterior margin of the spine to achieve a segmental lordosis. The patients received one or two CeSpace XP titanium coated PEEK cages (B Braun Aesculap, Tuttlingen, Germany) (Figure 1).

The choice of cage size depended mainly on the height of the adjacent intervertebral disc space and the sagittal profile. The cage was chosen to be at least 1mm higher than the affected disc, but was not supposed to exceed a normal adjacent level disc substantially. The exact disc height of the normal adjacent level was not measured pre- or intraoperatively, but was estimated by cage trials and lateral fluoroscopy during surgery. After surgery, all patients were treated by the same protocol, which consisted of moderate analgesia, standing-up and walking the day following the surgery, prophylactic antibiotics half an hour before and during three days post-surgery, and a soft collar for three days in our hospital. Patients are discharged from the hospital three days after surgery. Follow-up includes a clinical review at four weeks after surgery, and monthly visits up to six months. All patients are followed-up at least until one year after surgery, and then usually come back each year.

Clinical and radiological examinations

Fifty patients out of the identified 62

agreed to cooperate in assessing the results of the new cage design. For these patients, the demography was extracted from the patient file. Between November 2017 and September 2018 the patients then came to the hospital to be examined and to report on their subjective results. The residual twelve patients were either not accessible (three patients), lived abroad (one patient), or not interested to come to the hospital for a follow-up examination (eight patients).

The 50 patients experienced radiculopathy and neck pain as main symptoms. According to their indication, they had single level (40) or two-level fusion surgery (10), and received the studied cervical cage(s) in all cases.

Follow-up examinations were performed on an outpatient basis in our department. Neck and arm pain level and frequency were measured using the Visual Analogue Scale (VAS). Patient file was checked and the patients were asked if any Adverse Events or Serious Adverse Events were experienced.

Functionality was assessed with help of the validated Spanish Neck Disability Index forms (NDI), it assesses the neck-specific functioning with a percentage (0-100%, where 0% denotes optimal function).^{23,24}

The categories were defined according to the Physiopedia categories for the Neck Disability Index.²⁵

Additionally, it was neurologically assessed if the patient experienced residual neurological deficits, and if the situation compared to the preoperative state has improved, is the same or it has deteriorated.²⁶ In addition, patients were asked to rate the overall surgical result in

four categories: "excellent", "good", "unsatisfactory" or "bad".

Radiological analysis involved the measurement of various angles in the follow-up x-rays, to identify the fusion status: The segmental angles of the operated vertebral levels were measured in extension and flexion. At the follow-up the occurrence of anterior and posterior bone bridging was assessed. Cage position was evaluated qualitatively as "ideal", "suboptimal" or "bad". Solid arthrodesis was assessed according to the following accepted criteria:^{1,5,13,28} the operated segment was rated as a solid arthrodesis, if movement of less or equal 2° was measured, and by the absence of motion between the spinous processes on lateral flexion-extension radiographs. Movement of >2° on flexion/extension radiographs was considered as pseudarthrosis.^{2,5} Qualitative checks of bone sclerosis and radiolucencies along the implant-bone interface were assessed as well. Measurements were done on digital radiographs using integrated software to measure angles and distances up to the accuracy of 0.1° and 0.01 mm, respectively (Carestream Health, Rochester, New York, USA). The values were expressed as mean with standard deviation. To validate the assessed data the measurements were performed by an independent examiner (CS).

Statistical analysis

The statistical evaluation was performed using SAS Software version 9.4 (SAS Institute Inc., Cary, NC, USA). Statistical analysis of age and gender was performed by Student's t-test. A p-value <0.05 was deemed as statistically significant.



Figure 1. The CeSpace XP® Titanium-coated PEEK cage.

Results

Demographics

Out of the 62 patients that underwent ACDF surgery between 2013 and 2017, 50 could be contacted and convinced to come to a follow-up examination into the hospital (27 men and 23 women). Reasons for no examination were either not accessible (three patients), lived abroad (one patient), or not interested to come to the hospital for a follow-up examination (eight patients).

The 50 patients came to the hospital for follow-up between November 2017 and September 2018 after giving their consent to the study. Major symptoms were radiculopathy and neck pain. According to their indication, they had single level (40 patients) or two-level fusion surgery (ten patients), and received the studied cervical cage in all cases (Table 1).

Age ranged from 30 to 65 years at time of surgery, with an average age of 43.1 years (StdDev: 8,4 years, Table 2). The body mass index ranged between 19 and 37, with an average BMI of 26 (StdDev: 4). Forty-four (88%) of the patients were employed at time of surgery, two (4%) were retired, and 4 (8%) were self-employed. Forty-three patients (86%) have only light labor and full time work, three patients heavy labor, one patient had sedentary work and three were not able to work.

The patients were 15 smokers (30%), four former smokers (8%) and 31 non-smokers (62%). Therefore 19 patients have at least a smoking history. The majority of the patients did not suffer from concurrent diseases (38, 76%). Concurrent diseases mentioned in the rest of the patients were respiratory (three patients, 6%), endocrine (two, 4%) musculo-skeletal (two, 4%), or gastro-intestinal, uro-genital, renal, neurological, and cardiovascular (1 patient, 2% each). The follow-up period ranged from a minimum of 11,9 months to a maximum of 56,7 months, with an average of 27,8 months (StdDev:11,9 months). Eighteen patients (36%) did not receive any preoperative treatments. Twenty-six patients had physiotherapy (52%), five (10%) had rehabilitation measures, four patients (8%) had a collar, and one patient (2%) had acupuncture. Most of the patients used non-opioid-analgesics or no pain medication (Level 1 on WHO pain scale); only one patient used a low-powered opioid or non-opioid analgesics. The preoperative neurological assessment revealed no neurological deficit in 14 cases (28%), a motor deficit in four cases (8%), a sensory deficit in 30 cases (60%) and a combined motor and sensory deficit in two cases (4%). Previous spinal surgeries

on the affected level were not assessed or reported by any of the patients.

Surgery

All surgeries were performed by a Neurosurgeon, following the same procedure. Anticoagulation was not given for any patient, antibiotics (Cefuroxim, 1500mg intravenously) was given to all patients preoperatively. The surgical approach was "middle-lateral right" in all cases. None of the patients showed osteoporotic bone quality during operation, one patient suffered from a mild and one a severe sclerosis of the bone. The Anterior Longitudinal Ligament (ALL) was entirely opened in all cases, allowing to widely visualizing the ventral aspect of the dura. Microscopically assisted

radical discectomy was performed, removing posterior osteophytes and herniated disc fragments. ACDF was performed on 60 segments in 50 patients, in two cases at C3/4, in seven cases at C4/5, in 32 cases at C5/6 and in 19 cases at C6/7 (Table 3). Cage types were applied in sizes from 4 to 7 mm in height with a diameter of 14 or 16 mm, and a depth of 11,5 or 13,5 mm, and always with an angle of 5° to restore lordosis. Cage numbers and sizes implanted are listed in Table 1. An additional plate was not used in any of the patients. The operation time ranged from 45 to 110 minutes, with an average time of 57,9 minutes. Blood loss ranged between 0 and 40ml, with an average loss of 11,3 ml.

Table 1. Levels operated.

		Segments	
		1-level	2-level
C3/C4	2		
C4/C5	2		C4/C5 C5/C6 5
C5/C6	22		C5/C6 C6/C7 5
C6/C7	14		
Patients:	40		10

Table 2. Demographics.

	Min	Max	Mean	Std Dev
Age	30	65	43,1	8,4
Weight	45	113	76,4	13,9
Height	149	188	171,4	8,6
BMI	19,0	37,2	25,9	4,2
Gender	Male		Female	
	N	%	N	%
	27	0,54	23	0,46
Levels treated	1-level		2-levels	
	N	%	N	%
	40	67	20	33
Smoking status	Non-smokers		Smokers and former smokers	
	N	%	N	%
	31	62	19	38

Table 3. Cage sizes implanted in 50 patients.

Implant Art. Nr.	Name	Dimension	Nr. of cages used
SO274P	CeSPACE XP	4 mm 16 mm 13,5 mm 5°	3
SO255P	CeSPACE XP	5 mm 14 mm 11,5 mm 5°	7
SO275P	CeSPACE XP	5 mm 16 mm 13,5 mm 5°	47
SO276P	CeSPACE XP	6 mm 16 mm 13,5 mm 5°	2
SO257P	CeSPACE XP	7 mm 14 mm 11,5 mm 5°	1
Total			60

Clinical and radiological outcome

All 50 patients gave a statement on their neck pain. On average they rated their pain at 17.9mm (min 0.0mm, max 91.0mm, StdDev: 20.6 mm). The arm pain was rated by 48 patients, at 14.3mm (min 0.0mm, max 86.0mm, StdDev: 21.5mm). Frequency of neck pain was rated by all 50 patients at 28.0mm (min 0.0mm, max 100.0mm, StdDev: 28.7mm). Frequency of arm pain was rated by 49 patients at 14.9mm (min 0.0mm, max 96.0mm, StdDev: 21.7mm), Table 4.

The NDI was reported by 49 patients at a mean of 7.5 points (15% of disability out of 50 points (min 0, max 33 (66%), StdDev: 7 (14%)). This corresponds to the category “mild disability” (5-14points, 10 – 28%, mild disability,²⁴) Out of the 49 patients, 21 experienced no disability, 21 a mild disability, five patients a moderate and two patients a severe disability according to the chosen categories.

Adverse or Serious Adverse Events were not identified in the patient files, nor did any of the patients report on experienced Adverse Events during the pre- and postoperative period until the current follow-up examination.

Neurologically none of the patient reported any deficits at the follow-up examination. Compared to the preoperative situation the neurological status was improved for four patients. The residual patients did not experience any deficits neither pre- nor postoperatively.

The overall rating of the surgical result by the patient is excellent in 36 cases (72%), good in twelve cases (24%), and unsatisfactory in two cases (4%). The result option “bad” was not chosen in any patient.

Plain AP and ML, x-rays were performed in all patients (plain: 60 segments,

100%) during the follow-up visit.

Fusion: In three patients the X-ray images for flexion and extension to determine segmental mobility were not complete, so that a total of 57 segments could be evaluated for residual motion in the segment.

Eleven segments (19.3%) had a higher mobility than 2°, in 46 segments (80,7%) an arthrodesis defined as segment mobility of less or equal than 2° was found. The high rate of smoking patients and those with a smoking history (“former smokers” and “smokers”) initiated an additional testing of differences between the groups on segment basis. The difference of the fusion rates of smokers and non-smokers is 65,2% vs. 91,2% of the segments, which proved to be significant, although the segment numbers are relatively low (p=0,0148, Table 5).

In 37 cages (62%) the position of the cage was rated ideal. Twenty cages (33%) were rated suboptimal, and three cages were rated bad (5%).

Radiological densities: An enhanced density in the operated segment was seen in all of the examined segments, bone bridging

the adjacent vertebrae was seen in 41 of the 60 segments treated (68%). In five segments only an anterior bone bridge was identified (12%), in 22 cases only posterior (54%), and in 14 cases bone bridges were seen anteriorly and posteriorly (34%).

Radiolucencies (RD): No RD were seen in 28 segments along the bone/implant interface (46.7%). Mild, “under 25% RD“ were identified in 19 segments (31.7%) Moderate, “between 25 and 50% radiolucencies” were seen in ten segments (16.7%). In three segments, bone/cage interfaces showed severe RD (5%), i.e. “more than 50%” of the interface line with signs of less density (Figure 2).

Discussion and Conclusions

We present a prospective study that intended to re-examine patients being operated for ACDF with cervical stand-alone TTN-coated PEEK cages in the past. The purpose of this investigation was to get more information on the clinical and radio-

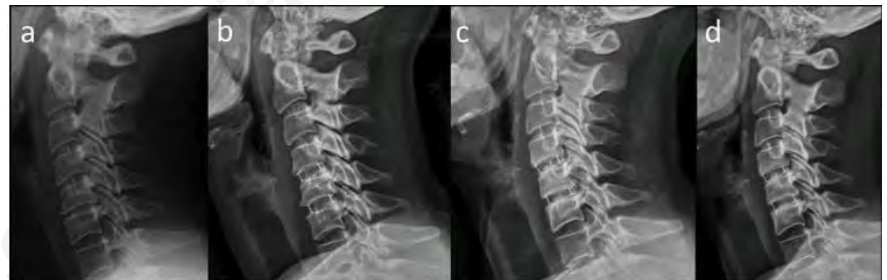

Figure 2. Patient with a bisegmental fusion: a) preoperatively, b) directly postoperative, c) after 5,5 months, and d) after 12 months.

Table 4. Clinical results, summarizing VAS and Neck Disability Index outcome.

Clinical Scale	N	Min, mm	Max, mm	Median, mm	Mean, mm	StdDev
VAS – Neck pain intensity	50	0.00	91.00	8.50	17.92	20.60
VAS – Arm pain intensity	48	0.00	86.00	3.50	14.29	21.53
VAS – Neck pain frequency	50	0.00	100.00	14.00	27.98	28.70
VAS – Arm pain frequency	49	0.00	96.00	5.00	14.92	21.56
Neck Disability Index, (%)	49	0.000	66	12	15	14

Table 5. Fusion rates in segments, depending on the smoking history of the patient, smokers (summarizing “former smokers” and “smokers”) and non-smokers. The difference in fusion rates is significant (p=0.0148).

	Non-Smoker		Smoker		Total (ALL)	
	N	%	N	%	N	%
Total (ALL)	34	100,0	23	100,0	57	100,0
No	3	8,8	8	34,8	11	19,3
Yes	31	91,2	15	65,2	46	80,7

logical outcome of a new PEEK cage design with a biocompatible porous Ti coating, in follow-ups between one and almost five years. The clinical outcome could be found comparable to the literature with overall minor disabilities for most of the patients. On average the examined subjects reported a low grade of disability (15%) assessed with the NDI, corresponding to the category “mild disability”.²⁵ A recent publication on microscope and non-microscope ACDF patients revealed an average NDI of 25.04% (microscope group) and 26.54% (non-microscope group).⁴¹

Forty-eight patients considered their outcome as good or excellent (96%), only two patients said that their result was unsatisfactory (4%). The result option “bad” was not chosen by any of the patients.

The radiological examination revealed a reasonable rate of solid arthrodesis and an overall good positioning of the cages. None of the patients experienced a reoperation or revision of the implanted cage.

Compared to a full TTN cage design, the radiological evaluation of the cage becomes easier due to a very low rate of artefacts, especially when magnetic resonance images are considered;⁴² this helps the surgeon to analyze the situation at a follow-up examination. On the other hand the cage integration into the bone is not compromised due to the biocompatible TTN coating (Figure 3, showing a comparison of MRI images of a TTN-coated and a full TTN cage).

Advantages regarding the imaging of the anatomic details around the surgical field of interest are an excellent view to the disc, foramina and canal, avoiding postoperative MRI artefacts rendered by full TTN cages.

Another feature besides the artefact-free visualization compared to full TTN cages is the striated surface of the cage endplates providing a press-fit and locking mechanism that anchors the cage tightly to the vertebral endplates once the cage is inserted and the distraction released (Figure 4).

We found that a relatively high percentage of patients are smokers or former smokers. Looking closer into their fusion rates compared to non-smokers separately, the overall rate of 81% fusion, defined as motion in the segments of less or equal 2° diverged as expected for the groups. The smokers reached a fusion rate of 65%, while the non-smokers showed a rate of 91%. This difference proved to be significant. ($p=0.0148$). The role of smoking in causing pseudarthrosis has been well studied in lumbar spine fusions with up to a fourfold increase in nonunion rates from 8% to 40% for lumbar fusions.²⁹ Nicotine has a direct

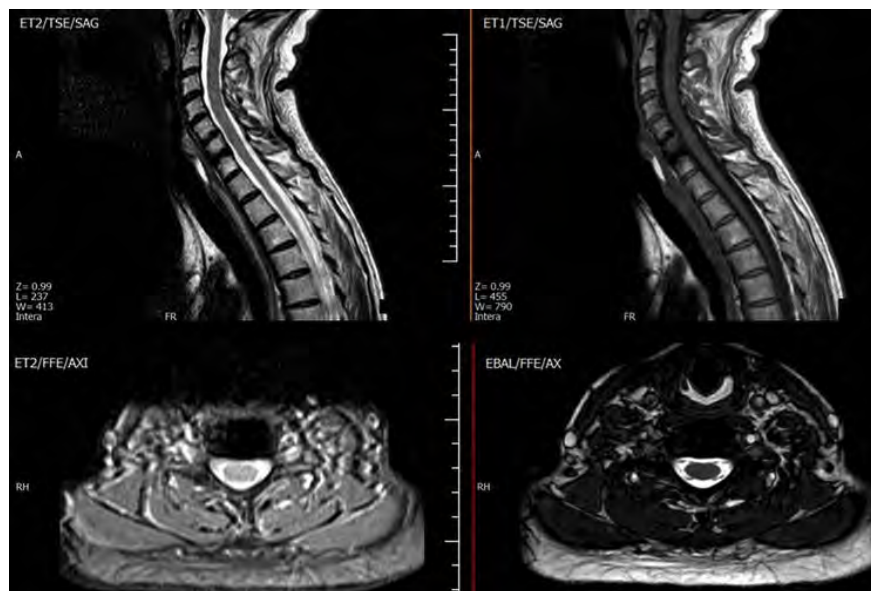


Figure 3. MRI Images of a spine that contains the TTN-coated cage investigated in this study. The images demonstrate an excellent visualization of disc, foramina and canal, avoiding postoperative MRI artifacts.

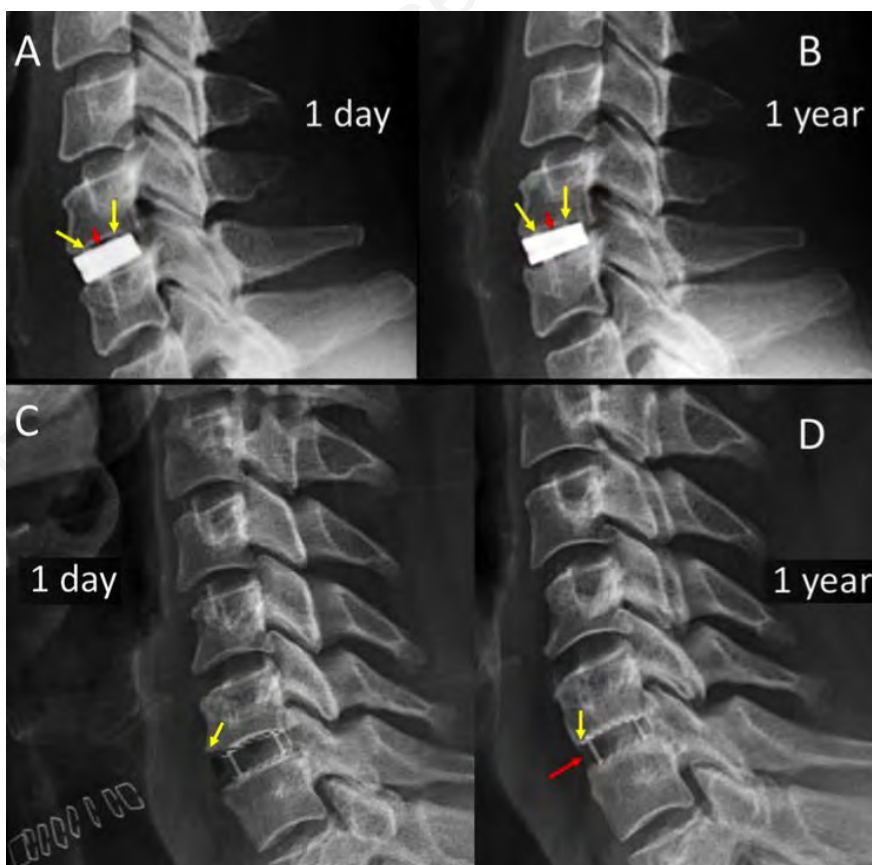


Figure 4. Comparison of mediolateral x-rays of a full titanium (A and B) and a titanium porous coated primary stabilization system (C and D). Note the void space (red arrow) at the vertebral-implant interface (red arrows in A and B) for the full TTN cage. In C and D, a complete implant-plate adhesion is visible directly postoperatively and after one year of follow-up. Yellow arrows in C and D depict a squaring modification of anterior-inferior vertebral body angle. Red arrow points to a subtle ossification of the anterior longitudinal ligament (ALL). Both features reveal a beginning degree of secondary stabilization (fusion).

inhibitory effect on autologous cancellous bone graft revascularization,³⁰ as well as an increased rate of bone graft necrosis in a rabbit model of bone graft implantation.³⁰ Systemic nicotine has also been linked to nonunion in spinal fusion animal models.^{31,32} For cervical spine surgery, the effects of smoking have been studied only in patients undergoing anterior decompression and arthrodesis. Smoking is associated with a higher rate of delayed fusions and pseudarthrosis,³³⁻³⁶ greater interspace collapse,³⁷ and increased pain and decreased activity in multilevel anterior interbody grafting.³⁶ Bishop *et al.*³⁷ found these negative effects on anterior interbody fusion with the use of both allogenic and autogenic grafts, but the effect of smoking was most pronounced in attempted fusions with allograft. Despite the reportedly higher rate of pseudarthrosis in smokers for interbody grafting, Hilibrand *et al.*³⁶ reported no difference in the rate of fusion between smokers and nonsmokers who underwent corpectomy and anterior strut grafting. The addition of anterior plating in multilevel anterior decompressions and fusions improves fusion rates in smokers.³⁸

Design, shape, size, surface architecture of a cage as well as bone density, endplate preparation and applied distraction during surgery need to be considered as important factors that influence the clinical and radiological results of cervical fusion.³⁹ A significant proportion of patients show good recovery after ACDF, which was the case for the patients examined here. On the other hand, a recent multicentric study on ACDF with empty PEEK cages, i.e. no bone filling, showed delayed fusion, documenting that PEEK alone is not ideal to promote cervical fusion.⁴⁰ Our study provides strong evidence that ACDF is an effective treatment, but the overall rate of radiographic fusion with empty PEEK cages is slow and insufficient. They also link the radiographic results of delayed fusion with the clinical results: "Lack of complete radiographic fusion leads to less improvement of pain and disability. We recommend against using empty uncoated pure PEEK cages in ACDF". A recent study on the effect of Ti coating in a lumbar fusion patient cohort with both cage variants (PEEK alone and coated PEEK PLIF cages in one segment) showed that the coated cages integrate better into the surrounding bone.²¹

There are a few limitations to the study: As a randomization could not be installed for this study due to the retrospective collection of patients to be re-examined, further research is necessary to elaborate an additional potential clinical benefit (superiority) of the cage investigated here. This

could be in a randomised study set-up that allows a direct comparison of PEEK alone and Ti coated PEEK.

References

1. Dorai Z, Morgan H, Coimbra C. Titanium cage reconstruction after cervical corpectomy. *J Neurosurg* 2003; 99:3-7.
2. Hacker RJ. A randomized prospective study of an anterior cervical interbody fusion device with a minimum of 2 years of follow-up results. *J Neurosurg* 2000;93:222-6.
3. Mastronardi L, Ducati A, Ferrante L. Anterior cervical fusion with polyetheretherketone (PEEK) cages in the treatment of degenerative disc disease. Preliminary observations in 36 consecutive cases with a minimum 12-month follow-up. *Acta Neurochir (Wien)* 2006;148:307-12.
4. Vadapalli S, Sairyo K, Goel VK, et al. Biomechanical rationale for using polyetheretherketone (PEEK) spacers for lumbar interbody fusion-A finite element study. *Spine (Phila Pa 1976)* 2006;31:E992-8.
5. Hacker RJ, Cauthen JC, Gilbert TJ, Griffith SL. A prospective randomized multicenter clinical evaluation of an anterior cervical fusion cage. *Spine (Phila Pa 1976)* 2000;25:2646-54.
6. Profeta G, de Falco R, Ianniciello G, et al. Preliminary experience with anterior cervical microdiscectomy and interbody titanium cage fusion (Novus CT-Ti) in patients with cervical disc disease. *Surg Neurol* 2000;53:417-26.
7. Cabraja M, Kroppenstedt S. Bone grafting and substitutes in spine surgery. *J Neurosurg Sci* 2012;56:87-95.
8. McKenna PJ, Freeman BJ, Mulholland RC, et al. A prospective, randomised controlled trial of femoral ring allograft versus a titanium cage in circumferential lumbar spinal fusion with minimum 2-year clinical results. *Eur Spine J* 2005;14:727-37.
9. Johansson CB, Roser K, Bolind P, et al. Bone-tissue formation and integration of titanium implants: an evaluation with newly developed enzyme and immunohistochemical techniques. *Clin Implant Dent Relat Res* 1999;1:33-40.
10. Schmieder K, Wolzik-Grossmann M, Pechlivanis I, et al. Subsidence of the wing titanium cage after anterior cervical interbody fusion: 2-year follow-up study. *J Neurosurg Spine* 2006;4:447-53.
11. Cabraja M, Abbushi A, Kroppenstedt S, Woiciechowsky C. Cages with fixation wings versus cages plus plating for cervical reconstruction after corpectomy - is there any difference? *Cen Eur Neurosurg* 2011;71:59-63.
12. Cabraja M, Abbushi A, Koeppen D, et al. Comparison between anterior and posterior decompression with instrumentation for cervical spondylotic myelopathy: sagittal alignment and clinical outcome. *Neurosurg Focus* 2010; 28:E15.
13. Thome C, Krauss JK, Zevgaridis D. A prospective clinical comparison of rectangular titanium cages and iliac crest autografts in anterior cervical discectomy and fusion. *Neurosurg Rev* 2004;27:34-41.
14. Brantigan JW, Steffee AD, Lewis ML, et al. Lumbar interbody fusion using the Brantigan I/F cage for posterior lumbar interbody fusion and the variable pedicle screw placement system: two-year results from a Food and Drug Administration investigational device exemption clinical trial. *Spine (Phila Pa 1976)* 2000;25:1437-46.
15. Cutler AR, Siddiqui S, Mohan AL, et al. Comparison of polyetheretherketone cages with femoral cortical bone allograft as a single-piece interbody spacer in transforaminal lumbar interbody fusion. *J Neurosurg Spine* 2006;5:534-9.
16. Chou YC, Chen DC, Hsieh WA, et al. Efficacy of anterior cervical fusion: comparison of titanium cages, polyetheretherketone (PEEK) cages and autogenous bone grafts. *J Clin Neurosci* 2008;15:1240-5.
17. Meier U, Kemmesies D. [Experiences with six different intervertebral disc spacers for spondylolysis of the cervical spine]. *Orthopade* 2004;33:1290-9.
18. Cheng B. Biomechanical Pull-out strength and Histology of Plasmapore XP® coated Implants: Ovine Multi-Timepoint Survival Study.
19. Mechanical Testing Summary: Adhesion Strength of the Plasmapore XP® coating to PEEK. Aesculap Implant systems, White Paper, 2013 (ART123).
20. Olivares-Navarrete R, Gittens RA, Schneider JM, et al. Osteoblasts exhibit a more differentiated phenotype and increased bone morphogenetic protein production on titanium alloy substrates than on poly-ether-ether-ketone. *Spine J* 2012;12:265-72.
21. Kashii M, Kitaguchi K, Makino T, Kaito T. Comparison in the same intervertebral space between titanium-coated and uncoated PEEK cages in lumbar interbody fusion surgery. *J Orthop Sci*

- 2019.
22. Aronson N, Filtzer DL, Bagan M. Anterior cervical fusion by the Smith-Robinson approach. *J Neurosurg* 1968;29:396-404.
 23. Vernon H, Mior S. The Neck Disability Index: a study of reliability and validity. *J Manipulative Physiol Ther* 1991;14:409-15.
 24. MacDermid JC, Walton DM, Avery S, et al. Measurement properties of the neck disability index: a systematic review. *J Orthop Sports Phys Ther* 2009;39:400-C12.
 25. https://www.physio-pedia.com/Neck_Disability_Index
 26. Barsa P, Suchomel P. Factors affecting sagittal malalignment due to cage subsidence in standalone cage assisted anterior cervical fusion. *Eur Spine J* 2007;16:1395-400.
 27. Chiang CJ, Kuo YJ, Chiang YF, et al. Anterior cervical fusion using a polyetheretherketone cage containing a bovine xenograft: three to five-year follow-up. *Spine (Phila Pa 1976)* 2008;33:2524-8.
 28. Yang JJ, Yu CH, Chang BS, et al. Subsidence and nonunion after anterior cervical interbody fusion using a standalone polyetheretherketone (PEEK) cage. *Clin Orthop Surg* 2011;3:16-23.
 29. Brown CW, Orme TJ, Richardson HD. The rate of pseudoarthrosis (surgical nonunion) in patients who are smokers and patients who are nonsmokers: a comparison study. *Spine*. 1986;11:942-3.
 30. Dafarti TK, Whitesides TE, Heller JG, et al. Nicotine on the revascularization of bone graft. An experimental study in rabbits. *Spine* 1994;19:904-11.
 31. Boden SD, Sumner DR. Biologic factors affecting spinal fusion and bone regeneration. *Spine (Phila Pa 1976)* 1995;20:102S-112S.
 32. Silcox DH, Dafarti T, Boden SD, et al. The effect of nicotine on spinal fusion. *Spine* 1995;20:1549-53.
 33. An HS, Simpson JM, Glover JM, Stephany J. Comparison between allograft plus demineralized bone matrix versus autograft in anterior cervical fusion. A prospective multicenter study. *Spine* 1995;20:2211-3326.
 34. Bishop RC, Moore KA, Hadley MN. Anterior cervical interbody fusion using autogenic and allogeneic bone graft substrate: a prospective comparative analysis. *J Neurosurg* 1996;85:206-10.
 35. Bohlman HH, Emery SE, Goodfellow DB, Jones PK. Robinson anterior cervical discectomy and arthrodesis for cervical radiculopathy. Long-term follow-up of one hundred and twenty-two patients. *J Bone Joint Surg Am* 1993;75:1298-307.
 36. Hilibrand AS, Fye MA, Emery SE, et al. Impact of smoking on the outcome of anterior cervical arthrodesis with interbody strut grafting. *J Bone Joint Surg Am* 2001;83:668-73.
 37. Bishop RC, Moore KA, Hadley MN. Anterior cervical interbody fusion using autogenic and allogeneic bone graft substrate: a prospective comparative analysis. *J Neurosurg* 1996;85:206-10.
 38. Bose B. Anterior cervical instrumentation enhances fusion rates in multilevel reconstruction in smokers. *J Spinal Disord* 2001;14:3-9.
 39. Cabraja M, Oezdemir S, Koeppen D, Kroppenstedt S. Anterior cervical discectomy and fusion: comparison of titanium and polyetheretherketone cages. *BMC Musculoskelet Disord* 2012;13:172.
 40. Suess O, Schomaker M, Cabraja M, et al. Empty polyetheretherketone (PEEK) cages in anterior cervical discectomy and fusion (ACDF) show slow radiographic fusion that reduces clinical improvement: results from the prospective multicenter "PIERCE-PEEK" study. *Patient Saf Surg* 2017;11:12.
 41. Adogwa O, Elsamadicy A, Reiser E, et al. Comparison of surgical outcomes after anterior cervical discectomy and fusion: does the intra-operative use of a microscope improve surgical outcomes. *J Spine Surg* 2016;2:25-30.
 42. Arregui Aso J, Martínez-Quiñones JV, Consolini F, et al. Cespace: sistema de fusión intersomática cervical: Estudio preliminar en 104 casos (120 implantes). *Neurocirugía* 2019;22:542-53.