

## Cytomegalovirus associated rectal ulcer as a manifestation of primary HIV infection

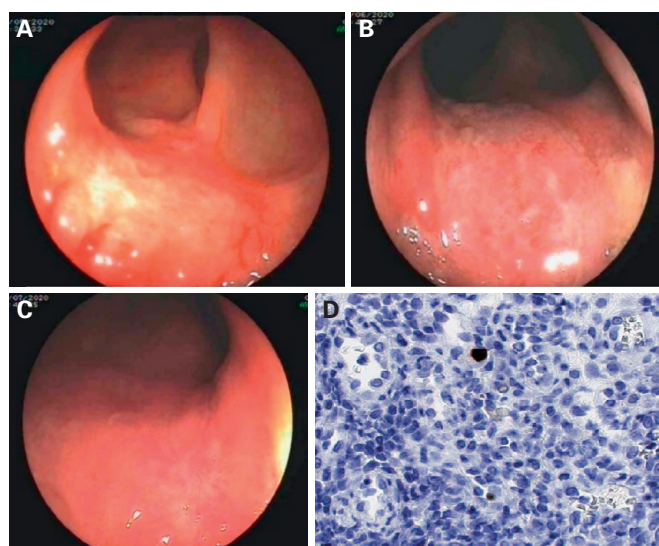
Keywords: Cytomegalovirus (CMV). Human immunodeficiency virus (HIV). Colitis.

Dear Editor,

We present the case of a 40-year-old male who presented due to fatigue, mild weight loss and rectal bleeding for 2 months, with no fever or diarrhea. He referred unprotected intercourse and blood tests revealed mild elevation of transaminases. Serologies were positive for CMV IgG, CMV plasma levels were 47 UI/ml (PCR) and the rest of hepatotropic viruses were negative. Abdominal ultrasound was normal and an ulcer was observed in the lower rectum during colonoscopy, with negative biopsies for malignancy and a positive immunohistochemistry (IHC) for CMV (Fig. 1A). Serologic analysis was extended and was positive for antibodies against the human immunodeficiency virus (HIV), with a viral load of 50 500 copies/ml, negative p24 antigen and a CD4+ cell count of 900 cells/mm<sup>3</sup> (30 %). The rest of serologies and triple-site testing were negative. We referred the patient to the infectious disease clinic and he started antiretroviral therapy (ART). A watchful waiting approach was decided for the rectal ulcer with close endoscopic follow-up, resulting in early healing and complete resolution (Figs. 1 B and C).

### Discussion

Cytomegalovirus (CMV) disease of the gastrointestinal tract is a common manifestation of CMV infection in HIV patients, generally secondary to reactivation (1) and in advanced stages with a CD4 cell count below 100 cells/mm<sup>3</sup> (2). The colon is the most common site affected and endoscopic findings are heterogeneous, with ulcers being the most frequent endoscopic finding, sometimes associated with inflammation (3). Isolated cases of CMV infection have been described during primary HIV infection with a normal CD4



**Fig. 1.** A. Rectal ulcer at diagnosis. B. Control at 3 weeks. C. Control at 8 weeks. D. IHC with CMV positivity in isolated endothelial cells of neovessels.

cell count (4,5), generally associated with fever, abdominal pain and diarrhea, with a good response to ganciclovir. Our patient presented a mononucleosis-like syndrome without fever and an isolated rectal ulcer due to CMV. A watch and wait approach was decided due to starting ART and the good general condition of the patient. It was not necessary to start ganciclovir because of the clinical and endoscopic improvement. At 8 weeks, the rectal ulcer was healed.

Conflict of interest: the authors declare no conflict of interest.

Silvia Espina Cadena<sup>1,2</sup>, Elena del Valle Sánchez<sup>3</sup>, Yolanda Martínez Santos<sup>1</sup>,  
María Badía Martínez<sup>1</sup>, and Patricia Camo Monterde<sup>1</sup>  
<sup>1</sup> Gastroenterology Department. Hospital General de la Defensa. Zaragoza, Spain. <sup>2</sup>Instituto de Investigación Sanitaria (IIS) Aragón. Zaragoza, Spain. <sup>3</sup>Pathological Anatomy Department. Hospital Universitario Miguel Servet. Zaragoza, Spain

DOI: 10.17235/reed.2022.8546/2021

## References

---

1. Pintos Pascual I, Muñoz Rubio E, Ramos Martínez A. Complicaciones infecciosas en el paciente con infección por el VIH. *Medicine - Programa de Formación Médica Continuada Acreditado* 2018;12(56):3306-13. DOI: 10.1016/j.med.2018.04.021
2. Garcés Molina FJ, Royo García A, Hernández Pérez G, et al. Diarrea por citomegalovirus (CMV) como primera manifestación de sida. *An Med Interna* 2000;17:31-2.
3. Marques O, Jr., Averbach M, Zanoni EC, et al. Cytomegaloviral colitis in HIV positive patients: endoscopic findings. *Arq Gastroenterol* 2007;44(4):315-9. DOI: 10.1590/s0004-28032007000400007
4. Smith PR, Glynn M, Sheaff M, et al. CMV colitis in early HIV infection. *Int J STD AIDS* 2000;11(11):748-50. DOI: 10.1258/0956462001915183
5. Paparone PP, Paparone PA. Cytomegalovirus Colitis in a Human Immunodeficiency Virus-Positive Patient With a Normal CD4 Count. *Am J Med Sci* 2012;344(6):508-10. DOI: 10.1097/MAJ.0b013e31825d4d1d