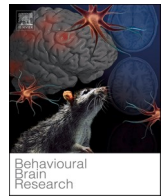




Contents lists available at ScienceDirect

## Behavioural Brain Research

journal homepage: [www.elsevier.com/locate/bbr](http://www.elsevier.com/locate/bbr)

## Hippocampal alterations after SARS-CoV-2 infection: A systematic review

Candela Zorzo<sup>a,b,c,1</sup>, Lucía Solares<sup>c,2</sup>, Marta Mendez<sup>a,b,c,\*,3</sup>, Magdalena Mendez-Lopez<sup>d,e,4</sup><sup>a</sup> Neuroscience Institute of Principado de Asturias (INEUROPA), Faculty of Psychology, Plaza Feijoo s/n, 33003 Oviedo, Asturias, Spain<sup>b</sup> Instituto de Investigación Sanitaria del Principado de Asturias (ISPA), Av. del Hospital Universitario, s/n, 33011 Oviedo, Asturias, Spain<sup>c</sup> Department of Psychology, University of Oviedo, Faculty of Psychology, Plaza Feijoo s/n, 33003 Oviedo, Asturias, Spain<sup>d</sup> Department of Psychology and Sociology, University of Zaragoza, Pedro Cerbuna 12, 50009 Zaragoza, Aragón, Spain<sup>e</sup> IIS Aragón, San Juan Bosco, 13, 50009 Zaragoza, Aragón, Spain

## ARTICLE INFO

**Keywords:**  
 COVID  
 Hippocampus  
 Brain  
 Neuropsychology  
 Symptomatology

## ABSTRACT

SARS-CoV-2 infection produces a wide range of symptoms. Some of the structural changes caused by the virus in the nervous system are found in the medial temporal lobe, and several neuropsychological sequelae of COVID-19 are related to the function of the hippocampus. The main objective of the systematic review is to update and further analyze the existing evidence of hippocampal and related cortices' structural and functional alterations due to SARS-CoV-2 infection. Both clinical and preclinical studies that used different methodologies to explore the effects of this disease at different stages and grades of severity were considered, besides exploring related cognitive and emotional symptomatology. A total of 24 studies were identified by searching in SCOPUS, Web Of Science (WOS), PubMed, and PsycInfo databases up to October 3rd, 2022. Thirteen studies were performed in clinical human samples, 9 included preclinical animal models, 3 were performed post-mortem, and 1 included both post-mortem and preclinical samples. Alterations in the hippocampus were detected in the acute stage and

**Abbreviations:** [18F]-FDG, 18F-fluorodeoxyglucose; 2019-nCoV, 2019 novel coronavirus; ACE2, angiotensin converting enzyme 2; ALFF, amplitude of low-frequency fluctuation; BBB, Blood-Brain Barrier; CA1, Cornu Ammonis-1; CBF, Cerebral blood flow; Cd11b, Cluster of Differentiation 11b; Cd200r1, Cluster of Differentiation receptor 1; CD68, Cluster Differentiation 68 Factor; CNS, Central Nervous System; CoV-19, Coronavirus 2019; COVID-19, Coronavirus Disease 2019; Cx3cr1, CX3C Chemokine Receptor 1; CXCL, C-X-C Motif Chemokine Ligand; DCX, Doublecortin; DG, Dentate Gyrus; dMRI, Diffusion Magnetic Resonance Imaging; dpi, day post-infection; ELISA, enzyme-linked immunoassay; EPM, Elevated Plus Maze; ErbB, erythroblastic leukemia viral oncogene; fMRI, Functional Magnetic Resonance Imaging; G-CSF, Granulocyte Colony-Stimulating Factor; GAD-7, Generalised Anxiety Disorder Assessment; GFAP, Glial Fibrillary Acidic Protein; GnRH, Gonadotropin hormone-releasing hormone; GMV, Grey Matter Volume; H&E, hematoxylin and eosin; hACE2, human angiotensin converting enzyme 2; HADS, Hospital Anxiety and Depression Scale; Hmgb1, high mobility group box 1; hpi, hours post-infection; Iba-1, Ionized calcium-binding adaptor molecule-1; ICU, Intensive Care Unit; IF, Immunofluorescence; Ifitm3, interferon-induced transmembrane protein 3; IFN- $\alpha$ , Interferon-alpha; IFN $\gamma$ , Interferon-gamma; IHC, immunohistochemistry; IL, Interleukin; Isg, Interferon-stimulated gene; K18, Keratin 18; Ki67, Kiel 67; LFB, Luxol Fast Blue; Long-COVID, Post-Acute Sequelae of SARS-CoV-2; M, Mean; MADRS, Montgomery-Asberg Depression Rating Scale; M<sub>age</sub>, Mean age; MAP2, Microtubule-associated protein 2; MCI, Mild cognitive impairment; MhcII $\alpha$ , Major Histocompatibility Complex II  $\alpha$ ; MMSE, Minimental State Examination; MoCa, Montreal Cognitive Assessment; MRI, Magnetic Resonance Imaging; mRNA, messenger ribonucleic acid; m, month/s; N, sample; NeuN, neuronal nuclear protein; Nlrp3, nucleotide-binding domain, leucine-rich-containing family, pyrin domain-containing-3; NR, not reported; n, sample per subgroup; p-NF-kB, phosphorylated-nuclear factor kappa B; PCLS, Posttraumatic Stress Disorder Checklist; PET, Positron Emission Tomography; PHQ-9, Patient Health Questionnaire; PRISMA, Preferred Reporting Items for Systematic Reviews and Meta-Analyses; PsycInfo, Psychological Information Database; PubMed, Public/Publisher MEDLINE; qPCR, quantitative polymerase chain reaction; qRT-PCR, quantitative real-time polymerase chain reaction; R<sub>age</sub>, age range; RAVLT, Rey Auditory Verbal Learning Test; ReHo, Regional homogeneity; RNA, Ribonucleic Acid; ROCF, Rey-Osterrieth Complex Figure; RT-PCR, Reverse transcription polymerase chain reaction; S1, Spike protein subunit 1; SARS-CoV-2, Severe Acute Respiratory Syndrome Coronavirus 2; SDMT, Symbol Digit Modalities Test; sgRNA, subgenomic ribonucleic acid; sMRI, Structural Magnetic Resonance Imaging; SOX9, SRY-Box Transcription Factor 9; STAI, State-Trait-Anxiety Inventory; Tlr, Toll-Like Receptor; TMT, trail making test; TNF, tumor necrosis factor; TrkB, tropomyosin receptor kinase B; VBM, Voxel-based morphometry; VEGF, vascular endothelial growth factor; WHO, World Health Organization; WOS, Web Of Science; wpi, weeks post-infection.

\* Correspondence to: Faculty of Psychology, Plaza Feijoo s/n, 33003 Oviedo, Asturias, Spain.

E-mail addresses: [zorrocandela@uniovi.es](mailto:zorrocandela@uniovi.es) (C. Zorzo), [UO271781@uniovi.es](mailto:UO271781@uniovi.es) (L. Solares), [mendezmarta@uniovi.es](mailto:mendezmarta@uniovi.es) (M. Mendez), [mmendez@unizar.es](mailto:mmendez@unizar.es) (M. Mendez-Lopez).<sup>1</sup> <https://orcid.org/0000-0002-4424-5697><sup>2</sup> <https://orcid.org/0000-0003-0401-6221><sup>3</sup> <https://orcid.org/0000-0003-1718-7492><sup>4</sup> <https://orcid.org/0000-0002-4249-602X><https://doi.org/10.1016/j.bbr.2023.114662>

Received 23 June 2023; Received in revised form 30 August 2023; Accepted 8 September 2023

Available online 12 September 2023

0166-4328/© 2023 The Author(s). Published by Elsevier B.V. This is an open access article under the CC BY-NC license (<http://creativecommons.org/licenses/by-nc/4.0/>).

after several months of infection. Clinical studies revealed alterations in hippocampal connectivity and metabolism. Memory alterations correlated with altered metabolic profiles or changes in grey matter volumes. Hippocampal human postmortem and animal studies observed alterations in neurogenesis, dendrites, and immune response, besides high apoptosis and neuroinflammation. Preclinical studies reported the viral load in the hippocampus. Olfactory dysfunction was associated with alterations in brain functionality. Several clinical studies revealed cognitive complaints, neuropsychological alterations, and depressive and anxious symptomatology.

## 1. Introduction

On March 2020, The World Health Organization [1] declared COVID-19 a global pandemic caused by the severe acute respiratory syndrome coronavirus 2 (SARS-CoV-2) infection. COVID-19 is a multi-systemic disease [2], and a wide range of clinical symptoms affecting COVID-19-positive patients has been reported (for review, see [3]). A significant proportion of subjects has experienced psychological, neurological and neuropsychiatric alterations [4–6] during the acute stage of the illness and post-illness [7], revealing brain sequelae caused by the infection. The aetiology of persistent symptoms points to viral persistence [8,9], virus-induced autoimmunity (autoreactive anti-neuronal antibodies that affect immunomodulatory proteins are detected) [10,11], endothelial dysfunction and alterations in coagulation [12,13]. Interestingly, it has been proposed that the virus can follow different routes, such as neuronal pathways by moving along cranial nerves, vascular/systemic pathways mediated via endothelial cells that traverse the blood-brain barrier (BBB), or through cerebrospinal fluid-containing space [14].

There is strong evidence of brain-related abnormalities in COVID-19. Breakdowns of the BBB [15], hypoxia [7], or neuroinflammation have been found in SARS-CoV-2-infected models [16]. The virus has been found in the brain parenchyma, cerebrospinal fluid and cerebrovascular endothelium [14,17], resulting in apoptosis and necrosis [17]. Neuro-image techniques reveal abnormal brain scans, showing a greater reduction in grey matter thickness and tissue contrast in the orbitofrontal cortex and parahippocampal gyrus [18], alterations in the medial temporal lobe [19], hypometabolism in the cingulate cortex [20], a reduction in global brain size [21], hyperintense and hemorrhagic lesions [19,20], encephalitis [20], and damage of the orbitofrontal cortex and the parahippocampal gyrus [18]. SARS-CoV-2 may also provoke thrombotic vascular problems that affect the medial temporal lobe [22, 23], which could lead to clinical symptoms of amnesia [23].

Interestingly, some of the structural changes caused by the virus in the nervous system are found in the medial temporal lobe. Functionally, some neuropsychological symptoms of COVID-19, such as alterations of verbal memory and long-term visuospatial memory [for review, see [24]], are related to the function of a subcortical region located in this lobe, the hippocampus. Additionally, the olfactory dysfunction found in these patients [25], which suggests impairment of the olfactory pathway functionally connected to the hippocampus, is associated with worse cognition [21,26,27]. The hippocampus is part of the limbic system, and is involved in learning and memory [28,29]. It acts as a central hub for the consolidation of information, receiving projections from cortical and subcortical structures while sending information to other brain structures depending on the requirement [30,31].

There is an increasing interest in exploring what happens in the hippocampus secondary to COVID-19. In this sense, case and clinical studies have revealed abnormal brain imaging in the medial temporal lobe and the hippocampus, affecting its structure and functioning [18, 32–43]. Hippocampal abnormalities have also been assessed in post-mortem studies, observing morphological changes affecting neurons [44,45], glia activation [44–46] and interleukins upregulation [46]. Considering clinical studies, it is important to note that some studies focused on the early stages of the disease [34,38], and others after months of infection [18,32–37,39–43]. In addition, clinical studies have not only used different neuroimaging techniques but also

evaluated the effect of the infection in the hippocampus at different grades of severity of the disease, ranging from patients who show some symptomatology [35–37,43], to Long-COVID syndrome [33,34,40,42]. All these factors may influence the interpretation of the results obtained. Preclinical research showed noticeable results that could be comparable to those found in human studies. When assessing infected animals, studies confirmed the presence of viral RNA in the hippocampus [47–50]. Preclinical research was also conducted to assess hippocampal morphological changes affecting neurons [46,51–53], glial cell activation [46,50–54], and neuroinflammation-associated processes [47,50, 53,54].

This systematic review aims to explore, compile, update, and provide an overview of the available scientific evidence about hippocampal and related cortices structural and functional alterations due to SARS-CoV-2 infection. This review aims to present findings of both clinical and preclinical studies according to their different methodologies used to explore the effects of this disease at different stages and grades of severity. Also, related cognitive and emotional symptomatology is described. This will help to better understand the impact of SARS-CoV-2 infection and address future studies attempting to explore the effect of the virus on this brain region.

## 2. Method

### 2.1. Search and study selection

SCOPUS, Web Of Science (WOS), PubMed and PsycInfo databases were used for the present bibliographic search. No restriction on date of publication was applied. The final search was carried out on October 3rd, 2022. We applied a comprehensive search strategy combining algorithms and keywords related to hippocampal alterations after SARS-CoV-2 viral infection: ((covid-19) OR (2019-ncov) OR (sars-cov-2) OR (cov-19)) AND ((hippocampus) OR (hippocampi) OR (hippocampal gyrus) OR (hippocampal gyri) OR (parahippocampal gyrus) OR (parahippocampal gyri)).

This systematic review was conducted following the recommendations of the Preferred Reporting Items for Systematic Reviews and Meta-Analyses (PRISMA) statement [55].

### 2.2. Inclusion and exclusion criteria

The inclusion criteria used in this systematic review were: (1) clinical and pre-clinical studies including adult samples; (2) Sample size greater than 7 patients or 3 subjects/animals; (3) SARS-CoV-2 infection as the independent variable; (4) Medial temporal lobe outcomes as the dependent variables. The exclusion criteria were: (1) Case studies, review papers, letters to the editor, editorials, brief communications, notes, meeting abstracts and theoretical articles; (2) not written in English; (3) unpublished works that had not undergone peer-review; (4) articles lacking results focused on hippocampal regions.

### 2.3. Screening for inclusion

Two authors performed a blind review of all search results to determine whether the retrieved studies met the criteria. Firstly, after removing duplicates, only titles and abstract were screened, and the articles that did not meet the criteria were excluded. Secondly, the full

texts of the remaining articles were assessed to consider inclusion.

### 3. Results

#### 3.1. Study selection

A total of 383 articles were found in the first identification process. Of them, 210 studies were obtained once duplicates were removed. After reviewing the titles and abstracts, 146 articles were removed. A full-text review was conducted on 62 articles, resulting in the exclusion of 38. Finally, a total of 24 articles were selected for this systematic review (see flowchart in Fig. 1). From the total of articles collected, 13 of them contained clinical (human) studies, 3 post-mortem (human) studies, and 9 included preclinical (non-human) assessment. One article included both post-mortem (human) and preclinical (non-human) samples. The studies are detailed in Table 1 for human clinical (human) studies, in Table 2 for post-mortem (human) studies and in Table 3 for preclinical (non-human) studies.

A data synthesis process was performed to summarize the relevant information. In Table 1, we included sample characteristics, degree of COVID-19 severity (recovered, acute or Long-COVID), comorbidities or treatment employed if hospitalised, mean duration of time elapsed from the onset to the first evaluation, neurological, cognitive, and emotional main findings, neuroimage methodology—including selected technique and condition in which it was applied—and neuroimage findings. In Table 2, we incorporated sample characteristics, comorbidities or treatment employed if hospitalised, neurological findings, brain determinations and brain findings. Finally, in Table 3, we included sample characteristics, type of study (*in vitro*, *in vivo*), behavioural findings, brain determinations and brain results.

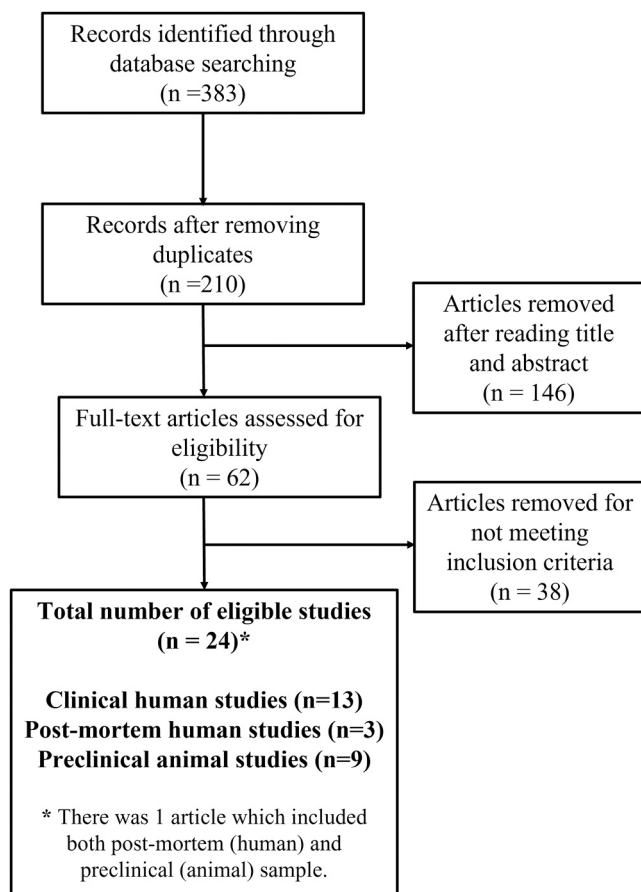


Fig. 1. Flowchart of literature search and study selection process.

#### 3.2. Clinical studies

A total of 13 articles were included in this section.

##### 3.2.1. Sample characteristics

Five studies used cohort designs including a sample size of 22 [35], 47 [41], 51 [39], 60 [43] and 401 [18] subjects infected with the SARS-CoV-2 virus. Cross-sectional studies assessed 14 [37], 26 [38], 30 [32] and 79 [36] patients. Only one study combined cross-sectional and longitudinal designs, with a sample size of 27 participants in the cross-sectional analysis and 1 patient evaluated longitudinally [34]. Two studies employed a retrospective analysis including 35 [33] and 143 [42] infected subjects. Finally, the only prospective study was conducted by Sollini et al. [40] in a sample of 13 COVID participants.

In the clinical trials, 85% of the studies were performed on adults, with participants' average age ranging from 39 to 59 years [18,32,33,35,36,38–43], whereas 15% were conducted on 61- to 74-year-old participants [34,37]. All the studies included males and females. Male and female samples were equal in 15% of the studies [18,37,39]. However, the proportion of females was high in 69% of the studies (54–70%) [32–36,38,39,41,42]. Only 15% of the studies (54–56.7%) included a larger sample of males than of females [40,43]. Considering clinical severity, 38% of the studies included subjects diagnosed with Long-COVID [32–34,40,42], 23% included subjects in the acute or convalescent phase of infection [18,34,38] and 62% included recovered patients studied 3 weeks after recovery [18,34–37,39,41,43]. Of the total number of studies, 62% included hospitalised patients in their sample [18,32,33,35,36,39,41,43]. In these studies, hospitalised patients comprised a mean proportion of 61% of the sample, of which an average of 21% reported some artificial oxygen administration. To note, some studies reported comorbidities, such as diabetes, in 46% of the studies [18,33,39–41,43] hypertension in 38% [33,39–41,43], coronary heart disease in 8% [39] and autoimmune disease in 8% [40]. Overall, the mean duration from infection to assessment varied from 13 to 345 days.

##### 3.2.2. Neurological findings

**3.2.2.1. Olfactory/gustatory alterations.** Olfactory impairment is a frequent symptom. Overall, 69% of the clinical studies reported this alteration [33–38,40,42,43]. However, the percentage of sample reporting this alteration varies between conditions. Regarding acute or convalescent periods, 56% of the articles mentioned this symptomatology, ranging from 3% to 100% of the participants [34–36,38,43], 44% of the sample maintained this symptom in the long-term, 29–100% of the participants [33,34,40,42], while only 33% of studies still observed hyposmia/anosmia after recovery [35,37,43], ranging from 3% to 100% of their sample.

Regarding the association between olfactory impairment and brain functionality, changes in the metabolic state [37,40] and inter-neuronal connections [38] of the insular cortex and hippocampal areas were described in a group of Long-COVID patients with chronic hyposmia. Other studies have observed that hyposmia is inversely correlated with left hippocampal grey matter volume [43].

Taste alterations were mentioned in 54% of the articles [33–36,40,42,43]. In acute phases, 57% of the studies observed ageusia/dysgeusia in 3–71% of their participants [34–36,43]. The same percentage of studies assessing Long-COVID (57%) observed this alteration, shown by 26–75% of their participants [33,34,40,42]. In the recovery stage, only 14% of the participants declared persistent dysgeusia [42]. To note, both Lu et al. [43] and Du et al. [35] observed, respectively, 37% and 5% reduction of this symptom across time.

**3.2.2.2. Sleep alterations.** Data on insomnia problems are present in 31% of the studies [33–35,42]. Martini et al. [34] concluded that

**Table 1**  
Human clinical studies.

First author, year	Sample characteristics Groups N (Age, sex)	COVID-19 severity	Comorbidities/ Treatment	Mean duration of first infection-evaluation (days, weeks, or months)	Neurological findings	Cognitive and emotional findings	Neuroimaging method (condition)	Neuroimage findings
Besteher et al., 2022	Long-COVID group: N = 30 ( $M_{age} = 47.5 \pm 11.5$ ; 56,6% females). Control group: N = 20 healthy subjects ( $M_{age} = 42.95 \pm 13.41$ ; 50% females)	Long-COVID	No relevant comorbidities. 13.33% hospitalised (6.67% with oxygen therapy).	8.65 months	NR	Long-COVID patients showed low scores in general cognition (MoCa) compared to controls. Long-COVID patients showed high scores in depressive symptomatology (MADRS) compared to controls. No differences were detected in anxious symptomatology (STAI).	sMRI, VBM (resting state)	Long-COVID patients showed large GMV in the hippocampus compared to controls. Large hippocampal GMV was inversely associated with the time elapsed between infection and evaluation.
Cattarinusi et al., 2022	COVID-19 group: N = 79 ( $M_{age} = 42.8 \pm 13.8$ ; 58.2% females) Control group: N = 17 healthy subjects ( $M_{age} = 35.8 (\pm 11.7)$ ; 35.3% females)	Recovered	No relevant comorbidities. 28% hospitalised	132 $\pm$ 67 days	Acute phase: 69.9% fever, 42.5% cough, 71.2% fatigue, 68.5% muscular pain, 27.4% sore throat, 23.3% diarrhoea, 8.2% conjunctivitis, 52.1% headache, 35.6% hyposmia and/or hypogeusia, 6.8% skin rash, 37% dyspnea, 19.2% chest pain, 1.4% movement disorders, 1.4% extrapyramidal symptoms. Recovery phase: 55.7% persistent physical symptoms.	COVID-19 group showed a high score in depressive symptomatology (PHQ-9) compared to controls. No differences were detected in anxious symptomatology (GAD-7).	sMRI, fMRI (resting state)	COVID-19 group showed higher ReHo in the right hippocampus compared to controls nine months after infection. There were no differences in the hippocampal grey matter. There was a positive correlation between ReHo in the right hippocampus and depressive symptomatology.
Donegani et al., 2021	COVID-19 group: N = 14 ( $M_{age} = 64.4 \pm 10.9$ ; 50% females) Control group: N = 48 healthy subjects ( $M_{age} = 61.1 \pm 11.1$ ; 79.1% females)	Recovered	NR	8.3 $\pm$ 2.1 weeks	Recovery phase: 100% Hyposmia	NR	[18 F]-FDG PET (resting state)	COVID-19 group showed hypometabolism of the parahippocampal gyrus compared to controls.
Douaud et al., 2022	COVID-19 group: N = 401 ( $M_{age}$ in the first scan: 58.9 $\pm$ 7.0; $M_{age}$ in the second scan: 62.1 $\pm$ 6.7; 57.1% females) Control group: N = 284 healthy subjects ( $M_{age}$ in the first scan: 60.2 $\pm$ 7.4; $M_{age}$ in the second scan: 63.3 $\pm$ 7.1; 57.3% females)	Acute phase in the first scan and recovered phase in the second scan.	Comorbidities: 4.48% diabetes. 3.74% hospitalised, 0.49% ICU (0.72 with oxygen therapy)	141 $\pm$ 79 days (second scan).	NR	COVID-19 group showed worse performance in processing speed/ executive function (TMT) than controls. No differences were detected in processing speed (SDMT).	sMRI, dMRI, fMRI (resting state) task fMRI	COVID-19 group showed a greater reduction in grey matter thickness and grey-white intensity contrast in the parahippocampal gyrus compared to controls. These alterations were similar in hospitalised and non-hospitalised COVID-19 patients.
Du et al., 2022	COVID-19 group: N = 22 ( $M_{age} =$	Recovered (1-year follow-up)	No relevant comorbidities.	345.79 $\pm$ 15.79 days	Hospitalisation: 79% fever, 74% cough, 42%	No differences were detected in anxious or depressive	fMRI (resting state)	COVID-19 group showed increased ALFF values in the

(continued on next page)

Table 1 (continued)

First author, year	Sample characteristics Groups N (Age, sex)	COVID-19 severity	Comorbidities/ Treatment	Mean duration of first infection-evaluation (days, weeks, or months)	Neurological findings	Cognitive and emotional findings	Neuroimaging method (condition)	Neuroimage findings
	54.2 ± 8.7; 57.89% females) Control group: N = 29 healthy subjects (M <sub>age</sub> = 50.5 ± 11.6; 72% females)		100% hospitalised.		dyspnea, 5% (1/18) headache, 37% fatigue, 21% myalgia, 5% (1/18) nausea, 5% (1/18) vomiting, 11% diarrhoea, 5% (1/18) chest pain, 42% hyposmia, 37% hypogeusia. 1-year follow-up: 11% fever, 37% cough, 16% expectoration, 32% dyspnea, 36% headache, 21% fatigue, 36% myalgia, 5% (1/18) decreased appetite, 5% (1/18) nausea, 5% (1/18) diarrhoea, 32% chest tightness, 36% chest pain, 5% (1/18) hyposmia, 5% (1/18) hypogeusia. COVID-19 patients show higher scores of insomnia than healthy controls.	symptomatology (HADS).		hippocampus and parahippocampal gyrus compared to controls.
Esposito et al., 2022	COVID-19 group: N = 27 (M <sub>age</sub> = 39.6 ± 7.8; 62.96% females) Control group: N = 17 healthy subjects (M <sub>age</sub> = 36.2 ± 7.3; 64.70% females)	Recovered in acute stage (< 3 weeks)	NR	13 ± 7.4 days	Convalescence period: 100% hyposmia/anosmia	NR	dMRI, fMRI (resting state)	COVID-19 group showed a lack of functional connectivity between anterior and posterior hippocampus compared to controls. A reduction in the functional connection between the hippocampus and the insula was detected.
Guedj et al., 2021	Long-COVID group: N = 35 (M <sub>age</sub> = 55.06 years ± 11.22; 57.1% females) Control group: N = 44 healthy subjects (M <sub>age</sub> = 55.11 years ± 14.07; 56.8% females)	Long-COVID	Comorbidities: 29% diabetes, 21% hypertension. 39% ICU (16% oxygen therapy)	97 days	29% hyposmia/anosmia, 26% disgeusia/ageusia, 80% dyspnea, 66% pain, 46% insomnia.	Long-COVID group (49% of the sample) self-reported memory/cognitive complaints. Long-COVID group (33% of the sample) reported posttraumatic stress symptomatology (PCLS). A high index was found in patients with cognitive complaints and dysgeusia.	[18 F]-FDG PET (resting state)	Long-COVID group showed hypometabolism in the right temporal lobe (amygdala and the hippocampus) compared to controls. Hypometabolism was associated with pain, insomnia and duration of the symptoms.
Lu et al., 2020	COVID-19 group: N = 60 (M <sub>age</sub> = 44.10 ± 16.00; 43.33% females) Control group: N = 39 healthy subjects (M <sub>age</sub> =	Recovered (3- month follow-up)	Comorbidities: 21.67% Hypertension, 10% diabetes. 100% Hospitalised (61.67% oxygen therapy)	97.46 ± 8.01 days	Acute phase: 25% headache, 5% vision change, 1.67% hearing loss, 6.67% hypogeusia, 3.33% hyposmia, 11.67% impaired mobility, 6.67% numbness in	COVID-19 group (13% of the sample) self-reported memory loss in the acute phase and 28% in the follow-up. COVID-19 group (42% of the sample) self-reported mood	sMRI, dMRI (resting state)	COVID-19 group showed higher GMV in the hippocampus compared to controls. Hippocampal GMV was inversely associated with

(continued on next page)

Table 1 (continued)

First author, year	Sample characteristics Groups N (Age, sex)	COVID-19 severity	Comorbidities/ Treatment	Mean duration of first infection-evaluation (days, weeks, or months)	Neurological findings	Cognitive and emotional findings	Neuroimaging method (condition)	Neuroimage findings
	45.88 ± 13.90; 43.59% females)				extremities, 6.67% tremor, 26.67% fatigue, 15.00% myalgia, Follow-up: 10% headache, 1.67% vision change, 1.67% hearing loss, 1.67% hypogeusia, 3.33% hyposmia, 6.67% impaired mobility, 6.67% numbness in extremities, 1.67% tremor, 6.67% fatigue, 25% myalgia	alterations in the acute phase and 17% in the follow-up.		memory loss and hyposmia.
Martini et al., 2022	COVID-19 group: N = 26 (M <sub>age</sub> = 73.71 ± 11.28; 57.69% females) Control group: N = 125 healthy subjects (M <sub>age</sub> = 65.78 ± 11.33; 53.6% females)	Acute COVID stage, sub-acute COVID stage, Long-COVID	NR	Acute COVID stage: < 1 month Sub-acute COVID stage: 1–3 months, Long-COVID: 5, 7, 9 months	Hyposmia (Acute = 85.71%, 1-m = 100%, 2-m = 75%, 3-m = 100%, 5-m = 40%*, 7–9-m = 100%), Ageusia (Acute = 71.42%, 1-m = 50%, 2-m = 25%*, 3-m = 75%, 5-m = 33.33%*, 7–9-m = 75%), others (disorientation, confusion, headache, sleeplessness, delirium, chronic fatigue syndrome, ageusia)	COVID-19 group showed low scores in general cognition (MMSE) at 1 and 2 months, compared to 3, 5 and 7–9 months. COVID-19 groups (1 and 2 months) showed a worse performance in immediate verbal memory (digit span forward and RAVLT) compared to normative data. COVID-19 groups (2 months) showed a worse performance in verbal fluency, compared to normative data. COVID-19 groups (1 and 7–9 months) showed a worse performance in visuospatial copy (ROCF) compared with normative data. No differences were detected in anxiety (Acute = 0%, 1-m = 50%, 2-m = 50%, 3-m = 0%, 5 m = 33.33%, 7–9-m = 0%) or depressed mood (Acute = 0%, 1-m = 0%, 2-m = 25%, 3-m = 0%, 5 m = 33.33%, 7–9-m = 25%) between COVID-19 subgroups.	[18 F]-FDG PET (resting state)	COVID-19 groups showed hippocampal and parahippocampal gyms hypermetabolism compared to controls. No differences were detected concerning months of infection.
Qin et al., 2021	COVID-19 group: N = 51 n = 19 mild COVID (M <sub>age</sub> : 59.37 ± 5.87; 63.15% females). n = 32 severe	Recovered (3-month follow-up)	Comorbidities: 39.21% Hypertension, 17.64% diabetes, 7.84% coronary heart disease. 100% hospitalised.	101.21 ± 12.24 days (since discharge)	Hospitalization period: Mild group: 68% cough, 84% fever, 11% dyspnea, 21% diarrhoea, 5% headache, 26% fatigue, 11% myalgia, 26% chest	NR	dmMRI, fMRI, (resting state)	COVID-19 severe group showed cortical thickness reduction in left hippocampus and reduced CBF in right hippocampus compared to controls.

(continued on next page)

Table 1 (continued)

First author, year	Sample characteristics Groups N (Age, sex)	COVID-19 severity	Comorbidities/ Treatment	Mean duration of first infection-evaluation (days, weeks, or months)	Neurological findings	Cognitive and emotional findings	Neuroimaging method (condition)	Neuroimage findings
	COVID ( $M_{age}$ : 63.19 ± 5.37; 50% females) Control group: N = 31 healthy subjects ( $M_{age}$ = 60.58 ± 6.42; 41.93% females)				tightness Severe group: 78% cough, 84% fever, 19% dyspnea, 22% diarrhoea, 16% headache, 47% fatigue, 19% myalgia, 43% chest tightness			No differences were detected between mild COVID-19 group and controls.
Sollini et al. 2021	Long-COVID group: N = 13 ( $M_{age}$ = 54; 38.46% females) Control group: N = 26 ( $M_{age}$ = 54; 38.46% females)	Long-COVID	Comorbidities: 23.07% diabetes, 23.07% hypertension, 7.69% autoimmune disease, 30.76% others. NR hospitalization	132 ± 31 days	Long-COVID period: 69.23% Dyspnoea, 7.69% chest pain, 30.76% anosmia and ageusia, 7.69% headache, 15.30% tachycardia, 61.53% fatigue, 23.07% joint pain, 7.69% trembling hands, 7.69% polyneuropathy. NR	NR	[18 F]-FDG PET (resting state)	Long-COVID groups showed hypometabolism in the right parahippocampal gyrus compared to controls. This alteration was present in patients with persistent anosmia/ageusia and fatigue.
Tu et al., 2021	COVID-19 group: N = 47 ( $M_{age}$ = 51.8 ± 11.3; 70.21% females) Control group: N = 43 healthy subjects ( $M_{age}$ = 52.5 ± 11.0; 74.41% females)	Recovered (6-month follow-up)	Comorbidities: 23% hypertension, 6% diabetes. 100% hospitalised (21% oxygen therapy)	50.6 ± 13.2 days (since discharge)		COVID-19 group showed higher depressive (PHQ-9), anxious (GAD-7) and posttraumatic stress symptomatology (PCLS). Sex differences were found, with higher scores in PHQ-9, GAD-7 and PCLS in females.	sMRI, fMRI (resting state)	COVID-19 group showed higher GMV and ALFF in the hippocampus compared to controls.
Verger et al., 2022	Long-COVID group: N = 143 patients (47.4 ± 13.6; 68.53% females) No control group	Long-COVID	NR	10.9 ± 4.8 months	Long-COVID period: Fatigue, pain, insomnia, hyposmia/anosmia, dysgeusia/ ageusia or signs of dysautonomia (tachycardia, orthostatic intolerance and breathlessness)	Long-COVID group (100% of the sample) self-reported memory/cognitive complaints.	[18 F]-FDG PET (resting state)	Long-COVID group (42% of the sample), showed hippocampal and parahippocampal hypometabolism, studied by visual analysis.

\* = one patient data was not available; [18 F]-FDG = 18 F-fluorodeoxyglucose; ALFF = Amplitude of Low-Frequency Fluctuation; CBF = Cerebral Blood Flow; COVID-19 = Coronavirus Disease 2019; dMRI = Diffusion Magnetic Resonance Imaging; fMRI = Functional Magnetic Resonance Imaging; GAD-7 = Generalised Anxiety Disorder Assessment; GMV = Grey Matter Volume; HADS = Hospital Anxiety and Depression Scale; ICU = Intensive Care Unit; Long-COVID = Post-Acute Sequelae of SARS-CoV-2; m = month/s; M = Mean; MADRS = Montgomery-Asberg Depression Rating Scale;  $M_{age}$  = Mean age; MMSE = Minimal State Examination; MoCa = Montreal Cognitive Assessment; MRI = Magnetic Resonance Imaging; N = sample; n = sample per subgroup; NR = Not Reported; PCLS = Posttraumatic Stress Disorder Checklist; PET = Positron Emission Tomography; PHQ-9 = Patient Health Questionnaire; RAVLT = Rey Auditory Verbal Learning Test; ReHo = Regional homogeneity; ROCF = Rey-Osterrieth Complex Figure; SDMT = Symbol Digit Modalities Test; sMRI = Structural Magnetic Resonance Imaging; STAI = State-Trait Anxiety Inventory; TMT = Trail Making Test; VBM = Voxel-Based Morphometry.

25–75% of the patients reported sleep disorders ( $n = 3$  at 1 month;  $n = 2$  at 2 months and  $n = 3$  at 3 months) in the acute and sub-acute stage, but these alterations were also present in Long-COVID samples [34]. Recovered patients showed higher insomnia scores than healthy controls [35]. Interestingly, Guedj et al. [33] observed that chronic insomnia was associated with abnormalities in the right temporal lobe (hippocampus and amygdala).

3.2.2.3. *Physical symptoms: respiratory alterations, fatigue, pain.* Another well-documented symptom was fatigue, pointed out by 54% of the studies [34–36,39,40,42,43]. Of these articles, 57% provided clinical

data from subjects in the acute stage [35,36,39,43], 43% in the recovery period [34,35,43] and 43% in Long-COVID syndrome [34,40,42]. Regarding studies in the acute SARS-CoV-2 infection, the frequency of this symptom fluctuated between 26% and 71.2% [35,36,39,43]. Qin et al. [39] indicated a substantial difference between mild (26%) and severe COVID-19 type (47%). In the recovered patients, these rates vary from 6.7% to 50%. Also, in Long-COVID subjects, a significant prevalence was noted, with rates between 33.3% and 61.5%. Some studies observed fatigue reduction over time. Thus, Lu et al. [43] detected a substantial improvement in this symptom after three months, whereas Du et al. [35] indicated a boost after one year. To note, an association

**Table 2**  
Human post-mortem studies.

Citation	Sample characteristics Groups N (Age, sex)	Comorbidities/ treatment	Neurological findings	Brain determinations	Brain findings
Bayat et al., 2022	COVID-19 group: N = 4 (R <sub>age</sub> = 30–45 years) Control group: N = 4 (R <sub>age</sub> = 30–45 years)	100% ICU (oxygen therapy)	100% anosmia	Microglia (Iba-1; IHC). Astrocyte (GFAP; IHC). Spatial distribution of hippocampal neurons (H&E and Voronoi tessellation method). Apoptosis (Caspase-3; IHC). Neurogenesis (Ki67; IHC). Dendrite morphology (Golgi Cox staining).	COVID-19 group showed a reduction in microglia and astrocyte complexity and length, with a reduction in total number of branches, arbores area, soma roundness, neighbour distance, and regularity, with an increase of the soma size compared to controls. COVID-19 group showed an increase of the neuron area in the granular and pyramidal layers of the dentate gyrus, with an altered spatial distribution and a reduction in total number compared to controls. COVID-19 group showed higher apoptosis in the pyramidal and granular layer of the dentate gyrus compared to controls. COVID-19 group showed a reduction in hippocampal neurogenesis compared to controls. COVID-19 group showed a reduction in complexity, length, and spines of dendrites of pyramidal cells compared to controls.
Poloni et al., 2021	COVID-19 group: N = 9 (M <sub>age</sub> = 77.44 years; 44.44% females) Control group: N = 6 (M <sub>age</sub> = 82.33; 66.66% females)	Comorbidities: 55.55% hypertension, 44.44% dementia, 33.33% cardiovascular disease, 22.22% diabetes, 22.22% atrial fibrillation, 22.22% preexisting MCI, 11.11% obesity, 11.11% chronic obstructive pulmonary disease, 11.11% paraparesis, 11.11% cerebrovascular disease. 11.11% ICU.	55.55% delirium, 88.88% fever, cough and/or dyspnea.	Neuronal loss (H&E and LFB). Microglia (CD68; IHC).	COVID-19 group showed a loss of hippocampal neurons compared to controls. COVID-19 group did not show superior microglia activation in the hippocampus compared to controls. Specific analysis revealed that this result appears in COVID-19 patients with delirium compared to COVID-19 patients without delirium.
Soung et al., 2022	COVID-19 group: N = 14 (M <sub>age</sub> = 73, 21% females) Control group: N = 10 (M <sub>age</sub> = 77, 39% females)	Comorbidities: 29% MCI. 100% hospitalised (57% oxygen therapy)	86% unspecified neurological/psychiatric symptoms.	Virus detection (SARS-CoV-2 mRNA; in situ hybridization) BBB integrity (fibrinogen; IHC) Cytokines (IL-1 $\beta$ and IL-6 in neurons (NeuN) and microglia (Iba-1); IHC) Astrocytes (GFAP; IHC)	COVID-19 group did not show SARS-CoV-2 virus in the hippocampus, but a disruption was detected in the BBB, reflected in the hippocampal tissue. COVID-19 group did not show an increase of activated microglia with cytokine activation in the hippocampus, but there was an increase in neurons marked with cytokine expression in the hippocampus compared to controls. COVID-19 group did not show astrocytic reactivity compared to controls.

BBB = Blood–Brain Barrier; CD68 = Cluster Differentiation 68; COVID-19 = Coronavirus Disease 2019; GFAP = Glial Fibrillary Acidic Protein; H&E = Hematoxylin and Eosin; Iba-1 = Ionized calcium-binding adaptor molecule-1; ICU = Intensive Care Unit; IHC = Immunohistochemistry; IL = Interleukin; Ki67 = Kiel 67; LFB = Luxol Fast Blue; Mage = Mean age; MCI = Mild Cognitive Impairment; mRNA = messenger ribonucleic acid; N = sample; NeuN = neuronal nuclear protein; Rage= age range; SARS-CoV-2 = severe acute respiratory syndrome coronavirus 2.

between hypometabolic changes has been observed in the right parahippocampal gyrus and Long-COVID participants with fatigue [40].

Forty-six per cent of the clinical studies provided information about some kind of pain like myalgia, chest pain or joint pain [33,35,36,39,40,43]. Out of the total, 38% of the articles have presented data for myalgia [35,36,39,40,43], a symptom present in 100% of the acute groups, and in 50% of the recovery stage, with a prevalence of 11 – 68.5% and 25 – 36%, respectively. Chest pain was present in 15% of the studies [35,36], with a prevalence of 5 – 19% in the acute stage. Du et al. [35] detected chest pain in the recovery group, with a prevalence of 36%. Regarding joint pain, it was informed in one study, with a prevalence of 23% of Long-COVID patients. Furthermore, as reported Guedj et al. [33], Long-COVID with no specific pain was associated with hypometabolic patterns located in the right hippocampus and amygdala.

Considering COVID-19 complications which affect the lower respiratory system, such as dyspnoea or chest tightness, 46% of the total number of articles reviewed addressed this problem [33,35,36,39,40,

42]. Thirty-three per cent of these articles declare dyspnoea both in the acute stage and the recovery stage, and half of them in Long-COVID. In the acute infection, 32 – 42% of the participants presented dyspnoea [35,36,39], whereas in the recovery period, this symptom was found in 32% of the sample [35], and it was chronic in 69 – 80% of the Long-COVID patients [33,40,42]. Concerning chest tightness, its prevalence in the acute phase fluctuated from 26% to 43% in mild and severe COVID-19, respectively [39]. Du et al. [35] observed that this symptom was mentioned by 32% of the recovered subjects. In addition, 15% of the articles reported nasopharyngeal symptoms [35,36]. Sore throat was reported in 27% of the patients in the acute stage [36], and 16% presented expectoration after recovery [35].

Also, it has been observed that acute SARS-CoV-2 infection can lead to delirium (43%), confusion (86%) and impaired consciousness (86%) [34].

**3.2.2.4. Other alterations.** Headache, fever, cough, gastrointestinal



**Table 3**  
Preclinical (non-human) studies.

Citation	Sample characteristics Groups N (Age, sex)	In vitro / In vivo	Method of infection	Brain determinations	Behavioural findings	Brain findings
De Oliveira et al., 2022	COVID-19 group: N = 3–5 (Age= 15–16 weeks, females) N = 5 (Age= 18 weeks, male) Control group: N = 4 (Age= 15–16 weeks, females) N = 3 (Age= 18 weeks, male)	In vivo (Syrian hamsters)	Intranasal (SARS-CoV-2)	Virus infection (target gene: sgRNA; qPCR). Cytokines (target genes: sgRNA, IL-6, IL-1 $\beta$ , TNF- $\alpha$ , Isg20, Ifitm3, IFN- $\alpha$ , qPCR). Proteomic analysis (differentially expressed proteins)	NR	COVID-19 group showed SARS-CoV-2 virus presence in the hippocampus at 3, 5, 7 and 14 dpi. COVID-19 group showed increased IL-6, TNF- $\alpha$ , Ifitm3 and IFN- $\alpha$ gene expression compared to controls. COVID-19 group showed differentially expressed proteins in astrocytes, which correlated with synaptic vesicle cycle, oxidative phosphorylation, melanogenesis, long-term potentiation, GnRH signalling, glucagon signalling, glioma, ErbB signalling, dopaminergic and cholinergic synapses. COVID-19 group showed increased reactive microglia in the hilar area of DG of the hippocampus 7dpi and 7wpi compared to controls. COVID-19 group showed reduced neurogenesis in the hilar area of DG of the hippocampus 7dpi and 7wpi compared to controls. COVID-19 group showed an inverse correlation between neurogenesis and reactive microglia in the DG 7dpi compared to controls.
Fernández-Castañeda et al., 2022	COVID-19 group: N = 4–7 (Age=6–12 weeks, females) Control group: N = 3–6 (Age=6–12 weeks, females)	In vivo (CD1 and BALB/c mice)	Intratracheal (SARS-CoV-2)	Microglia reactivity (Iba-1, CD68; IHC). Neurogenesis (DCX; IHC).	NR	COVID-19 group showed increased reactive microglia in the hilar area of DG of the hippocampus 7dpi and 7wpi compared to controls. COVID-19 group showed reduced neurogenesis in the hilar area of DG of the hippocampus 7dpi and 7wpi compared to controls. COVID-19 group showed an inverse correlation between neurogenesis and reactive microglia in the DG 7dpi compared to controls.
Frank et al., 2022	COVID-19 group: N = 5–6 (Age= 2–3 months, male) Control group: N = 5–6 (Age= 2–3 months, male)	In vivo (Sprague-Dawley rats)	Intra-cisterna magna (S1 subunit of SARS-CoV-2 spike protein)	Microglia/macrophage activation (Iba-1, Cd11b, MhcII; mRNA) Microglia/macrophage receptors (Cd200r1 and Cx3cr1; mRNA) Astrocyte activation (GFAP; mRNA) Pattern recognition receptors (Tlr2, Tlr4; mRNA) Inflammasomes (Nlrp3; mRNA) Cytokines (IL-1 $\beta$ , IL-6, TNF; mRNA) Damage-associated molecular patterns (Hmgb1; mRNA) Cytokine/chemokine (IFN $\gamma$ , IL-1 $\beta$ , IL-6, TNF, CXCL1, IL-2 and IL-10; ELISA)	COVID-19 group showed reduced total activity, self-grooming, and wall-rearing compared to controls. COVID-19 group showed increased social avoidance compared to controls.	COVID-19 group showed increased gene expression of microglia/macrophage activation and receptors, astrocyte activation, pattern recognition receptors, inflammasomes, cytokines and damaged-associated molecular patterns 24hpi in the hippocampus compared to controls. COVID-19 group showed increased gene expression of microglia/macrophage activation and receptors, astrocyte activation and inflammasomes 7dpi in the hippocampus compared to controls. COVID-19 group showed increased cytokines at a protein level 24 hpi in all markers regardless IL-6, and the increase was found 7dpi only in TNF in the hippocampus compared to controls.
Jiao et al., 2021	COVID-19 group: N = 7 (Age= 3–5 years, NR) Control group: N = 2 (Age=3–5 years, NR)	In vivo (Rhesus monkeys)	Intranasal (SARS-CoV-2) N = 5 Intracranial (SARS-CoV-2) N = 2	Virus infection (target: SARS-CoV-2 and ACE2 nucleoprotein; qRT-PCR and IF) Microglia/macrophages (CD68; IHC). Cytokines (G-CSF, IL-13, IL-2, IL8, IL-15, IL-18, VEGF) Cellular heterogeneity (targets: microglia, mature neurons, oligodendrocytes,	NR	COVID-19 group showed SARS-CoV-2 virus in the hippocampus 4 and 14 dpi, and in the entorhinal cortex 7 dpi with the intranasal method, and 9 dpi with the intracranial method. COVID-19 group showed increased microglia/macrophage activation in the hippocampus with both intranasal and intracranial methods compared

(continued on next page)

Table 3 (continued)

Citation	Sample characteristics Groups N (Age, sex)	In vitro / In vivo	Method of infection	Brain determinations	Behavioural findings	Brain findings
				endothelial vascular cells; single-cell RNA sequencing)		to controls. COVID-19 group showed cytokine elevation across infection in the hippocampus with both intranasal and intracranial methods compared to controls. COVID-19 group single-cell sequencing study reflected that the inflammatory cytokines induced by SARS-CoV-2 infection downregulated mitochondria-associated genes compared to controls. COVID-19 group did not show SARS-CoV-2 virus presence in the hippocampus. COVID-19 group showed astrocyte activation 5, 8, 17 and 42 dpi in the hippocampus compared to controls. COVID-19 group showed microglia activation in the apical region of the CA1 hippocampus 5, 8, 17 and 42 dpi, and in the basal region 8 and 17 dpi compared to controls. COVID-19 group showed dendritic spine density reduction at 42 dpi in the apical region of the CA1 hippocampus, compared to 8 dpi and controls, but remained stable in the basal region.
Kishimoto-Urata et al., 2022	COVID-19 group: N = 3 (Age= 6 weeks, females) Control group: N = 4 (Age= 6 weeks, females)	In vivo (Syrian hamsters)	Intranasal (SARS-CoV-2)	Virus detection (SARS-CoV-2 nucleocapsid; IHC)Astrocyte (GFAP; IHC) Microglia (Iba-1; IHC) Spine density (Golgi-Cox staining)	NR	COVID-19 group showed astrocyte activation 5, 8, 17 and 42 dpi in the hippocampus compared to controls. COVID-19 group showed microglia activation in the apical region of the CA1 hippocampus 5, 8, 17 and 42 dpi, and in the basal region 8 and 17 dpi compared to controls. COVID-19 group showed dendritic spine density reduction at 42 dpi in the apical region of the CA1 hippocampus, compared to 8 dpi and controls, but remained stable in the basal region.
Oh et al., 2022	COVID-19 group: N = 5 (Age= 8–10 weeks, male) Control group: N = 5 (Age= 8–10 weeks, male)	In vitro (primary cultured hippocampal neurons and glia of E17–18 embryos and one-day-old C57BL/6 pups) / In vivo (C57BL/6 mice)	In vitro: S1 subunit of SARS-CoV-2 spike protein In vivo: Intra-hippocampal (S1 subunit of SARS-CoV-2 spike protein)	In vitro: Survival rate (NeuN and MAP2 staining) Cytokine expression (target: IL-1 $\beta$ , IL-6, TNF- $\alpha$ ; RT-PCR) In vivo: Neuronal death (cresyl violet and NeuN; IHC) Astrocytes (GFAP; IHC) Microglia (Iba-1; IHC)	COVID-19 group showed a reduction in object discrimination. COVID-19 group showed anxiety-related behaviours. COVID-19 group showed conserved locomotor activity.	<u>In vitro:</u> There was a reduction in the survival rate of primary hippocampal neurons, mediated by activated glia. There was an increase of pro-inflammatory cytokines in the dorsal and ventral hippocampus. <u>In vivo:</u> COVID-19 group showed a reduction in neuronal cell density in the CA1 and DG areas of the dorsal (35%) and ventral (20%) hippocampus compared to controls. COVID-19 group showed an increase in astrocytic reactivity in the CA1 and DG areas of the dorsal (59%) and ventral (63%) hippocampus compared to controls. COVID-19 group showed an increase in microglia reactivity and morphological features associated with reactive microglia in CA1 and DG areas of the dorsal hippocampus compared to controls.
Rhea et al., 2021	COVID-19group: N = 3–15 (Age= 6–10 weeks, male) Control group: N = 2–10 (Age= 6–10 weeks, male)	In vivo (CD-1 mice)	Intravenous and intranasal (S1 subunit of SARS-CoV-2 spike protein)	Virus detection (Blood-to brain entry rate, S1 subunit of SARS-CoV-2 spike protein)	NR	COVID-19 group showed SARS-CoV-2 virus in the hippocampus both with intravenous and intranasal methods.
Soung et al., 2022	COVID-19group: NR (Age= 5–6 weeks, male)	In vivo (Syrian hamsters)	Intranasal (SARS-CoV-2)	Virus detection (SARS-CoV-2 mRNA; in situ hybridisation) BBB integrity (extravasated	NR	COVID-19 group did not show SARS-CoV-2 virus in the hippocampus. There was a

(continued on next page)

Table 3 (continued)

Citation	Sample characteristics Groups N (Age, sex)	In vitro / In vivo	Method of infection	Brain determinations	Behavioural findings	Brain findings
	Control group: NR (Age= 8–10 weeks, male)			serum, IHC) Cytokines (IL-1 $\beta$ and IL-6 in neurons (NeuN) and microglia (Iba-1; IHC) Astrocytes (SOX9; IHC) Neurogenesis (Ki67, DCX; IHC)		disruption in the BBB, reflected in the hippocampal tissue. COVID-19 group showed a gradual increase of activated microglia with cytokine activation compared to controls. COVID-19 group did not show astrocytic reactivity compared to controls. COVID-19 group showed a gradual decline neurogenesis: in proliferation, neuroblasts and immature neurons.
Yinda et al., 2021	COVID-19 group: N = 30 (Age= 4–6 weeks, 50% females) Control group: N = 2 (Age= 4–6 weeks, NR)	In vivo (transgenic K18-hACE2 mice)	Intranasal (SARS-CoV-2 low and high dose)	Virus detection (SARS-CoV-2 nucleocapsid; IHC) Edema (H&E staining)	NR	COVID-19 group showed SARS-CoV-2 virus in the hippocampus at 7dpi, but not at 3dpi. COVID-19 groups showed edema and inflammation in the hippocampus at 7dpi, but not at 3dpi.

ACE2 = angiotensin converting enzyme 2; BBB = Blood–Brain Barrier; CA1 = Cornu Ammonis-1; Cd11b= Cluster of Differentiation 11b; Cd200r1 = Cluster of Differentiation receptor 1; CD68 = Cluster of Differentiation 68; COVID-19 = Coronavirus Disease 2019; Cx3cr1 = CX3C Chemokine Receptor 1; CXCL = C-X-C Motif Chemokine Ligand; DCX = Doublecortin; DG = Dentate Gyrus; dpi = day post-infection; ELISA = enzyme-linked immunoassay; ErbB = erythroblastic leukemia viral oncogene; G-CSF = Granulocyte Colony-Stimulating Factor; GFAP = Glial Fibrillary Acidic Protein; GnRH = Gonadotropin hormone-releasing hormone; H&E = hematoxylin and eosin; hACE2 = human angiotensin converting enzyme 2; Hmgb1 = high mobility group box 1; hpi = hours post-infection; Iba-1 = Ionized calcium-binding adaptor molecule-1; IF = Immunofluorescence; Ifitm3 = interferon-induced transmembrane protein 3; IFN- $\alpha$  = Interferon-alfa; IFN $\gamma$  = Interferon gamma; IHC = immunohistochemistry; IL = Interleukin; Isg = Interferon-stimulated gene; K18 = Keratin 18; Ki67 = Kiel 67; LFB = Luxol Fast Blue; MAP2 = Microtubule-associated protein 2; MhcII $\alpha$  = Major Histocompatibility Complex II  $\alpha$ ; mRNA = messenger ribonucleic acid; N = sample; NeuN = neuronal nuclear protein; Nlrp3 = nucleotide-binding domain, leucine-rich-containing family, pyrin domain-containing-3; NR = not reported; qPCR = quantitative polymerase chain reaction; qRT-PCR = quantitative real-time polymerase chain reaction; RNA = ribonucleic acid; RT-PCR = Reverse transcription polymerase chain reaction; S1 = Spike protein subunit 1; SARS-CoV-2 = severe acute respiratory syndrome coronavirus 2; sgRNA = subgenomic ribonucleic acid; SOX9 = SRY-Box Transcription Factor 9; Tlr = Toll-Like Receptor; TNF = tumor necrosis factor; VEGF = vascular endothelial growth factor; wpi = weeks post-infection.

problems, and psychomotor alterations were also found in the studies assessing hippocampal alterations after SARS-CoV-2 infection (for details, see Table 1).

### 3.2.3. Cognitive and emotional findings

Concerning cognitive assessment, 15% of the studies reported low general cognition, assessed with MoCa [32] or MMSE [34], both in acute-stage [34] and in Long-COVID [32]. Martini et al. [34] observed an improvement over time, reflecting lower scores during the first two months compared with 3, 5, and 7–9 months. Twenty-three per cent of the studies described subjective memory or cognitive complaints, observed in the acute phase [43], Long-COVID samples [33,42] and recovered patients [43]. Some studies included data about the percentage of samples affected: Lu et al. [43] reported 13% in the acute phase and 28% at follow-up, and Guedj et al. [33] described this symptom in one-half of the sample. Other authors established neurological impairments and cognitive/memory complaints as inclusion criteria for Long-COVID patients [42]. Neuropsychological assessments revealed alterations in some specific cognitive domains: one study (8%) showed processing speed or executive function deficits in the TMT test in recovered patients [18], while no differences were found when assessed with the SDMT. In addition, Martini et al. [34] detected low scores in the sub-acute COVID-19 group in the Digit Span Forward and RAVLT immediate recall, as well as in verbal fluency. Also, Long-COVID participants showed low visuospatial abilities in the ROCF copy. To note, subjects in the acute phase of the disease showed lower scores in the MMSE compared to those found in sub-acute and recovery patients [34].

Fifty-four per cent of the clinical studies included data about mood disturbances [32–36,41,43]. Regarding depressive symptomatology, it was present in 31% of the studies, both in Long-COVID evaluated with the MADRS [32], recovered patients assessed by the PHQ-9 test [36,41],

and in the study of Martini et al. [34], which found inter-individual differences in depressive symptomatology, with no differences in depressive scores across COVID-19 groups (acute: <1 month; sub-acute: 1–3 months; Long-COVID: 5, 7, 9 months). However, one study (8%) found no depressive symptomatology in recovered patients assessed with the HADS [35]. As for anxiety, 23% of the studies reported disturbances [33,34,41], whereas 23% detected no differences [32,35,36]. The works that assessed this emotional symptom showed higher anxiety scores (GAD-7) and post-traumatic stress symptoms (PCLS) in recovered patients in comparison to healthy subjects [41], as well as at 3 weeks post-infection [33]. Also, the study of Guedj et al. [33] described higher scores in the PCLS in patients suffering from cognitive complaints and dysgeusia. Martini et al. [34] observed inter-individual differences in anxiety but no differences between acute, sub-acute, and Long-COVID-19 groups of patients [34]. Finally, one study (8%) reported general mood disturbances in 42% of the sample affected during the acute phase and a 25% reduction of symptomatology 3 months later [43].

### 3.2.4. Neuroimage findings

MRI was employed by 62% of the clinical trials included in this systematic review [18,32,35,36,38,39,41,43]. The remaining studies used PET scans [33,34,37,40,42]. Concerning MRI, to detect structural alterations, 38% employed sMRI [18,32,36,41,43], and 30% dMRI [18, 38,39,43], whereas 46% of the studies used fMRI to assess functional changes, all of them in the resting state [18,35,38,39,41].

Overall, 77% of the clinical studies found abnormalities in the hippocampus [32–36,38,39,41–43], and 46% in the parahippocampal gyrus [18,34,35,37,40,42].

Concerning abnormalities in the hippocampus, few studies (20%) included measures in the acute or convalescence period [34,38]. One

study—which was performed less than 3 weeks from infection—observed a significant reduction in the connectivity between the anterior and posterior hippocampus, in addition to a reduction in the functional connectivity of the hippocampus with the insula. Similarly, the study of Martini et al. [34] observed hippocampal hypermetabolism at different periods (acute: <1 month; sub-acute: 1–3 months; Long-COVID: 5, 7, 9 months), with no differences concerning months since infection. Forty per cent of the studies observed alterations in patients with Long-COVID syndrome [32–34,42], with one study using structural scans [32] and the remaining three employing PET measures [33,34,42]. Thus, higher grey matter volume was noted compared to healthy volunteers, a result that was more accentuated in participants with shorter time-periods from infection to evaluation [32]. Regarding brain activity, some studies observed hippocampal hypometabolism [33,42]. Specifically, Guedj et al. [33] identified hypometabolic patterns in a selected sample of Long-COVID individuals with and without cognitive impairment compared to healthy controls, and Verger et al. [42] observed similar results in 42% of the sample, which reported subjective cognitive/memory complaints. However, the study of Martini et al. [34] observed the opposite results: hippocampal hypermetabolism. Structural and functional alterations in the hippocampus were also present in recovered patients, which represented 50% of the studies and employed MRI for detection (structural or functional measures) with periods ranging from 3 months to one year [35,36,39,41,43]. Results are diverse. A higher frequency of Regional Homogeneity (ReHo) in the right hippocampus has been observed nine months after the SARS-CoV-2 infection, reflecting abnormalities in the local connectivity for this region, but no changes in hippocampal grey matter [36]. Interestingly, this study observed a correlation between hippocampal connectivity alteration and depressive symptomatology. However, Lu et al. [43] and Tu et al. [41] revealed an increased bilateral grey matter volume in the hippocampus at three [43] and six months after discharge [41], with the study of Lu et al. [43] observing a negative association with memory loss. Also, a higher amplitude of low-frequency fluctuations (ALFF) has been revealed, both 6 months [41] and one year after infection [35], adding alterations in spontaneous neuronal activity. Finally, the study of Qin et al. [39] distinguished between mild or severe symptomatology during the acute phase and observed a reduction in the Cerebral Blood Flow (CBF) signals and cortical thickness in the left hippocampus of the severe group compared to healthy volunteers.

Regarding the studies finding alterations in the brain area that surrounds the hippocampus, that is, the parahippocampal gyrus [18,34,35,37,40,42], similar results can be observed. Thirty-three per cent of the articles included measures in the acute state [18,34]. Interestingly, Douaud et al. [18] conducted a longitudinal study with a cohort of COVID-19 patients that underwent an MRI scan in both the acute and recovery phases approximately four months after infection, detecting a reduction in grey matter thickness and grey-white intensity across time, in both hospitalised and non-hospitalised patients. The study of Martini et al. [34] observed parahippocampal hypermetabolism in patients in the acute, subacute, and long states, with no differences concerning months since infection. Thirty-three per cent of the studies observed alterations in Long-COVID [40,42], showing hypometabolism bilaterally [42] or in the right hemisphere [40]. The remaining 33% were conducted in recovered participants who showed hypometabolic pattern—scans limited to subjects with hyposmia [37]—or increased ALFF values [35].

### 3.3. Post-mortem studies

A total of three articles were included in this section.

#### 3.3.1. Sample characteristics

In the post-mortem studies, infected groups were composed by 4 [44], 9 [45] and 14 [46] tissue samples.

Two of the studies included an average age of the deceased of 76

years, ranging from 69 to 82 years [45,46]. One study had a younger profile with a mean age of 38, with subjects ranging from 30 to 45 years. Two articles included both male and female samples [45,46], one of them with 40% of females [45] and the other with 21% [46]. Bayat et al. [44], did not provide information about sex. Regarding the severity of the SARS-CoV-2 infection, two articles included 100% of the samples, [46] or needing ICU care and the deceased [44], while only one study reported that 11% of the sample required ICU treatment [45]. Oxygen therapy was administered to 57% [46]. One study reported comorbidities such as hypertension in 56% of the sample, dementia in 44%, cardiovascular disease in 33%, diabetes, atrial fibrillation in 22%, and obesity, chronic obstructive pulmonary disease, paraparesis, and cerebrovascular disease in 11% [45], while two studies reported pre-existing cognitive impairment, ranging from 22% to 29% of the sample [45,46].

#### 3.3.2. Neurological findings

All the necropsy examinations have provided evidence of neurological symptoms, including olfactory dysfunction, physical symptoms, and other alterations. Anosmia was described in the total sample of Bayat et al. [44]. Respiratory alterations, such as cough and/or dyspnoea, and fever were also frequent in the sample (89%) of the study by Poloni et al. [45] with delirium only described in 56% of their sample. Unspecified neurological symptoms were present in 86% of the sample studied by Soung et al. [46].

#### 3.3.3. Brain findings

SARS-CoV-2 mRNA virus detection in the hippocampus was conducted in one study and, although no viral load was detected, a disruption of the BBB integrity was found in the hippocampal tissue [46].

Considering the reactivation of glial cells, all the studies evaluated microglia [44–46], and two of them astrocytes [44,46]. Regarding hippocampal microglia, two studies reported no higher microglia activation compared to controls [45,46], or activated microglia with cytokine activation [46]. However, the study of Poloni et al. [45] revealed activated microglia in the hippocampus in patients with delirium, compared to COVID-19 patients without delirium. Specific studies concerning microglia morphology confirmed a reduction in its complexity, length, and regularity (observed by a reduction of the total number of branches, arbores area, soma roundness, neighbour distance, and increased soma size) compared to the control post-mortem sample. As for astrocytes, similar results have been obtained. Soung et al. [46] did not observe astrocyte reactivity, and Bayat et al. [44] showed comparable results to microglia related to astrocytic complexity, length and regularity. To note, one study detected an increased cytokine expression in hippocampal neurons compared to controls [46].

Regarding hippocampal neurons, both Bayat et al. [44] and Poloni et al. [45] revealed neuronal loss, in the latter, not affected by Alzheimer's pathology. Bayat et al. [44] indicated apoptosis in granular and pyramidal layers, as well as morphological alterations, especially in the dentate gyrus. Morphological changes involved neuronal abnormalities in area and spatial distribution. Moreover, a significant reduction in the dendrite complexity, length and number of pyramidal cells and reduced hippocampal neurogenesis assessed in the proliferative stage were detected [44].

### 3.4. Preclinical studies

A total of nine articles were included in this section.

#### 3.4.1. Sample characteristics

Regarding preclinical studies, researchers assessed different experimental samples which include 7 COVID infected Rhesus monkeys [50], 3 hamsters [51], 5 [53], and 30 [49] mice. Other studies employed different sample sizes in their experimental procedures, with sample sizes ranging from 3 to 5 hamsters [47], 3–15 [48] and 4–7 mice [52],

and 5–6 rats [54]. Only one study omitted the number of hamsters used [46].

All the studies used *in vivo* animals to examine the impact of SARS-CoV-2 infection on hippocampal activity [46–54], with one of them adding an *in vitro* analysis [53]. Forty-four per cent of the studies were performed in mice aged 4–12 weeks [48,49,52,53], 33% in hamsters aged 5–18 weeks [46,47,51], 11% in rats aged 8–12 weeks [54], and 11% in non-human primates aged 3–5 years [50]. Of these, 22% included both male and female subjects [47,49], 44% only males [46,48,53,54], 22% only females [51,52], and one study did not report information about sex [50]. Intranasal administration of the virus was conducted in 67% of the trials [46–51]. Other routes of administration were less frequently used, such as intratracheal [52], intravenous [48], intra-cisterna magna [54] and intracranial [50]. Oh et al. [53] injected the virus directly into the hippocampus.

### 3.4.2. Behavioural findings

Twenty-two per cent of the preclinical studies analysed behavioural responses, including exploratory activity, anxiety, and memory [53,54]. Both studies revealed a reduction in normal exploratory activity compared to controls. Frank et al. [54] observed abnormal in-cage behaviours regarding total activity, self-grooming, and wall-rearing, whereas Oh et al. [53] did not report alterations in locomotor activity. Regarding anxiety-like behaviours, both studies reflected alterations in this domain. Oh et al. [53] reported an anxious response in the Elevated Plus Maze (EPM) and the open field, observing a reduction of time spent by infected animals in the open arms of the EPM, and a reduction of time spent in the centre of the open field. Also, Frank et al. [54] observed an accentuated social avoidance in the Juvenile Social Exploration test after infection. Finally, concerning cognition, the COVID-19 group of animals presented worse novel-object and novel-location discrimination [53].

### 3.4.3. Brain findings

SARS-CoV-2 viral infection in the hippocampus was analysed by 67% of the studies that injected the virus intranasally or intravenously [46–51], with most of them (67%) reflecting a viral load in the hippocampus [47–50], and one of them in the entorhinal cortex [50]. To note, the study of Soung et al. [46] did not observe a viral load in the hippocampus directly but did find a disruption in the BBB permeability 3–4 days after the intranasal virus infection. The virus was detected in the hippocampus between 3 and 14 days post-infection [47,49,50] and in the entorhinal cortex between 7 and 9 days post-infection [50]. One study noted that the viral pathogen was not present at 3 days post-infection, but it was detected one week later [49].

Neuroinflammation studied through the activity of immune cells was present in the hippocampus and detected in 44% of the studies [47,50,53,54]. Increased activity of pro-inflammatory cytokines was observed both *in vivo* [47,50,54] and *in vitro* [53]. High expression of anti-inflammatory cytokines [54] and interferon immunity response were also described [47,54]. Inflammatory cytokines induced by SARS-CoV-2 infection were shown to downregulate mitochondria-associated genes [50]. Moreover, other essential mediators in inflammatory pathways, such as Toll-like receptors and the Hmgbl gene, were increased in the hippocampus, and inflammasome-associated genes remained elevated at seven days post-injection [54]. Even after seven days of infection, Yinda et al. [49] found signs of inflammation and cerebral oedema, including the hippocampus.

Regarding glial cell activity, 66% of the studies explored microglia [46,50–54] and 44% astrocytes [46,51,53,54]. Increased gene expression related to microglia/macrophage activation was described one [54] and nine days after infection [50]. Deeper analysis revealed reactive microglia in the hilar white matter of the hippocampal DG from one to seven weeks after infection [52], in the apical region of hippocampal CA1 up to 42 days post-infection, and in the basal CA1 region up to 17

days post-infection [51]. The infection showed morphological CA1 and DG alterations associated with reactive microglia [53]. Interestingly, the study of Soung et al. [46] revealed a gradual increase of activated microglia with cytokine activation. As for astrocytes, reactive astrogliosis was present one day after infection [54] and for up to 42 days [51]. Regarding hippocampal areas, higher astrocytic reactivation was found in the CA1 and DG of the dorsal (59%) and ventral (63%) hippocampus [53]. On the contrary, the study of Soung et al. [46] did not find astrocytic reactivity activation.

Concerning hippocampal neurons, 33% of the studies focused on functional and morphological changes [46,51,52], which can be linked to cognitive functions. SARS-CoV-2 infection leads to a reduction in neurogenesis [46,52], observed in the hilar area of the DG of the hippocampus both one and seven weeks since infection [52]. Soung et al. [46] detected a gradual decline in proliferation, neuroblasts and immature hippocampal neurons, showing that these cells were practically inexistent in the subgranular layer of the DG five days after the viral injection. To note, there was an inverse correlation between neurogenesis and reactive microglia in the DG one week after virus inoculation [52]. Also, *in vitro* analysis observed a reduction in the survival rate of primary hippocampal neurons, mediated by activated glia [53]. Moreover, the study of Kishimoto-Urata et al. [51] observed a reduction in dendritic spine complexity in the apical zone of the CA1, which developed over time, identified at 42 days post-infection, but not 8 days after the virus inoculation.

Finally, one study included proteomic analysis and revealed differentially expressed proteins in astrocytes in the hippocampus, which correlated with synaptic vesicle cycle, oxidative phosphorylation, melanogenesis, long-term potentiation, GnRH signalling, glucagon signalling, glioma, ErbB signalling, and dopaminergic and cholinergic synapses [47].

## 4. Discussion

The main objective of this systematic review was to provide an overview of hippocampal alterations due to SARS-CoV-2 infection. The studies on this topic were performed in clinical, postmortem and preclinical samples. Human studies included mostly female adult participants; only a few of them were performed in aged participants with and without comorbidities, including respiratory alterations, fatigue, pain, insomnia, and olfactory and/or gustatory dysfunction. Males were more prevalent in experimental animal research, conducted only in adulthood. Alterations in the hippocampus were detected in the acute stage and after several months of infection, both in patients classified as recovered and in Long-COVID. Most preclinical studies observed the viral load in the hippocampus, and one human postmortem study revealed disruptions in the BBB integrity. Clinical studies revealed alterations in hippocampal connectivity with its subfields and in functional-related brain areas. Most studies revealed hippocampal hypometabolism, and one study reflected a hypermetabolic stage. Some studies found that memory alterations correlate with altered metabolic profiles or changes in grey matter volumes. Hippocampal human postmortem and animal studies observed a drop in neurogenesis, low dendritic complexity and immune response, and high apoptosis. Also, neuroinflammation was observed due to the reactivity of astrocytes and microglia and the release of pro-inflammatory cytokines. Moreover, the studies described grey matter reduction, hypometabolism and connectivity alterations in the parahippocampal area. Olfactory dysfunction was associated with alterations in brain functionality in some studies. Participants showed subjective cognitive complaints and neuropsychological alterations, both in the acute stage and several months since infection. Specific assessments revealed impaired attention, poor verbal and visuospatial learning, and verbal fluency alterations. Some clinical studies included depressive and anxious symptomatology, with one study observing associations of these psychological symptoms with alterations in hippocampal connectivity. Cognitive and emotional

symptoms were supported by a few preclinical studies that observed cognitive and emotional alterations in their experimental subjects.

Risk factors associated with COVID-19 severity include comorbidities such as diabetes, hypertension, obesity, immunodeficiencies, cardiovascular disease, and chronic lung disease, among others [56,57]. These comorbidities were reported in most of the articles exploring hippocampal function or structure in COVID-19 [18,33,39–41,43,45,46], whereas others did not find potentially associated clinical features [32,35,36] and still others did not provide information about them [34,37,38,42,44]. Apart from these clinical features, disease severity, hospitalisation and number of deaths are correlated with risk factors, including older age [58,59]. However, most of the human studies meeting criteria for inclusion in this review involve middle-aged subjects, and only the postmortem studies incorporate aged subjects. The higher representation of middle-aged samples in clinical studies can be explained by trial adherence [60]. The clinical studies included in this review aimed to observe hippocampal alterations due to SARS-CoV-2 infection; therefore, most of them excluded participants with a previous diagnosis of cognitive impairment, neurodegenerative diseases, neurological disorders, history of brain alterations, or psychopharmacological treatments [32,33,35–40,57,61], which are more prevalent in aged people. However, post-mortem human studies included pre-existing dementia and cognitive impairment within the aged sample [45,46]. These factors are relevant, as there may be an interplay between suffering from dementia and the elevated risk of infection, explained by many reasons, including the clinical and social features of dementia [62,63].

Risk factors for severity and/or mortality also include pre-existing comorbidities, such as diabetes, hypertension, cardiovascular disease, or respiratory disease, among others [57]. These conditions were present in both clinical and postmortem studies, with differential rates [18,33,39–41,43,45,46].

Regarding sex, it has been claimed that male sex is a risk factor for disease severity and hospitalisation [57], whereas the long-COVID syndrome predominantly affects females [64]. Here, we found that almost all the clinical trials include both sexes, with a higher representation of females across samples. Most of the studies that included long-COVID samples showed a higher representation of females than males [32–34,42], in accordance with the higher prevalence of this syndrome in women [65]. However, it is striking that few studies included an independent analysis based on sex and that preclinical non-human studies showed a higher percentage of male samples. The study by Tu et al. [41] reported that females had higher rates of affective symptoms compared to males, and the study of Verger et al. [42] concluded that 75% of the sample presenting hypometabolism in limbic regions were women, suggesting a different metabolic profile in limbic brain areas.

Most of the neuroimaging studies present limitations. The vast majority of neuroimaging studies employed healthy subjects as controls [18,32,41,43], while only one study did not compare groups, visually interpreting as normal or abnormal neuroimages of patients [42]. Although most of the studies include control groups matched in age and sex with COVID cases [18,32,35,38,41,43], some studies count with unequal size of control and COVID groups, which substantially differ in their number of subjects [34,36,37,40]. This may represent a methodological limitation, as it could affect statistical power and type I error rates [66]. Also, acute respiratory distress syndrome, which is commonly developed among COVID patients [67], has been associated with secondary acute brain injury leading to neuroinflammation and neuronal damage within the hippocampus, being the hypoxic ischemic injury from hypoxic respiratory failure a potential mechanism of brain alterations in patients suffering acute respiratory distress syndrome [68]. Interestingly, Thakur et al. [69] studied patients with SARS-CoV-2 infections and observed hypoxic damage with neuronal shrinkage, reactive astrocytosis, and neovascularization widespread within the brain, most prominently in the brainstem with only some individuals

(22%) showing a focal damage in the hippocampus, suggesting that hypoxia-ischaemia could contribute to neurological damage. Thus, it could be more appropriate to include patients with respiratory infections as control group in the studies of neuropsychological alterations after COVID-19. In this way it would be possible to elucidate to what extent primary infection of the brain or respiratory disease are significant contributing factors of neurological alterations after SARS-CoV-2 infection. This is particularly important when assessing the effects of the virus on the hippocampus, as this region is strongly affected by hypoxic-ischaemic damage [70].

COVID-19 infection can result in symptoms limited to the acute or post-acute stage or long-term alterations, known as long-COVID syndrome when occurring beyond 3 months since infection and lasting at least 2 months [1]. In the acute phase, the symptoms vary and can include headache, fever, fatigue, dyspnea, cough, anosmia/ageusia, myalgia, skin rash, or gastrointestinal problems. Symptoms can also extend to a more complex profile, with hypoxia, respiratory failure, multiple organ failure, and neurological and/or neuropsychological complications [71]. In long-COVID syndrome, the above-mentioned symptoms may be present, and also long-term neuropsychological alterations [72,73]. In this line, the studies that included information about symptoms during the acute stage—both clinical and post-mortem—revealed common COVID-19-associated symptomatology [34–36,38,39,44–46]. Moreover, many of these symptoms were detected after the acute phase, both in patients classified as recovered [35–37,43] or as long-COVID [33,34,40,42]. At this point, it is important to note that the distinction between recovered and long-COVID syndrome is difficult to assess in these reports, so we have shown the classifications provided by the authors. It may be important to consider that some of the patients classified as recovered presented persistent physical symptoms, but their cognitive skills were not explored [35,36,39,43], and some of them declared subjective memory loss [43]. Also, the severity of the disease may be associated with persistent symptoms, although this is not essential, as some studies have shown that many patients suffering the whole spectrum of severity (mild, moderate, severe) can be affected by long-COVID [74]. In this systematic review, we found that 62% of the studies included hospitalised patients with variations in their need for oxygen administration [18,32,33,35,36,39,41,43].

Insomnia problems were present in 31% of the clinical studies [33–35,42]. The study of Guedj et al. [33] observed a correlation between sleep disturbances and abnormalities in the right temporal lobe. However, none of the reviewed studies assessed associations between sleep alterations and cognitive functions. Considering the critical role of sleep in cognition [75] and the involvement of hippocampal functionality in memory consolidation [76], it may be interesting to include data about sleep when studying memory function.

Regarding the hippocampal structural and functional alterations due to SARS-CoV-2 infection, hippocampal abnormalities were present in all the postmortem and preclinical studies and most of the clinical studies (77%), most of them using neuroimaging assessment, which also reported alterations in the parahippocampal gyrus (46%). These alterations were observed at different periods from the onset of the disease. First, we note that several clinical and preclinical studies found a virus load in the hippocampus, and one study observed a disruption of the BBB integrity near the hippocampal tissue [46]. Viral load in the entorhinal cortex was demonstrated preclinically [50], revealing that the virus is present in the brain through an intranasal route. This knowledge provided the basis for developing intranasal vaccines [77].

Reduction in the connectivity between the anterior and posterior hippocampus, as well as in the hippocampal-insula connections, was observed less than 3 weeks since infection [38]. These connectivity failures are present in dementia [78] or psychosis [79], among other brain disorders. Interestingly, a longitudinal study that assessed whole-brain connectivity in COVID-19 survivors observed slight improvements in structural brain connectivity and cognitive performance over time, signalling a reduction in path length, which reflects decreased

information transmission across brain networks [80]. Also, the higher frequency of ReHo in the right hippocampus, with no changes in the grey matter [36], indicates alterations in the local functional-connectivity activity [81], also altered in some neuropsychological conditions [81,82]. In the same line, the higher ALFF values [35,41] suggest alterations in spontaneous neuronal activity, as found in depression [83] or cognitive impairment [84].

How the virus may alter hippocampal activity is not completely understood. Some studies reported hippocampal hypometabolism [33, 37,40,42], which is spread over the medial temporal lobe, including the olfactory gyrus, and, in turn, affecting connected limbic/paralimbic regions [33]. Almost all the measures were performed in the resting state, and the results were reported in samples with cognitive impairment [33,42] and also in studies not addressing this issue [37,40]. Memory complaints have been previously associated with decreased hippocampal metabolic activity, sometimes considered as a marker of subclinical changes in clinical cognitive decline [85,86]. Also, some studies observed a reduction in the CBF with hippocampal atrophy in the left hippocampus [39]. However, hippocampal hypermetabolism was also found in other studies [34]. Moreover, grey matter increased in both hippocampi [41,43], and this was associated with memory alterations [43]. Studies not including the hippocampus revealed that in the acute stage, hypermetabolic brain activity is more likely, while hypometabolism is more frequently present in Long-COVID [87]. In the present review, we included one longitudinal study with a sample that was followed-up over 9 months since the infection in which hypermetabolism was present at the initial stage and in the follow-up, associated with high inflammatory status [34]. The rest of the reviewed studies found hypometabolism in recovered or Long-COVID patients [33,37,40, 42], supporting the shift between hyper- to hypometabolic activity in the hippocampus and related areas over time after infection. Hypometabolism in the hippocampus or related regions was associated with some symptomatology, such as persistent Long-COVID symptoms [40] or pain, insomnia, and duration of the symptoms [33].

Also, alterations were found in the parahippocampal area—a critical structure connected with the hippocampus—, where reductions in grey matter thickness and hypometabolism were observed [18,34,35,37,40, 42]. The study of Donegani et al. [37] found that hypometabolism was present in patients with hyposmia, and Du et al. [35] observed increased ALFF values, similar to results within the hippocampus.

The hippocampal neuroimage results are combined with those directly exploring its activity or structure in postmortem human or animal studies. One postmortem human study described a drop in neurogenesis [44], probably affected by neuroinflammation, which also decreased stem cell proliferation [44]. Moreover, the hippocampus also showed decreased dendritic length and number of dendritic spines, suggesting a reduction in synaptic plasticity, with may affect memory function [44]. These results were observed in animals, which confirmed a drop in neurogenesis [46,52], with a gradual decline in proliferation, neuroblasts and immature hippocampal neurons following infection [46]. A reduction in dendritic spine complexity in the apical zone of CA1 was also observed [51]. The drop in neurogenesis may be caused by neuroinflammation. It is known that reactive microglia can impair the generation of new hippocampal neurons, leading the cytokines or chemokines to a direct inhibition of hippocampal neurogenesis [52]. Hence, it has been found that a drop in neurogenesis correlates with higher reactive microglia in the dentate gyrus (DG) [52]. As demonstrated *in vitro*, the survival rate of primary hippocampal neurons is mediated by activated glia [53]. It has been hypothesized that the release of pro-inflammatory cytokines participates in immune system-to-brain communication by activating resident microglia in the brain. Then, the microglia suppresses neuronal stem cell proliferation, increases deaths in neuronal progenitor cells, and decreases survival rate in newly developed neurons and their integration into existing neuronal circuits, acting in all the neurogenesis phases and leading to a general drop in this process [88]. Thus, the effect of activated glial cells may affect

communication between neurons and neurogenesis [89].

In addition, SARS-CoV-2 infection can lead to hippocampal apoptosis [44,45], observed in pyramidal cells of the CA1 and granular cells of DG with markers of neuroinflammation following astrocyte and microglia reactivity [44]. Glial reactivity leads to oxidative stress and provokes the expression of tropomyosin receptor kinase B (TrkB), IL-1 $\beta$ , phosphorylated-nuclear factor kappa B (p-NF-kB) and TNF- $\alpha$ , which affects neuronal survival, learning and memory [44].

Concerning SARS-CoV-2-induced inflammation, postmortem human studies found that the virus induces activation of microglia and astrocytes in the hippocampus [45,46]. Astrocytes and microglia also presented a reduction in complexity, length and regularity [46]. Microglia can be considered the virus's target, causing its activation and later local cytokine storm, leading to neurotoxic effects. Inflammatory microglia mediators can also activate pro-inflammatory astrocytes [44]. Preclinical studies have shown increased gene expression related to microglia/macrophage activation [50,54], increased reactive microglia and astrocytes [46,51–53], and changes in microglial morphology, associated with reactive microglia [53]. The pro-inflammatory cytokine release has been seen *in vivo* [47,50,54] and *in vitro* [53] anti-inflammatory cytokines [54], and interferon immunity response [47,54]. Alterations in gene expression are present in astrocytes, reflecting that SARS-CoV-2 can provoke changes both in the metabolic and proteomic profile of these glial cells, suggesting a possible mediation of CNS impairment [47]. Furthermore, it has been shown that inborn errors of interferon immunity can explain the critical disease in some patients, as well as T-cell reactivity, which triggers a broad B-cell activation and may result in functional immune dysregulation [12].

However, it must be taken into consideration that, in contrast to neuroimaging findings focused on the hippocampal alterations, neuropathological evidence also points towards brainstem involvement [90, 91]. The neuropathological findings from autopsies of patients with COVID-19 showed evidence of neuroinflammation with activation of innate and adaptive immune cells in the brainstem of COVID patients when comparing with controls with histories of severe respiratory failure [92]. In this sense, a recently published study that assessed many brain regions, including the hippocampus, which also included matched controls of pneumonia or respiratory failure, revealed an anatomically segregated pattern of inflammation mainly within brainstem regions [93].

The cells contained in the olfactory system connect the nasal epithelium with the medial forebrain (septum), preoptic area, and hypothalamus, and mechanisms of infection include populations with a higher binding affinity of the ACE-2, with higher viral loads in the nasal epithelium [57,94], but also in other organs and in the CNS [95]. Cell types in the olfactory epithelium may accumulate the virus after infection, and cascades of cellular events also appear [14]. The olfactory system projects to the orbitofrontal cortex, amygdala, hypothalamus, insula, entorhinal cortex, hippocampus, and parahippocampal cortex [96], and a volume reduction in some of these structures can be observed after infection [18]. SARS-CoV-2 neurotropism could spread to limbic/paralimbic brain structures through the olfactory bulb [33]. Recently, it has been observed that COVID-19 patients with anosmia show differences in the functional connectivity of the olfactory system, with increased functional connectivity in the left orbitofrontal cortex, visual association cortex, and cerebellum, and reduction in the right orbitofrontal cortex, and anterior cingulate cortex. Also, greater CBF has been observed in the posterior cingulate cortex, insula and hippocampus [97]. Reduction of smell and taste are common symptoms of COVID-19 infection [14]. Almost 70% and 50% of the reviewed clinical studies reported anosmia and taste alterations, respectively.

Some studies observed hippocampal and insula metabolic alterations in patients with hyposmia [37,38,40]. This symptom was associated with reduced hippocampal grey matter, suggesting that the virus may enter the CNS via the olfactory bulb-mediated neuronal retrograde route [43]. Esposito et al. [38] observed that olfactory dysfunction leads to

changes in the piriform area connections, the main receptor of afferent projections from the olfactory bulb. In this line, it may be of interest to address studies analysing associations between olfactory alterations and memory performance. Cognitive sequelae are more likely to appear in patients suffering from olfactory dysfunction, revealing a particular worsening in associative incidental learning and long-term procedural memory [98] maybe due to a dysfunction of the limbic system, which is involved both in declarative [99] and procedural memory consolidation [100].

Complaints about cognition after suffering from SARS-CoV-2 infection are widely reported, as well as the feeling of being mentally slow or fuzzy—usually known as brain fog [101]. Neuropsychological assessment has revealed that some subjects can have impaired attention, executive functions, and memory (reviewed by [24,102]), with no associations with the severity of the disease [24]. In this systematic review, some of the studies included data about subjective cognitive complaints [33,42,43] and objective neuropsychological impairments [32,34] that were present at the acute stage of the infection and in the long-term. Specific assessments revealed impaired attention [18], visuospatial ability, immediate verbal recall, and verbal fluency alterations [34], which improved over time [34], suggesting the need to study patients with neuropsychological alterations longitudinally to determine the progression of the symptoms. These studies describing neuropsychological alterations also observed hippocampal hypometabolism [33,42], hippocampal hypermetabolism [34], increases in hippocampal volume grey matter [32,43], and reduction in parahippocampal grey matter thickness and grey-white intensity [18]. Nevertheless, only the study of Lu et al. [43] negatively associated the increment of hippocampal grey matter volume with subjective memory loss, suggesting the importance of addressing specific correlations between cognitive alterations and brain structural/functional changes. Preclinically, Oh et al. [53] also supported cognitive alterations, as poorer novel object and novel location discrimination have been found, with alterations in hippocampal apoptosis and glial cell-related inflammation [53]. In particular, it is known that discrimination of novel locations involves the hippocampus, but novel object recognition primarily needs the perirhinal cortex [103].

Subjective memory complaints and results derived from cognitive screening tests, such as the MoCa and MMSE, are unspecific and difficult to relate to specific neurobiological bases. However, specific measures in certain cognitive domains add valuable information. The study of Douaud et al. [18] which revealed attention or executive deficits, observed reductions in grey matter and white matter in the parahippocampal gyrus—a limbic brain area essential in episodic memory, also associated with executive functions [104]. Furthermore, this structure is connected with the piriform cortex, a brain area that conforms the olfactory system [105]. These authors also observed alterations in the orbitofrontal cortex—which may better explain the cognitive deficits found, due to its involvement in attentional switching [106], as well as the reduction in global brain size after infection [18]. Moreover, Martini et al. [34] reported verbal learning immediate recall and verbal fluency alterations two months after infection, also finding hippocampal and parahippocampal hypermetabolism and visuospatial immediate recall deficits in the acute stage and at 7 months. However, although short-term declarative memory relies on the hippocampus [107,108], the neuropsychological assessment was only performed in a subgroup of SARS-CoV-2 patients, so it was not possible to relate these functional alterations directly with hippocampal impairment. Further, the neurobiological substrates of COVID-19 cognitive impairment may also include frontal lobe dysfunction [62].

Finally, regarding mood disturbances, suffering from COVID-19 disease may affect cognition due to emotional disturbances or stress [62]. In this systematic review, clinical samples were affected by mood disturbances, including depressive symptomatology [32,34,36,41] and anxiety [33,34,41]. The study of Cattarinussi et al. [36] revealed a positive correlation between alterations in the local hippocampal

connectivity and depressive symptomatology. Preclinical animal studies observed anxiety-like behaviours, reductions in locomotor activity, and high social avoidance [53,54], possibly reflecting an illness response or a consequence of hippocampal impairment. In fact, Oh et al. [53] observed hippocampal cell-death in their experimental subjects. Interestingly, it has been observed that the alterations in hippocampal connectivity are associated with depressive scores [36], supporting the hypothesis about hippocampal integrity and anxiety. In terms of connectivity, it is known that the hippocampus interacts with the amygdala during the encoding of emotional memories, which is important during anxiety. It has been hypothesized that COVID-19 survivors—due to the negative feelings they might have experienced—present hyperactivation in the amygdala and hippocampus [41], which may also mediate cognitive disturbances.

To the best of our knowledge, this review represents one of the few attempts to update the existing scientific literature aimed at assessing functional and structural alterations in the hippocampus and related cortices in COVID-19, including human clinical studies, human post-mortem studies and studies of animals subjected to SARS-CoV-2 infection. This review aimed to understand the progress of these alterations, covering all the stages of the disease (acute, long-COVID or recovered sample) and describing related cognitive and emotional symptomatology. Limitations of this review include difficulties in finding consistency in results, as the studies presented high heterogeneity in their samples, methods and description of variables, such as clinical symptoms. Nevertheless, our review helps to highlight the gaps in the literature. Future research is needed to delve into the hippocampal and related areas' function or structure after SARS-CoV-2 infection, including better control groups of respiratory failure and correlational analysis of relevant variables such as cognitive/emotional measures, as well as other clinical data, such as olfactory dysfunction or sleep alterations. Longitudinal studies of the evolution of SARS-CoV-2 hippocampal and cognitive/emotional alterations, differentiating between groups of patients according to their sex, age, severity, and main symptoms, are also needed. This would allow the scientific community and health professionals to better understand the neuropsychology of long-COVID and design future interventions.

## Funding

Gobierno de Aragón (Departamento de Ciencia, Universidad y Sociedad del Conocimiento) para el grupo S31\_23R; Conselleria d'Innovació, Universitats, Ciència i Societat Digital de la Generalitat Valenciana [GVA-COVID19/2021/025].

## Declaration of Competing Interest

None.

## Data Availability

No data was used for the research described in the article.

## References

- [1] WHO, WHO Coronavirus (COVID-19) Dashboard, Geneva World Heal. Organ. 2022.
- [2] J. Yasuhara, T. Kuno, H. Takagi, N. Sumitomo, Clinical characteristics of COVID-19 in children: A systematic review, *Pediatr. Pulmonol.* 55 (2020) 2565–2575, <https://doi.org/10.1002/ppul.24991>.
- [3] J. Li, et al., Epidemiology of COVID-19: A systematic review and meta-analysis of clinical characteristics, risk factors, and outcomes, *J. Med. Virol.* 93 (2021) 1449–1458, <https://doi.org/10.1002/jmv.26424>.
- [4] T.M. Schou, S. Joca, G. Wegener, C. Bay-Richter, Psychiatric and neuropsychiatric sequelae of COVID-19 – A systematic review, *Brain. Behav. Immun.* 97 (2021) 328–348, <https://doi.org/10.1016/j.bbi.2021.07.018>.
- [5] F. Ceban, et al., Fatigue and cognitive impairment in Post-COVID-19 Syndrome: A systematic review and meta-analysis, *Brain. Behav. Immun.* 101 (2022) 93–135, <https://doi.org/10.1016/j.bbi.2021.12.020>.



- [6] J.B. Badenoche, et al., Persistent neuropsychiatric symptoms after COVID-19: a systematic review and meta-analysis, *Brain Commun.* 4 (2022), <https://doi.org/10.1093/braincomms/fcab297>.
- [7] N. Barizien, et al., Clinical characterization of dysautonomia in long COVID-19 patients, *Sci. Rep.* 11 (2021) 1–7, <https://doi.org/10.1038/s41598-021-93546-5>.
- [8] C. Gaebler, et al., Evolution of antibody immunity to SARS-CoV-2, *Nature* 591 (2021) 639–644, <https://doi.org/10.1038/s41586-021-03207-w>.
- [9] J. Meinhardt, et al., Olfactory transmucosal SARS-CoV-2 invasion as a port of central nervous system entry in individuals with COVID-19, *Nat. Neurosci.* 24 (2021) 168–175, <https://doi.org/10.1038/s41593-020-00758-5>.
- [10] B.K. Patterson, et al., Immune-Based Prediction of COVID-19 Severity and Chronicity Decoded Using Machine Learning, *Front. Immunol.* 12 (2021) 1–13, <https://doi.org/10.3389/fimmu.2021.700782>.
- [11] S.W.X. Ong, et al., Persistent symptoms and association with inflammatory cytokine signatures in recovered coronavirus disease 2019 patients, *Open Forum Infect. Dis.* 8 (2021) 1–9, <https://doi.org/10.1093/ofid/ofab156>.
- [12] C. Human, G. Effort, Studying severe long COVID to understand post-infectious disorders beyond COVID-19, *Nat. Med.* 28 (2022) 879–882, <https://doi.org/10.1038/s41591-022-01766-7>.
- [13] D. Castanares-Zapatero, et al., Pathophysiology and mechanism of long COVID: a comprehensive review, *Ann. Med.* 54 (2022) 1473–1487, <https://doi.org/10.1080/07853890.2022.2076901>.
- [14] R. Butowt, C.S. von Bartheld, Anosmia in COVID-19: Underlying Mechanisms and Assessment of an Olfactory Route to Brain Infection, *Neuroscientist* 27 (2021) 582–603, <https://doi.org/10.1177/1073858420956905>.
- [15] S. Krasemann, et al., The blood-brain barrier is dysregulated in COVID-19 and serves as a CNS entry route for SARS-CoV-2, *Stem Cell Rep.* 17 (2022) 307–320, <https://doi.org/10.1016/j.stemcr.2021.12.011>.
- [16] R. Klein, et al., COVID-19 induces neuroinflammation and loss of hippocampal neurogenesis, *Res. Sq.* (2021) 1–21, <https://doi.org/10.21203/rs.3.rs-1031824/v1>.
- [17] G. Aghagholi, B. Gallo Marin, N.J. Katchur, F. Chaves-Sell, W.F. Asaad, S. A. Murphy, Neurological involvement in COVID-19 and potential mechanisms: a review, *Neurocrit. Care.* 34 (2021) 1062–1071, <https://doi.org/10.1007/s12028-020-01049-4>.
- [18] G. Douaud, et al., SARS-CoV-2 is associated with changes in brain structure in UK Biobank, *Nature* 604 (2022) 697–707, <https://doi.org/10.1038/s41586-022-04569-5>.
- [19] S. Kremer, et al., Brain MRI findings in severe COVID-19: a retrospective observational study, *Radiology* 297 (2020) E242–E251, <https://doi.org/10.1148/radiol.2020202222>.
- [20] J. Hugon, E.F. Msika, M. Queneau, K. Farid, C. Paquet, Long COVID: cognitive complaints (brain fog) and dysfunction of the cingulate cortex, *J. Neurol.* 269 (2022) 44–46, <https://doi.org/10.1007/s00415-021-10655-x>.
- [21] J.W. Park, X. Wang, R. Xu, Revealing the mystery of persistent smell loss in Long COVID patients, *Int. J. Biol. Sci.* 18 (2022) 4795–4808, <https://doi.org/10.7150/ijbs.73485>.
- [22] R. Werner, M. Keller, J.C. Woehle, Increased incidence of transient global amnesia during the Covid-19 crisis? *Neurol. Res. Pract.* 2 (2020) <https://doi.org/10.1186/s42466-020-00077-x>.
- [23] R.S. Ramanathan, A. Wachsmann, Coronavirus disease-19 (COVID-19) related acute stroke causing transient global amnesia, *J. Stroke Cerebrovasc. Dis.* 30 (2020), 105738, <https://doi.org/10.1016/j.jstrokecerebrovasdis.2021.105738>.
- [24] T. Llana, C. Zorzo, M. Mendez-Lopez, M. Mendez, Memory alterations after COVID-19 infection: a systematic review, *Appl. Neuropsychol. Adult.* (2022) 1–14, <https://doi.org/10.1080/23279095.2022.2123739>.
- [25] M. Trott, R. Driscoll, S. Pardhan, The prevalence of sensory changes in post-COVID syndrome: A systematic review and meta-analysis, *Front. Med.* 9 (2022), <https://doi.org/10.3389/fmed.2022.980253>.
- [26] R. Furlan, et al., Covid-19, Association between chemosensory impairment with neuropsychiatric morbidity in post - acute COVID - 19 syndrome: results from a multidisciplinary cohort study, *Eur. Arch. Psychiatry Clin. Neurosci.* 273 (2022) 325–333, <https://doi.org/10.1007/s00406-022-01427-3>.
- [27] A. Di Stadio, et al., Olfactory dysfunction, headache, and mental clouding in adults with long-COVID-19: what is the link between cognition and olfaction? A cross-sectional study, *Brain Sci.* 12 (2022) 154, <https://doi.org/10.3390/brainsci12020154>.
- [28] H. Eichenbaum, P. Dudchenko, E. Wood, M. Shapiro, H. Tanila, The hippocampus, memory, and place cells: is it spatial memory or a memory space? *Neuron* 23 (1999) 209–226, [https://doi.org/10.1016/s0896-6273\(00\)80773-4](https://doi.org/10.1016/s0896-6273(00)80773-4).
- [29] C.M. Bird, N. Burgess, The hippocampus and memory: Insights from spatial processing, *Nat. Rev. Neurosci.* 9 (2008) 182–194, <https://doi.org/10.1038/nrn2335>.
- [30] S. Poulter, T. Hartley, C. Lever, The Neurobiology of Mammalian Navigation, *Curr. Biol.* 28 (2018) R1023–R1042, <https://doi.org/10.1016/j.cub.2018.05.050>.
- [31] D.G. Amaral, M.P. Witter, The three-dimensional organization of the hippocampal formation: A review of anatomical data, *Neuroscience* 31 (1989) 571–591, [https://doi.org/10.1016/0306-4522\(89\)90424-7](https://doi.org/10.1016/0306-4522(89)90424-7).
- [32] B. Besteher, et al., Larger gray matter volumes in neuropsychiatric long-COVID syndrome, *Psychiatry Res. J.* 317 (2022), <https://doi.org/10.1016/j.psychres.2022.114836>.
- [33] E. Guedj, et al., 18F-FDG brain PET hypometabolism in patients with long COVID, *Eur. J. Nucl. Med. Mol. Imaging* 48 (2021) 2823–2833, <https://doi.org/10.1007/s00259-021-05215-4>.
- [34] A.L. Martini, et al., Time-dependent recovery of brain hypometabolism in neuro-COVID-19 patients, *Eur. J. Nucl. Med. Mol. Imaging* 50 (2022) 90–102, <https://doi.org/10.1007/s00259-022-05942-2>.
- [35] Y.Y. Du, et al., Survivors of COVID-19 exhibit altered amplitudes of low frequency fluctuation in the brain: A resting-state functional magnetic resonance imaging study at 1-year follow-up, *Neural Regen. Res.* 17 (2022) 1576–1581, <https://doi.org/10.4103/1673-5374.327361>.
- [36] G. Cattarinussi, et al., Altered brain regional homogeneity is associated with depressive symptoms in COVID-19, *J. Affect. Disord.* 313 (2022) 36–42, <https://doi.org/10.1016/j.jad.2022.06.061>.
- [37] M.I. Donegani, et al., Brain metabolic correlates of persistent olfactory dysfunction after sars-cov-2 infection, *Biomedicines* 9 (2021), <https://doi.org/10.3390/biomedicines9030287>.
- [38] F. Esposito, et al., Olfactory loss and brain connectivity after COVID-19, *Hum. Brain Mapp.* 43 (2022) 1548–1560, <https://doi.org/10.1002/hbm.25741>.
- [39] Y. Qin, et al., Long-term microstructure and cerebral blood flow changes in patients recovered from COVID-19 without neurological manifestations, *J. Clin. Investig.* 131 (2021), e147329, <https://doi.org/10.1172/JCI147329>.
- [40] M. Sollini, et al., Long COVID hallmarks on [18F]FDG-PET/CT: a case-control study, *Eur. J. Nucl. Med. Mol. Imaging* 48 (2021) 3187–3197, <https://doi.org/10.1007/s00259-021-05294-3>.
- [41] Y. Tu, et al., Post-traumatic stress symptoms in COVID-19 survivors: a self-report and brain imaging follow-up study, *Mol. Psychiatry* 26 (2021) 7475–7480, <https://doi.org/10.1038/s41380-021-01223-w>.
- [42] A. Verger, A. Kas, P. Dudouet, F. Goehringer, D. Salmon-Ceron, E. Guedj, Visual interpretation of brain hypometabolism related to neurological long COVID: a French multicentric experience, *Eur. J. Nucl. Med. Mol. Imaging* 49 (2022) 3197–3202, <https://doi.org/10.1007/s00259-022-05753-5>.
- [43] Y. Lu, et al., Cerebral micro-structural changes in COVID-19 patients – an MRI-based 3-month follow-up study: a brief title: cerebral changes in COVID-19, *EclinicalMedicine* 25 (2020), 100484, <https://doi.org/10.1016/j.eclinm.2020.100484>.
- [44] A.H. Bayat, et al., COVID-19 causes neuronal degeneration and reduces neurogenesis in human hippocampus, *Apoptosis* 27 (2022) 852–868, <https://doi.org/10.1007/s10495-022-01754-9>.
- [45] T.E. Poloni, et al., COVID-19-related neuropathology and microglial activation in elderly with and without dementia, *Brain Pathol.* 31 (2021) 1–16, <https://doi.org/10.1111/bpa.12997>.
- [46] A.L. Soung, et al., COVID-19 induces CNS cytokine expression and loss of hippocampal neurogenesis, *Brain* 145 (2022) 4193–4201, <https://doi.org/10.1093/brain/awac270>.
- [47] L.G. De Oliveira, et al., SARS-CoV-2 infection impacts carbon metabolism and depends on glutamine for replication in Syrian hamster astrocytes, *J. Neurochem* 163 (2022) 113–132, <https://doi.org/10.1111/jnc.15679>.
- [48] E.M. Rhea, A.F. Logsdon, K.M. Hansen, L.M. Williams, J. May, K.K. Baumann, S. J. Holden, J. Raber, W.A. Banks, M.A. Erickson, The S1 protein of SARS-CoV-2 crosses the blood–brain barrier in mice, *Nat. Med.* 24 (2022) 368–378, <https://doi.org/10.1038/s41593-020-00771-8>.
- [49] C.K. Yinda, et al., K18-hACE2 mice develop respiratory disease resembling severe COVID-19, *PLoS Pathog.* 17 (2021) 1–21, <https://doi.org/10.1371/journal.ppat.1009195>.
- [50] L. Jiao, et al., The olfactory route is a potential way for SARS-CoV-2 to invade the central nervous system of rhesus monkeys, *Signal Transduct. Target. Ther.* 6 (2021), <https://doi.org/10.1038/s41392-021-00591-7>.
- [51] M. Kishimoto-Urata, et al., Prolonged and extended impacts of SARS-CoV-2 on the olfactory neurocircuit, *Sci. Rep.* 12 (1) (2022) 13, <https://doi.org/10.1038/s41598-022-09731-7>.
- [52] A. Fernández-Castañeda, et al., Mild respiratory COVID can cause multi-lineage neural cell and myelin dysregulation, *Cell* 185 (2022) 2452–2468.e16, <https://doi.org/10.1016/j.cell.2022.06.008>.
- [53] J. Oh, W.H. Cho, E. Barcelon, K.H. Kim, J. Hong, S.J. Lee, SARS-CoV-2 spike protein induces cognitive deficit and anxiety-like behavior in mouse via non-cell autonomous hippocampal neuronal death, *Sci. Rep.* 12 (1) (2022) 10, <https://doi.org/10.1038/s41598-022-09410-7>.
- [54] M.G. Frank, et al., SARS-CoV-2 spike S1 subunit induces neuroinflammatory, microglial and behavioral sickness responses: Evidence of PAMP-like properties, *Brain Behav. Immun.* 100 (2022) 267–277, <https://doi.org/10.1016/j.bbi.2021.12.007>.
- [55] M.J. Page, et al., Updating guidance for reporting systematic reviews: development of the PRISMA 2020 statement, *J. Clin. Epidemiol.* 134 (2021) 103–112, <https://doi.org/10.1016/j.jclinepi.2021.02.003>.
- [56] Y. dong Gao, et al., Risk factors for severe and critically ill COVID-19 patients: A review, *Allergy Eur. J. Allergy Clin. Immunol.* 76 (2021) 428–455, <https://doi.org/10.1111/all.14657>.
- [57] J.-J. Zhang, X. Dong, G.-H. Liu, Y.-D. Gao, Risk and Protective Factors for COVID-19 Morbidity, Severity, and Mortality, *Clin. Rev. Allergy Immunol.* 64 (2023) 90–107, <https://doi.org/10.1007/s12016-022-08921-5>.
- [58] J.Y. Ko, et al., Risk factors for Coronavirus disease 2019 (COVID-19)-associated hospitalization: COVID-19-associated hospitalization surveillance network and behavioral risk factor surveillance system, *Clin. Infect. Dis.* 72 (2021) e695–e703, <https://doi.org/10.1093/cid/ciaa1419>.
- [59] G. Onder, G. Rezza, S. Brusaferro, Case-Fatality Rate and Characteristics of Patients Dying in Relation to COVID-19 in Italy, *JAMA* 323 (2020) 1775–1776, <https://doi.org/10.1001/jama.2020.4683>.

- [60] V. Prendki, et al., A systematic review assessing the under-representation of elderly adults in COVID-19 trials, *BMC Geriatr.* 20 (2020) 538, <https://doi.org/10.1186/s12877-020-01954-5>.
- [61] J.A. Hosp, et al., Cognitive impairment and altered cerebral glucose metabolism in the subacute stage of COVID-19, *Brain* 144 (2021) 1263–1276, <https://doi.org/10.1093/brain/awab009>.
- [62] S. Toniolo, et al., Dementia and COVID-19, a bidirectional liaison: Risk factors, biomarkers, and optimal health care, *J. Alzheimer's Dis.* 82 (2021) 883–898, <https://doi.org/10.3233/JAD-210335>.
- [63] A. Bianchetti, R. Rozzini, L. Bianchetti, F. Coccia, F. Guerini, M. Trabucchi, Dementia Clinical Care in Relation to COVID-19, *Curr. Treat. Options Neurol.* 24 (2022) 1–15, <https://doi.org/10.1007/s11940-022-00706-7>.
- [64] F. Bai, et al., Female gender is associated with long COVID syndrome: a prospective cohort study, *Clin. Microbiol. Infect.* 28 (2022) 611.e9–611.e16, <https://doi.org/10.1016/j.cmi.2021.11.002>.
- [65] G. Pelá, et al., Sex-related differences in long-COVID-19 syndrome, *J. Women's Health* 31 (2022) 620–630, <https://doi.org/10.1089/jwh.2021.0411>.
- [66] S.A. Rusticus, C.Y. Lovato, Impact of sample size and variability on the power and type I error rates of equivalence tests: a simulation study, *Pract. Assess. Res. Eval.* 19 (2019), <https://doi.org/10.7275/4s9m-4e81>.
- [67] P.G. Gibson, L. Qin, S.H. Puah, COVID-19 acute respiratory distress syndrome (ARDS): clinical features and differences from typical pre-COVID-19 ARDS, *Med. J. Aust.* 213 (2020) 54–56, <https://doi.org/10.5694/mja2.50674>.
- [68] M. Huang, et al., Pathophysiology of brain injury and neurological outcome in acute respiratory distress syndrome: a scoping review of preclinical to clinical studies, *Neurocrit. Care.* 35 (2021) 518–527, <https://doi.org/10.1007/s12028-021-01309-x>.
- [69] K.T. Thakur, et al., COVID-19 neuropathology at Columbia University Irving Medical Center/New York Presbyterian Hospital, *Brain* 144 (2021) 2696–2708, <https://doi.org/10.1093/brain/awab148>.
- [70] D. Lana, F. Ugolini, M.G. Giovannini, An overview on the differential interplay among neurons-astrocytes-microglia in CA1 and CA3 hippocampus in hypoxia/ischemia, *Front. Cell. Neurosci.* 14 (2020), 585833, <https://doi.org/10.3389/fncel.2020.585833>.
- [71] B. Long, B.M. Carius, S. Chavez, S.Y. Liang, W.J. Brady, A. Koymfman, M. Gottlieb, Clinical update on COVID-19 for the emergency clinician: Presentation and evaluation, *Am. J. Emerg. Med.* 54 (2022) 46–57, <https://doi.org/10.1016/j.ajem.2022.01.028>.
- [72] C. Chen, S.R. Hauptert, L. Zimmermann, X. Shi, L.G. Fritsche, B. Mukherjee, Global Prevalence of Post-Coronavirus Disease 2019 (COVID-19) Condition or Long COVID: A Meta-Analysis and Systematic Review, *J. Infect. Dis.* 226 (2022) 1593–1607, <https://doi.org/10.1093/infdis/jiac136>.
- [73] C.X. Sandler, et al., Long COVID and post-infective fatigue syndrome: a review, *ofab440*, *Open Forum Infect. Dis.* 8 (2021), <https://doi.org/10.1093/ofid/ofab440>.
- [74] H. Crook, S. Raza, J. Nowell, M. Young, P. Edison, Long covid - mechanisms, risk factors, and management, *BMJ* 374 (2021) 1–18, <https://doi.org/10.1136/bmj.n1648>.
- [75] J.A. Brownlow, K.E. Miller, P.R. Gehrman, Insomnia and cognitive performance, *Sleep. Med. Clin.* 15 (2020) 71–76, <https://doi.org/10.1016/j.jsmc.2019.10.002>.
- [76] C.N. Oyanel, S. Binder, E. Kelemen, K. Petersen, J. Born, M. Inostroza, Role of slow oscillatory activity and slow wave sleep in consolidation of episodic-like memory in rats, *Behav. Brain Res.* 275 (2014) 126–130, <https://doi.org/10.1016/j.bbr.2014.09.008>.
- [77] K. Dhama, et al., COVID-19 intranasal vaccines: current progress, advantages, prospects, and challenges, *Hum. Vaccin. Immunother.* 18 (2022), <https://doi.org/10.1080/21645515.2022.2045853>.
- [78] Q. Ye, G. Gast, X. Su, T. Saito, T.C. Saido, T.C. Holmes, X. Xu, Hippocampal neural circuit connectivity alterations in an Alzheimer's disease mouse model revealed by monosynaptic rabies virus tracing, *Neurobiol. Dis.* 172 (2022), 105820, <https://doi.org/10.1016/j.nbd.2022.105820>.
- [79] N. Samudra, et al., Alterations in hippocampal connectivity across the psychosis dimension, *Psychiatry Res* 233 (2015) 148–157, <https://doi.org/10.1016/j.psychres.2015.06.004>.
- [80] B. Tassignon, et al., Longitudinal changes in global structural brain connectivity and cognitive performance in former hospitalized COVID-19 survivors: an exploratory study, *Exp. Brain Res.* 241 (2023) 727–741, <https://doi.org/10.1007/s00221-023-06545-5>.
- [81] C. Zhao, J. Zhu, X. Liu, C. Pu, Y. Lai, L. Chen, X. Yu, N. Hong, Structural and functional brain abnormalities in schizophrenia: a cross-sectional study at different stages of the disease, *Prog. Neuropsychopharmacol. Biol. Psychiatry* 83 (2018) 27–32, <https://doi.org/10.1016/j.pnpbp.2017.12.017>.
- [82] L. Ji, et al., Characterizing functional regional homogeneity (ReHo) as a B-SNIP psychosis biomarker using traditional and machine learning approaches, *Schizophr. Res.* 215 (2020) 430–438, <https://doi.org/10.1016/j.schres.2019.07.015>.
- [83] X.-K. Li, H.-T. Qiu, J. Hu, Q.-H. Luo, Changes in the amplitude of low-frequency fluctuations in specific frequency bands in major depressive disorder after electroconvulsive therapy, *World J. Psychiatry* 12 (2022) 708–721, <https://doi.org/10.5498/wjp.v12.i5.708>.
- [84] L. Zhuang, et al., Aggregation of vascular risk factors modulates the amplitude of low-frequency fluctuation in mild cognitive impairment patients, *Front. Aging Neurosci.* 12 (2020), 604246, <https://doi.org/10.3389/fnagi.2020.604246>.
- [85] P. Vannini, et al., Hippocampal hypometabolism in older adults with memory complaints and increased amyloid burden, *Neurology* 88 (2017) 1759–1767, <https://doi.org/10.1212/WNL.0000000000003889>.
- [86] M.L. Carlson, et al., Simultaneous FDG-PET/MRI detects hippocampal subfield metabolic differences in AD/MCI, *Sci. Rep.* 10 (2020) 12064, <https://doi.org/10.1038/s41598-020-69065-0>.
- [87] A. Kas, et al., The cerebral network of COVID-19-related encephalopathy: a longitudinal voxel-based 18F-FDG-PET study, *Eur. J. Nucl. Med. Mol. Imaging* 48 (2021) 2543–2557, <https://doi.org/10.1007/s00259-020-05178-y>.
- [88] V. Chesnokova, R.N. Pechnick, K. Wawrowsky, Chronic peripheral inflammation, hippocampal neurogenesis, and behavior, *Brain Behav. Immun.* 58 (2016) 1–8, <https://doi.org/10.1016/j.bbi.2016.01.017>.
- [89] G. Vargas, L.H. Medeiros Geraldo, N. Gedeão Salomão, M. Viana Paes, F. Regina Souza Lima, F. Carvalho Alcantara Gomes, Severe acute respiratory syndrome coronavirus 2 (SARS-CoV-2) and glial cells: Insights and perspectives, *Brain Behav. Immun.* Health 7 (2020), 100127, <https://doi.org/10.1016/j.bbih.2020.100127>.
- [90] J. Matschke, et al., Neuropathology of patients with COVID-19 in Germany: a post-mortem case series, *Lancet Neurol.* 19 (11) (2020) 919–929, [https://doi.org/10.1016/S1474-4422\(20\)30308-2](https://doi.org/10.1016/S1474-4422(20)30308-2).
- [91] S.R. Stein, et al., SARS-CoV-2 infection and persistence in the human body and brain at autopsy, *Nature* 612 (7941) (2022) 758–763, <https://doi.org/10.1038/s41586-022-05542-y>.
- [92] M. Schwabenland, et al., Deep spatial profiling of human COVID-19 brains reveals neuroinflammation with distinct microanatomical microglia-T-cell interactions, *Immunity* 54 (7) (2021) 1594–1610, <https://doi.org/10.1016/j.immuni.2021.06.002>.
- [93] A. Emmi, et al., Detection of SARS-CoV-2 viral proteins and genomic sequences in human brainstem nuclei, *NPJ Park. Dis.* 9 (1) (2023), 25, <https://doi.org/10.1038/s41531-023-00467-3>.
- [94] Q. Ding, N.V. Shults, S.G. Gychka, B.T. Harris, Y.J. Suzuki, Protein expression of angiotensin-converting enzyme 2 (ACE2) is upregulated in brains with Alzheimer's disease, *Int. J. Mol. Sci.* 22 (2021) 1687, <https://doi.org/10.3390/ijms22041687>.
- [95] R. Najafloo, et al., Mechanism of anosmia caused by symptoms of COVID-19 and emerging treatments, *ACS Chem. Neurosci.* 12 (2021) 3795–3805, <https://doi.org/10.1021/acscchemneuro.1c00477>.
- [96] R.M. Patel, J.M. Pinto, Olfaction: anatomy, physiology, and disease, *Clin. Anat.* 27 (2014) 54–60, <https://doi.org/10.1002/ca.22338>.
- [97] J. Wingrove, et al., Aberrant olfactory network functional connectivity in people with olfactory dysfunction following COVID-19 infection: an exploratory, observational study, *EclinicalMedicine* 58 (2023), 101883, <https://doi.org/10.1016/j.eclinm.2023.101883>.
- [98] T. Llana, M. Mendez, C. Zorzo, C. Fidalgo, M.C. Juan, M. Mendez-Lopez, Anosmia in COVID-19 could be associated with long-term deficits in the consolidation of procedural and verbal declarative memories, *Front. Neurosci.* 16 (2022) 1–15, <https://doi.org/10.3389/fnins.2022.1082811>.
- [99] J.S. Biane, et al., Neural dynamics underlying associative learning in the dorsal and ventral hippocampus, *Nat. Neurosci.* 26 (2023) 798–809, <https://doi.org/10.1038/s41593-023-01296-6>.
- [100] A.C. Schapiro, A.G. Reid, A. Morgan, D.S. Manoach, M. Verfaellie, R. Stickgold, The hippocampus is necessary for the consolidation of a task that does not require the hippocampus for initial learning, *Hippocampus* 29 (2019) 1091–1100, <https://doi.org/10.1002/hipo.23101>.
- [101] A.A. Asadi-Pooya, et al., Long COVID syndrome-associated brain fog, *J. Med. Virol.* 94 (2022) 979–984, <https://doi.org/10.1002/jmv.27404>.
- [102] L. Crivelli, et al., Cognitive consequences of COVID-19: results of a cohort study from South America, *Arq. Neuropsiquiatr.* 80 (2022) 240–247, <https://doi.org/10.1590/0004-282X-ANP-2021-0320>.
- [103] M. Mendez, N. Arias, S. Uceda, J.L. Arias, C-Fos expression correlates with performance on novel object and novel place recognition tests, *Brain Res. Bull.* 117 (2015) 16–23, <https://doi.org/10.1016/j.brainresbull.2015.07.004>.
- [104] W.D. Taylor, et al., APOE ε4 associated with preserved executive function performance and maintenance of temporal and cingulate brain volumes in younger adults, *Brain Imaging Behav.* 11 (2017) 194–204, <https://doi.org/10.1007/s11682-016-9522-9>.
- [105] A. Arshamian, et al., The functional neuroanatomy of odor evoked autobiographical memories cued by odors and words, *Neuropsychologia* 51 (2013) 123–131, <https://doi.org/10.1016/j.neuropsychologia.2012.10.023>.
- [106] J. Talpos, M. Shoaib, Executive function, *Handb. Exp. Pharmacol.* 228 (2015) 191–215, [https://doi.org/10.1007/978-3-319-16522-6\\_6](https://doi.org/10.1007/978-3-319-16522-6_6).
- [107] M. Cascella, Y. Al Khalili, Short-term Memory Impairment., Treasure Island (FL): StatPearls Publishing, 2022.
- [108] L.R. Squire, L. Genzel, J.T. Wixted, R. Morris, Memory Consolidation. Cold Spring Harb, Lab. Press, 2015, pp. 1–21, <https://doi.org/10.1101/cshperspect.a021766>.