



Facultad de Veterinaria
Universidad Zaragoza



Trabajo Fin de Grado en Veterinaria

Cicatrización de heridas por segunda intención en équidos: revisión narrativa y estudio comparativo preliminar de dos técnicas.

Second intention wound healing in horses: narrative review and a preliminary comparative study of two techniques.

Autor/es

Marta María García de Castro Maceiras.

Director/es

Francisco José Vázquez Bringas (Universidad de Zaragoza)
Olivier Lepage (VetAgroSup, Lyon, Francia)

Facultad de Veterinaria

2023-2024

Index

1. Abstract	1
2. Introduction	2
3. Objectives and justification	3
4. Material and methods	3
4.1. Narrative bibliographic review	3
4.2. Descriptive study	4
5. Results and discussion	5
5.1. Narrative review	5
5.1.1. Phases of wound repair	5
5.1.2. Types of wound closure	7
5.1.3. Criteria to select the type of closure	7
5.1.4. Management of wounds by second intention healing	8
5.1.5. Main complications in healing	10
5.1.6. Current techniques for secondary intention healing	11
5.1.7. Calcium sulphate (CaSO₄)	20
5.1.8. Discussion of the narrative review	21
5.2. Descriptive study	21
5.3. General discussion	32
6. Conclusions	32
7. Personal assessment	33
8. Acknowledgements	34
9. References	34

Nota preliminar:

La propuesta inicial de este trabajo era llevar a cabo un estudio comparativo entre dos técnicas diferentes, pero debido a las causas citadas en el apartado de justificación y objetivos, no ha sido posible, por lo que lo que finalmente se ha planteado, además de una revisión bibliográfica narrativa, como un estudio descriptivo de una sola técnica, basada en uso del sulfato de calcio. Se consultó en plazo si a consecuencia de este cambio era obligatorio solicitar modificación en la propuesta de trabajo de fin de grado (TFG) pero no se consideró necesario.

Este TFG es un trabajo de modalidad D realizado en colaboración con la universidad de destino de un programa de movilidad Erasmus + en Lyon VetagroSup, Francia. Al tener un tutor en esta universidad francesa se consultó con la coordinadora del grado la posibilidad de realizar este trabajo en inglés para facilitar la comprensión al tutor francés.

Preliminary note:

The initial proposal of this work was to carry out a comparative study between two different techniques, but due to the causes mentioned in the justification and objectives section, it has not been possible and so it has finally been proposed, in addition to a narrative literature review, as a descriptive study of a single technique, based on the use of calcium sulphate. We consulted in due time whether as a result of this change it was compulsory to request a modification in the final year dissertation proposal, but it was not considered necessary.

This TFG is a modality D project carried out in collaboration with the host university of an Erasmus + mobility program in Lyon VetagroSup, France. As we had a tutor at this French university, we consulted with the degree coordinator about the possibility of carrying out this work in English to make it easier for the French tutor to understand.

1. Abstract

This work is divided in two different parts. On one hand, a narrative bibliographic review focus on wounds by second intention in the equine species, including the use of sulphate of calcium. On the other hand, since there's so little scientific literature of this technique and almost any studies, it has been done a small descriptive study of this technique, the sulphate of calcium.

This narrative literature review explored the treatment of wounds in horses treated by second intention healing. The aim of this first part is to understand the physiological process of wound healing and the practical implications for veterinary practice. This review synthesizes current knowledge on various aspects such as wound management, most common complications in this type of wound, most current treatments use nowadays and try to understand more the properties of sulphate of calcium and use of this biomaterial. After gathering all the information, a bast number of different techniques were found and it's concluded that no consensus has been made of which technique has the best results to treat wound by second intention healing.

The descriptive study investigated the use of plaster of Paris or calcium sulphate in the management of wounds treated by second intention healing in horses' limbs. This study aimed to evaluate healing rate, complications, and overall effectiveness in promoting wound closure and tissue regeneration of this technique. Results suggest that calcium sulphate or more known as plaster of Paris, contributes positively to wound healing in equine limb injuries, being very affordable and easy to use. Future research will be interesting to refine these findings have scientific evidence of the efficacy of this treatment for optimizing wound care in equine veterinary practice.

In conclusion, calcium sulfate shows promising results in promoting wound healing in horses treated by second intention healing, but further research is mandatory to establish its efficacy and conditions of use.

Resumen

Este trabajo se divide en dos partes distintas. Por un lado, una revisión bibliográfica narrativa centrada en las heridas tratadas con cicatrización por segunda intención en la especie equina, especialmente el uso de sulfato de calcio. Por otro lado, dada la escasez de literatura científica sobre esta técnica y la falta de estudios al respecto, se realiza un pequeño estudio descriptivo de esta técnica, el sulfato de calcio.

Esta revisión bibliográfica narrativa explora el tratamiento de heridas en caballos tratados mediante cicatrización por segunda intención. El objetivo de esta primera parte es comprender el proceso fisiológico de cicatrización de heridas y las implicaciones prácticas para la práctica veterinaria. La revisión recopila el conocimiento actual sobre varios aspectos como el manejo de heridas, las complicaciones más comunes en este tipo de heridas, los tratamientos más utilizados actualmente, y busca comprender mejor las propiedades del sulfato de calcio y el uso de este biomaterial. Tras recopilar toda la información, se encuentra una gran variedad de técnicas diferentes y se concluye que no existe un consenso sobre cuál técnica ofrece los mejores resultados para tratar heridas mediante cicatrización por segunda intención.

El estudio descriptivo investiga el uso de yeso de París o sulfato de calcio en el manejo de heridas tratadas mediante cicatrización por segunda intención en las extremidades de los caballos. Este estudio tuvo como objetivo evaluar la tasa de cicatrización, las complicaciones y la eficacia general para promover el cierre de heridas y la regeneración tisular con esta técnica. Los resultados sugieren que el sulfato de calcio, más conocido como yeso de París, contribuye positivamente a la cicatrización de heridas en lesiones en las extremidades de los equinos, siendo muy económico y fácil de usar. Sería interesante realizar futuras investigaciones para confirmar estos hallazgos y obtener evidencia científica sobre la eficacia de este tratamiento para optimizar el cuidado de heridas en la práctica veterinaria equina.

En conclusión, el sulfato de calcio muestra resultados prometedores en el tratamiento de heridas en caballos tratados mediante cicatrización por segunda intención, pero se necesita más investigación para establecer con suficiente evidencia su grado de eficacia y sus recomendaciones de uso.

2. Introduction

Wounds in horses are one of the main issues that we can face as an equine practitioner. Very often, these wounds will be treated by secondary intention, for many reasons such as: lack of tissue to approximate edges, an area in continuous movement, contamination of the wound or a long time having passed from the time the wound occurred until it was attended by a veterinarian (Theoret, 2008; Young and McNaught, 2011).

Something to keep in mind is that horses are the domestic species that has the most problems healing wounds, even worse than donkeys or even ponies. The dehiscence of the suture is very common and if the wound is in the extremities is even more complicated because of the poor vascularization, being close to bones, tendons and articulation that will not allow the immobilization of the extremity so it will be difficult to preserve the granulation tissue. The tendency to form keloids, that are thick and irregular scar tissue (Elce, 2016).

The first thing we must know and understand to address this topic is the physiological processes that occur during the healing process, to be able to adapt the treatment to each phase of the wound healing process. On the other hand, it is necessary to know the types of closure possible, the actual treatments that we can use for the management of a wound and the possible

complications that we might encounter. Conversely, currently there's so many different techniques to manage a second healing intention wound but no consensus has been reached of which treatments is the most efficient. A very promising technique that has been used by equine practitioners that have a very good result but there's no scientific evidence or studies nowadays is the sulphate of calcium or plaster of Paris (Rivera, 2023).

3. Objectives and justification

This work is divided in two distinct parts and therefore two different objectives. Firstly, with the narrative literature review we will try to understand more the mechanism of healing in the limbs of equids and their current treatments and possible complications that we can encounter when treating a wound. Furthermore, it is known that wounds on the body of equids heal much more easily than on the extremities. This difficulty of healing in wounds on the limbs of equids has been the subject of study by veterinarians for several years. Some authors claim that one of the causes of poor healing is due to a slower inflammatory response in the extremities than in the body (Haspeslagh *et al.*, 2021).

Initially, in the TFG proposal, the second objective was, taking advantage of the Erasmus stay in another university and the possibility of seeing several clinical cases during the stay, to carry out a small preliminary comparative study between the most common used technique in each of the two universities to treat the same problem, in this case wounds treated with healing by second intention. This was finally changed to a descriptive study of one of the techniques, the calcium sulphate or plaster of Paris, due to the lack of sufficient cases that met the inclusion criteria in the study during my training days at the destination University. This descriptive study aims to evaluate the outcomes of eight equine cases treated with calcium sulfate for limb wounds. By closely examining these cases, we seek to understand the potential efficacy, benefits, and limitations of calcium sulfate as a treatment modality for equine limb wounds.

This study has a special interest because there's not much scientific literature or evidence of the efficacy of this biomaterial that every year is more and more use by equine practitioners. This biomaterial is very affordable, easy to use and with good empiric outcomes according to the equine practitioners that use this technique, which are three of the main criteria to select a treatment in equine medicine. This study pretends to show some cases, that had a very good outcome to motivate future research about this technique and motivate other veterinarians to use this biomaterial.

4. Material and methods

4.1. Narrative bibliographic review

For the first part of the work, that is a narrative bibliographic review, books from recognized editorials and focused or including equine wound management were used, in addition to scientific articles from relevant databases including PubMed, Web of Science, Google Scholar, Scopus, and veterinary-specific databases like CAB Abstracts and the Veterinary Information Network (VIN). A filter was initially adjusted so that articles from the last 30 years to the present appeared to obtain the most recent and up-to-date information. But since there is limited information on the subject, no specific publication dates for articles were restricted to ensure a greater number of available publications also, given the potentially limited information available on calcium sulfate in wounds in equine species, the search has been expanded to other species. Only information that has become outdated due to subsequent scientific advancements has been excluded. Three languages were added to the filter to maximize the amount of information: French, English, and Spanish.

To search information a Boolean combination of keywords was used, such as: “second-intention healing,” “equine,” “wound management,” “secondary wound closure,” and “limb”, and “calcium sulphate”.

With the aim of organizing the bibliographic references found on the topic, the assistance of a reference manager (RefWorks) has been utilized. The sixth edition of the American Psychological Association (APA, 2018) format has been employed to indicate the citations and bibliographic references.

4.2. Descriptive study

For the second part of this work, the preliminary case comparison study, for the reasons previously mentioned, was decided to be changed for a descriptive study of the sulphate of calcium dressing technique. This modification in the focus of the work was communicated to the Degree Coordinator, who gave her approval, without considering it necessary to request modifications from the responsible Faculty Committee.

Cases treated at the Equine Surgery and Medicine Service of the HVUZ, by referring equine practitioners from the HVUZ or by others Spanish veterinarians (working in Spain or in France) were included. The information of the cases was collected directly from the HVUZ's medical records and multimedia archives or from the veterinarian that treated the case, by phone or WhatsApp contact. For the selection of cases, it is intended that the horses have a similar situation and without complications that can affect healing, so the following inclusion criteria were established:

- Wound in the extremities.
- Do not suffer from other concomitant diseases.
- Adequate wound monitoring and clinical documentation
- The wound has been treated by second intention with sulphate of calcium

A descriptive statistic was performed. In this descriptive study, two types of variables were distinguished, qualitative and quantitative. The qualitative variables used in this study were: sex of the horse, breed of the horse, location of the wound, use of NSAID's, use of antibiotics, complications, bone exposure and need of surgery. These will be analyzed using frequencies and percentages, employing tables to visualize category distributions.

Quantitative variables that were included in this study: were age of the horse, frequency of bandage changes, total healing time and approximate cost of the treatment. To calculate the treatment costs, a table with the same prices for each type of treatment was used. Travel and hospitalization expenses were excluded; therefore, the only costs included in the treatment expenses were the veterinary medical act costs, to exclude costs exclusively resulting from the case being treated at home (travel) or in hospital (hospitalisation). A histogram with the data was performed in Excel to determine the distribution of these data. The lack of the characteristic bell-shaped curve showed that the data didn't presented a normal distribution. Since the data doesn't follow a normal distribution, these variables were analyzed using descriptive statistics such as medians and interquartile range (IQR). If the data followed a normal distribution, the mean, standard deviation were calculated. Range between minimum and maximum were calculated for all quantitative variables.

To analyze this information an Excel document and Python application were used to synthetize the information of the variables previously mentioned, create the representations in form of tables and calculate the descriptive statistical parameters.

5. Results and discussion

5.1. Narrative review

5.1.1. Phases of wound repair

The objective of healing is to re-establish an epithelial cover and recover the integrity of the tissue, the strength and function of the lost tissue (Young and McNaught, 2011). Depending of the type of wound we will have different processes (Hanson, 2008). In this narrative review we will focus on full-thickness cutaneous wounds.

The main phases of wound repair are: Acute inflammatory phase, proliferative phase, and remodeling phase (Caston, 2012) (Figure 1).

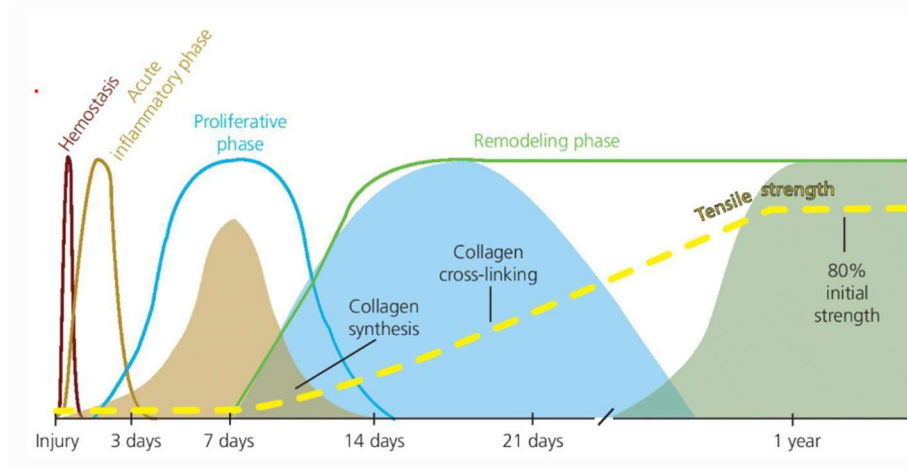


Figure 1: Phases of wound healing. Source: Theoret,C. (2017). *Physiology of wound healing, Chapter 1*. Veterian Key. From : <https://veteriankey.com/1-physiology-of-wound-healing/>.

The acute inflammatory phase takes place since the injury happens until the first three days. During this phase we have two different responses (Theoret, 2005). A vascular response in which the cell membrane release phospholipids that will be transformed into arachidonic acid that will mediate vascular tone and permeability as well as platelet aggregation (Subramaniam, 2021). The first thing that should happen is the formation of a clot from the coagulated blood and aggregated platelets (Seid and Birhan, 2019). This clot will prevent the bleeding of the wound and provide a provisional extracellular matrix that will be replaced by granulation tissue in the phase of repair (Stashak, 2008). The other response that we have in this phase is the cellular response. Leukocytes are chemoattracted to the site of injury. The first line of defense in contaminated wounds are the neutrophils (Seid and Birhan, 2019). They will phagocyte the possible bacteria that will penetrate in the site of injury and be a source of pro-inflammatory cytokines essential in infected wounds (Theoret, 2005). Once the contaminating particles are cleared the neutrophil migration and phagocytosis will decrease (Maher and Kuebelbeck, 2018).

Inflammatory conditions will produce a rapid increase of macrophages caused by the emigration of monocytes from the blood vessels (Caston, 2012). These pluripotent monocytes can evolve into macrophages that depending on the conditions that they will encounter they will have different functional properties (Hanson, 2008). Macrophages will also help in the debridement of the site of injury acting as a microbial killing by phagocytosis and promote angiogenesis for the new tissue (Wilmink and van Weeren, 2004). Macrophages play a key role in the reparative phase of healing. The adherence to Extra-Cellular Matrix (ECM) will stimulate the transformation of monocytes into a phenotype that will provide the cytokines necessary for the correct development of the new tissue in the wound (Theoret, 2005). Once this population of cells are not needed anymore, they will be eliminated by apoptosis or programmed cell death. The

inflammatory cells that were necessary for the repair of the wound will be eliminated by apoptosis and the number of mesenchymal cells will increase to deposit new matrices and mature the wound (Stashak, 2008).

The proliferative phase takes place from the second day to the two weeks post-injury. During this phase a red, fleshy granulation tissue will appear filling the defect site (Caston, 2012). Granulation tissue is mainly formed by three elements: macrophages, fibroblasts and new blood vessels (Wilmink and van Weeren, 2004). Macrophages will stimulate angiogenesis and fibroplasty, due to the cytokines and growth factors that they are able to produce (Maher and Kuebelbeck, 2018). Fibroblasts are in charge of synthesize the new ECM components and lastly the new vascularization will provide oxygen and necessary nutrients for the correct development of the mesenchymal cells (Theoret, 2005). This stroma will provide the site of injury a barrier to contamination from the outside to prevent the infection of the wound and a surface for the mesenchymal cells to migrate (Subramaniam, 2021).

Fibroblast production from adjacent uninjured adjacent tissues will be stimulated by inflammatory cells. This fibroblast will migrate to the wound space to replace de provisional matrix by a collagen – rich one (Stashak, 2008).

The period of the most rapid gain in tensile strength occurs seven to fourteen days after the injury, coinciding with the period of most connective tissue accumulation. After this time, collagen level stays stable, and fibroblast start to decrease their activity corresponding with a slower gain in wound strength during the remodeling of the wound (Caston, 2012). The granulation tissue rich in fibroblast is afterwards replaced by an avascular and acellular scar while the number of capillary decreases, fibroblasts go in apoptosis or acquire a muscle consistency and will later help in wound contraction (Theoret, 2005). If the signal to decrease the activity of fibroblast is delayed in a specific time frame, the degradation and synthesis of collagen will be imbalanced leading to formation of excessive scar tissue (Maher and Kuebelbeck, 2018).

Epithelialization is a natural process of covering the defect with epithelium (Seid and Birhan, 2019). This epithelium is the first line of defense from possible environment contamination and in charge of maintaining internal homeostasis by limiting fluid and electrolyte loss (Subramaniam, 2021). Epithelial migration starts from the wound margin 24 to 48 hours post-injury but it's not until the fourth to sixth day that we can see it macroscopically (Stashak, 2008).

The last phase known as matrix synthesis and remodeling. During this phase the process of contraction of the wound will start, both dermis and epidermis surrounding the injury site will be drawn centripetally over the exposed wound bed (Theoret, 2005). The skin surrounding the wound will stretch by an intussusceptive growth and the wound gets a stellate appearance. During this phase most authorities agree that myofibroblast, that are a specialized fibroblast phenotype, are the most prevalent type of cells in healthy granulation tissue and are aligned along the lines of contraction (Subramaniam, 2021). The most important feature of this type of cells is the well- developed alpha smooth muscle actin (α -SMA) micro filamentous system. The number of this myofibroblast appears proportional to the need for contraction of the wound. To sum up, the more the repair of the wound progresses the least number of fibroblasts we will find (Maher and Kuebelbeck, 2018).

Wound contraction is divided in three phases. A lag phase in which the skin edges retract prior to the fibroblastic invasion into the wound that will be necessary for the contraction. Subsequently a phase of rapid contraction followed by a slow contraction phase as the wound edges start to approach completely until complete closure (Stashak, 2008).

Contraction will decreased in response to three different events wound edges get in contact and both epithelialization and contraction ceases, tension of the surrounding becomes similar or greater that the contractile force generate by the smooth muscle actin of the myofibroblasts,

and lastly , in chronic wounds a failure of wound contraction due to a low number of myofibroblast in the granulation tissue, in this situation the granulation tissue consists primarily of collagen and it's really pale (Stashak, 2008; Maher and Kuebelbeck, 2018).

The last phase of wound repair in the maturation. This phase consists of converting ECM from granulating tissue to scar tissue by synthesis, lysis and remodeling connective tissue (Stashak, 2008).

5.1.2. Types of wound closure

The types of closure that exist to resolve a wound are closure by first intention, delayed closure by first intention or closure by secondary intention.

Closure by first intention consists of directly approximating the edges with a suture. To do this, the wound must be recent, not infected, or contaminated, and the edges must be brought together without generating excessive tension on the tissue (Ferrer, 2019).

Delayed closure by first intention consists of approximating the edges as much as possible using a suture, but without completely approximating the edges (Ferrer, 2019). This technique is usually performed on wounds that are not so recent and there is already some granulation tissue meaning that the proliferation phase has already begun, or it is too inflamed to be able to perform a suture. These are usually wounds with a high degree of contamination, so the degree of contamination and inflammation must be reduced before the suture can be done. To sum up, they are wounds that are not suitable to be closed directly by first intention. The objective of using this technique is to reduce the time necessary to close the wound and obtain a better aesthetic result (Hendrickson, 2004).

Closure by secondary intention consists of letting the wound continue its natural healing process without the need for suturing (Bertone, 1989). The main objective is to avoid contamination of the wound and provide adequate conditions so that the different physiological phases of healing can occur (Hanson, 2008).

Some authors also talk about wounds that have « no intention » of healing like fistulas, keloids or EGT (exuberant granulating tissue) that probably will need cutaneous grafts.

5.1.3. Criteria to select the type of closure

The best approach to manage a wound should not be dictated by strict rules about timing or conditions. Instead, it should be guided by a thorough assessment of the wound and consideration of patient-specific factors. Since each wound is unique, it requires personalized care (Elce, 2016).

Most of the time wounds that are sutured have a complete or partial dehiscence. Indeed, a retrospective study of more than 500 horses with accidental skin wounds showed that primary closure was successful in only 26% of the horses and 41% of the ponies in which it was attempted. Which leads to the practitioners to use most of the times the second intention healing (Elce, 2016).

To choose the type of closure more adequate for each wound we have different criteria, among which the more important are:

- Contamination
- Localization of the wound
- Tissue lost.
- Time passed since injury.

The criteria to use a first intention healing are (Kamus and Theoret, 2018).

- The wound is in an area where suturing is practical and won't be subjected to excessive movement or stress.
- The wound has a minimal risk of infection or can be effectively cleaned and debrided.
- The area has an adequate blood supply to promote healing.
- The wound edges can be approximated without excessive tension.
- The wound is free from contamination and debris.

The criteria to use a second intention healing are (Kamus and Theoret, 2018).

- The wound is contaminated with dirt, bacteria, or other debris, making primary closure risky.
- There is significant tissue loss, and the wound edges cannot be easily approximated.
- The area has a compromised blood supply, which could hinder healing if closed surgically.
- The wound is older and has already begun to heal by granulation.
- The wound is in an area subjected to significant movement or stress, making primary closure impractical.
- Areas like the lower limbs where motion is constant, and sutures are likely to fail because of the constant movement.

5.1.4. Management of wounds by second intention healing

Managing a wound healing by secondary intention in horses involves several key steps to ensure proper healing and prevent complications. The main steps that we should follow when facing a wound are: wound cleaning, exploration and debridement (Eggleston, 2018).

i. Wound cleaning and exploration

Wound cleaning and exploration are critical. Cross-contamination should be avoided, and strict aseptic techniques are necessary for open synovial structures. Various substances are used for wound cleaning, but they can cause chemical or mechanical trauma to the wound bed. The practitioner must balance the benefits of a clean wound with the potential trauma caused by the cleaning agents. As Joseph Lister said: *"Don't do to a wound what you wouldn't do to your own eye."* (Dean A. Hendrickson, 2004, p.30).

Scrubbing devices like woven gauze enhance wound cleansing but also cause mechanical trauma. Irrigation force is crucial, with higher pressures reducing bacterial numbers but causing more tissue trauma. Fluid pressure should not exceed 15 psi to minimize dispersion, and different devices can achieve varying pressures like a 50 mL syringe with a pink needle breaking the end. Normal saline is effective for cleaning mildly contaminated wounds, while tap water can be used for grossly contaminated wounds (Freeman *et al.*, 2021). The BEVA guidelines for evidence-based medicine on equine wound healing pointed out that in antiseptic agents like povidone-iodine and chlorhexidine are used for reducing bacterial numbers but should be reserved for peri-wound tissues due to their cytotoxicity. Topical antibiotics are effective in reducing bacterial numbers in human burn patients, and silver in various formulations has been commonly used, especially in burn care. However, adequate debridement is more critical than antimicrobial therapy in wound healing (Freeman *et al.*, 2021).

ii. Debridement

Wound debridement focuses on removing devitalized tissue, bacteria, contaminants, or foreign bodies from wounds. The presence of these elements can hinder healing and prevent the body from combating infections effectively (Maher and Kuebelbeck, 2018).

Wound debridement is one of the quickest and most effective methods to reduce bacterial contamination. However, all debridement types have both positive and negative impacts on the

wound bed and healing process. The best debridement method is one where the benefits outweigh the drawbacks for the specific wound (Freeman *et al.*, 2021).

Debridement methods are categorized into three main types: mechanical, chemical, and natural (Seid and Birhan, 2019). Each of these categories has further subcategories:

- **Mechanical Debridement:** involves physical contact with the wound using instruments or products not typically found in the wound. Common methods include sharp and physical debridement. Devices such as Versajet, which utilizes a high-pressure jet of saline solution to precisely and effectively debride wounds, minimizing damage to surrounding healthy tissue and promoting faster recovery (Shimada *et al.*, 2021).
 - Sharp Debridement: Utilizes cutting instruments like scalpels, scissors, or lasers to remove devitalized tissue. It is the least traumatic mechanical method and requires careful assessment of tissue viability to avoid excessive tissue removal (Chhabra *et al.* 2017).
 - Physical Debridement: Removes devitalized tissue through physical forces other than cutting, often using woven gauze. Techniques include "wet-to-dry" or "dry-to-dry" dressings and hydrotherapy. This method is cost-effective but can be traumatic and is best for small quantities of devitalized tissue (Freeman *et al.*, 2021).
- **Chemical Debridement:** such as Dakin's solution, which is a diluted solution of sodium hypochlorite, commonly known as bleach, combined with baking soda (sodium bicarbonate) to reduce its irritant properties (Leise, 2018). In this category we can find also the hypertonic saline dressings. However, they often cause significant trauma to the wound bed, limiting their use. Hypertonic saline dressings are effective for infected or heavily exuding wounds by desiccating necrotic tissue and bacteria through osmotic action (Freeman *et al.*, 2021). Acid Replacement Solution-1050 (ARS-1050) is promising for chemical debridement of infected wounds (Auer and Stick, 2012).
- **Natural Debridement** Natural methods utilize the body's own processes and substances for debridement.
 - Autolytic Debridement: Uses semi-occlusive or occlusive dressings to keep wound fluid in contact with the wound bed, allowing the body's enzymes to soften and remove necrotic tissue. This method is very selective and painless, though it requires patience and is not suitable for heavily infected wounds (Freeman *et al.*, 2021).
 - Enzymatic Debridement: Involves applying specific enzymes to the wound, which selectively liquefy necrotic tissue for easy removal while leaving healthy tissue intact. This method is effective for large wounds with moderate necrotic debris but can be costly (Jacobsen, 2016).
- **Biological Debridement:** biological methods make use of living organisms, such as larvae, to debride wounds.
 - Larval Debridement (Maggot Therapy): Involves the application of sterile larvae of the greenbottle fly to the wound. These larvae consume necrotic tissue and bacteria, promoting healing by releasing enzymes that liquefy dead tissue and disinfect the wound (Jacobsen, 2016). Larval debridement is highly selective, sparing healthy tissue, and can be particularly useful for wounds with extensive necrosis or infection. It also helps in reducing bacterial load and stimulating granulation tissue formation (Seid and Birhan, 2019).

5.1.5. Main complications in healing

1. Exuberant granulating tissue (EGT)

"Exuberant granulating tissue" refers to an excessive formation of granulation tissue, which is a part of the normal wound healing process (Maher and Kuebelbeck, 2018). Granulation tissue consists of new blood vessels, fibroblasts, and inflammatory cells that form at the site of a wound during the proliferative phase of healing. However, when this tissue grows excessively, it can impede wound closure and lead to complications (Hirshberg *et al.*, 1998).

Exuberant granulating tissue typically presents as bright red, beefy-looking tissue that protrudes above the surface of the wound (Anantama *et al.*, 2022). It can be associated with chronic wounds, such as pressure ulcers, diabetic ulcers, or venous ulcers, where the normal healing process is disrupted (Theoret and Wilmink, 2016). Treatment strategies may include "aggressive debridement, topical agents to promote epithelialization, or surgical intervention" (Hirshberg *et al.*, 1998).

If the healing is delayed due to excessive granulation tissue or impaired epithelialization, other complications such as keloids. This is characterized by the fibrosis under the surrounding skin of the wound and the scar produced can lead to the formation of an unattractive, hypertrophic scar and accumulation of fibrous tissue at the site of the wound (Bertone, 1989).

2. Biofilms

Bacterial biofilms are structured communities of bacteria on surfaces, enveloped in a three-dimensional extracellular matrix, significantly impacting wound healing and infection management (Jørgensen *et al.*, 2017). Chronic wounds, characterized by delayed or interrupted healing, are often indicative of biofilm infection if other underlying conditions are excluded. Biofilms are resilient to antibiotics and immune responses, complicating treatment (Nesse, 2023). Biofilms are prevalent in both human and equine nonhealing wounds, necessitating advanced training in wound care and targeted treatments to manage these persistent infections effectively (Marchant *et al.*, 2024).

3. Infection

Wound infections refer to the invasion and multiplication of microorganisms within a wound, leading to local and systemic inflammatory responses that can impair the healing process (Dart *et al.*, 2016). Wound infections are typically characterized by the five cardinal signs of inflammation, such as redness, swelling, warmth, pain and loss of function at the site of the wound. Additionally, there may be purulent discharge, delayed wound healing, and systemic symptoms such as fever and discomfort (Dart *et al.*, 2016). Wound infections can significantly impact patient outcomes, prolong hospital stays, increase healthcare costs, and in severe cases, lead to sepsis and death (Orsini *et al.*, 2016).

Clinical signs of wound infection can include cellulitis, erythema, swelling, and increased local temperature. Covert infections might show less obvious signs, such as loss or changes in granulation tissue. Quantitative bacteriology measures the bacterial load, with loads above 10^5 organisms per gram of tissue negatively affecting healing. The presence of foreign materials can reduce the necessary bacterial load for infection to 10^4 organisms per gram of tissue (Theoret, 2016).

4. Bone sequestration

Bone sequestration refers to the process in which a fragment of devitalized bone becomes separated from the surrounding healthy bone due to injury, infection, or other pathological conditions. This fragment, known as a sequestrum, lacks a blood supply and may act as a nidus for persistent infection or chronic inflammation (Hanson, 2008). Treatment of bone sequestration typically involves surgical debridement to remove the necrotic bone fragment,

along with antimicrobial therapy to address any underlying infection. In some cases, additional procedures such as bone grafting may be necessary to promote bone healing and reconstruction and avoid further problems such as osteomyelitis (Lew and Waldvogel, 2004).

5. Chronic wounds

Chronic wounds are persistent, non-healing wounds that fail to progress through the normal phases of wound healing, often due to underlying systemic or local factors (Theoret, 2004). Chronic wounds are characterized by a prolonged inflammatory phase, impaired tissue regeneration, and persistent infection or inflammation (Maher and Kuebelbeck, 2018). These wounds often show clinic signs such as delayed wound healing, excessive exudate, and necrotic tissue formation (Theoret, 2004). Treatment strategies for chronic wounds typically involve addressing underlying factors contributing to impaired healing, such as infection, ischemia, and metabolic abnormalities. This may include wound debridement, optimization of wound bed preparation, use of advanced wound care products, and adjunctive therapies such as negative pressure wound therapy or bioengineered skin substitutes (Maher and Kuebelbeck, 2018).

5.1.6. Current techniques for secondary intention healing

5.1.6.1. Dressings

The ideal wound dressing should maintain a moist environment and allow for adequate gas exchange at the wound surface, promoting the healing process in each phase. It should protect the wound from infection by acting as a bacterial barrier. Additionally, the dressing should eliminate dead space, allow removal of excess exudate, be easy to apply, and be nonantigenic (Gomez and Hanson, 2005). Dressings can be classified depending on 3 different characteristics of the dressing:

1. According to the composition of the dressing we can find synthetic, semisynthetic or biological.

Synthetic dressings are made from man-made fabrics or plastic materials among which we found: gauze, films, sprays, foams, and gels. Semisynthetic dressings combine synthetic and biological products. Biologic dressings are derived from natural sources and include amnion, allografts, and xenografts, as well as bioengineered tissues composed of various proteins or wound-healing cells (May, 1991).

2. According to the ability to adhere to the wound we can find non-adherent or adherent dressing.

Non-adherent and gauze dressings are commonly used, allowing fluid transfer and aiding in wound healing. However, maintaining a moist wound-healing environment with gauze dressings can be challenging, often requiring frequent remoistening. While non-adherent dressings like Telfa™ pads have been traditionally favored for their ease of application, newer dressings designed for specific wound-healing stages may offer improved outcomes (May, 1991).

3. According to the ability to allow the passage of exudates and vapors we can find occlusive, semi occlusive, or non-occlusive dressings.

Occlusive dressings, which isolate the wound and offer benefits such as rapid debridement and decreased healing time, are becoming more popular despite concerns about infection. Studies have shown that occlusive dressings do not necessarily increase infection rates (May, 1991).

A synthetic, nonocclusive, or semi-occlusive primary layer is commonly used for equine wounds. While occlusive dressings are beneficial initially for promoting granulation tissue, they can delay

healing. Silicone dressings, though, have shown promise in preventing excessive granulation tissue and improving tissue quality (Eggleston, 2018).

- **Hypertonic saline dressings**

Hypertonic saline dressings are specifically formulated for necrotic or heavily exuding wounds, working through osmotic action to desiccate necrotic tissue and bacteria (Farstvedt *et al.*, 2004). However, their non-selective debridement requires careful monitoring to prevent damage to surrounding tissue. These dressings should be changed every 24 to 48 hours initially, with frequency adjusted based on exudate levels. Curasalt™, a loosely woven gauze dressing premoistened with 20% hypertonic saline, is preferred for its effectiveness in removing necrotic tissue and reducing bacterial load compared to lower concentrations. Once necrotic tissue is removed and bacterial infection is controlled, transitioning to another dressing type such as calcium alginate or semi-occlusive foam is recommended (Hendrickson, 2004).

- **Non-Adherent Cotton (NAC)**

NAC (Gamage™) offers protection, support, and insulation. Ideal for highly exudative limb wounds in the inflammatory phase (Stashak *et al.*, 2004).

- **Hydrophilic Dressings**

These include Particulate Dextranomers (PDs), Maltodextrin (MD), Calcium Alginate (CA), Freeze-Dried Gel (FDG), and Chitin (C). They aid in wound healing, debridement, and tissue regeneration. Best used based on wound type and healing phase (Auer and Stick, 2012).

Calcium alginates

Calcium alginate dressings, made from sodium and calcium alginate derived from seaweed, offer a soft, non-woven fabric composition. The calcium within the dressing interacts with sodium in the wound, promoting wound exudate that accelerates myofibroblast and epithelial cell activity, facilitating wound healing. These dressings are suitable for moderately to heavily draining wounds, absorbing up to 20 times their weight in exudate and reducing the need for frequent bandage changes (Subramaniam, 2021). They conform to wound contours, are easy to apply, and are painlessly removed intact. Additionally, they exhibit good vertical wicking properties, minimizing maceration of healthy peri-wound tissue (Auer and Stick, 2012; Subramaniam, 2021).

Available in pads or ropes for loose packing, these dressings can be trimmed to size and are highly conformable. Newer versions include zinc-embedded varieties (Curasorb Zn™), which support epithelialization. Calcium alginate dressings are associated with reduced pain during changes and are typically used after wound debridement and cleaning, or when pre-moistened with gel to stimulate granulation tissue. They may be pre-moistened with saline for wounds requiring granulation tissue stimulation but lacking excess exudate. Dressing changes are recommended every 3 to 7 days, depending on exudate levels (Gomez and Hanson, 2005).

- **Maltodextrins**

Maltodextrins, derived from plant starches, have exhibited bacteriostatic properties against bacteria like *Pseudomonas aeruginosa* and *Staphylococcus aureus*. Additionally, they provide glucose as nutrition to wound healing cells (Caston, 2012). In horse studies, maltodextrins showed better tissue healing outcomes compared to nitrofurazone. They are available as powders and gels, maltodextrins are best utilized during the granulating stage of wound healing, followed by the use of a semi-occlusive foam dressings once adequate granulation tissue is established (Hendrickson, 2004).

- **Occlusive Synthetic Dressings (OSDs)**

Occlusive Synthetic Dressings (OSDs) are nonporous materials designed to promote "moist wound healing" by retaining low moisture/vapor transmission (Gomez and Hanson, 2005). They

create an optimal environment for wound healing by facilitating autolytic debridement, which selectively removes necrotic tissue, and by stimulating fibroplasia and epithelialization through growth factors and cytokines present in the moist wound. Benefits of moist wound healing include preventing scab formation, improving oxygenation, preventing bacterial strike-through, enhancing epithelialization, and augmenting bacterial colonization without increasing infection rates (Auer and Stick, 2012).

- Hydrogels (HGs)

Hydrogel dressings, composed of water, glycerin, and polymer, foster a moist wound-healing environment, ideal for dry wounds. They come in various forms, such as amorphous gel or gel-impregnated gauze, and are completely occlusive. By moistening scabs, they facilitate wound debridement and promote improved healing processes like autolytic debridement and white blood cell migration (Gomez and Hanson, 2005). Typically used in dry wounds, they offer relief in painful wounds and require changing every 4 to 7 days based on exudate levels. Once the wound becomes moist, other semi-occlusive dressings are favored over hydrogels (Hendrickson, 2004). They are particularly useful for shallow, flat wounds and can be used to deliver topical medications (Auer and Stick, 2012).

- Hydrocolloid (HC) Dressings

HC dressings have an adhesive layer, an absorbing hydrocolloid mass, and a protective outer film. They are effective in promoting granulation tissue formation and epithelialization, although their use should be limited to the early inflammatory phase of wound healing to prevent exuberant granulation tissue (Stashak *et al.*, 2004).

- Silicone Dressings

Silicone gel sheet dressings, like CicaCare[®], are used to prevent hypertrophic scarring by exerting pressure on the microvasculature and altering growth factor levels. They are effective during the repair and remodeling phases of healing (Auer and Stick, 2012).

- **Semi-Occlusive Synthetic Dressings (SCSDs)**

SCSDs include a variety of fabric-based dressings and newer polyurethane sheets or foams. They are useful in different wound healing stages, with some being more effective during early granulation and others promoting epithelialization in later stages. Studies indicate that dressings like Telfa[®] promote faster healing compared to occlusive dressings like Biodres[®], which may prolong healing and increase the need for trimming granulation tissue (Auer and Stick, 2012).

SCSDs are modern dressings that create a moist environment for wound healing while allowing some gas exchange. They come in various forms like polyurethane sheets or foam.

- Fabric Synthetic Dressings (FSDs)

FSDs include petrolatum-impregnated gauze (e.g., Vaseline Petrolatum Gauze[®]), petrolatum emulsion dressings (e.g., Adaptic[®]), rayon/polyethylene fabrics, and others. Studies indicate that wounds with petrolatum dressings show more contraction initially but less epithelialization over time compared to other dressings like cotton non-adherent film (CNF). Petrolatum dressings initially promote wound contraction but slow epithelialization. These are recommended in early wound healing, especially for wounds free of necrotic tissue (Auer and Stick, 2012).

Polyurethane Semi-Occlusive Dressings (PUS)

Available as sheets (e.g., Op-Site[®], Tegaderm[®]) or foam (e.g., Hydrosorb[®]), these dressings are waterproof, allow vapor transmission, and create a moist environment conducive to healing. They protect against bacterial infections but can sometimes strip newly formed skin during removal (Auer and Stick, 2012). Polyurethane dressings create a moist environment that accelerates healing phases but require monitoring for excess fluid accumulation. These are used

throughout the healing period for clean wounds, especially during the repair phase (Gomez and Hanson, 2005).

- Foam dressings

Foam dressings are semi-occlusive and are suitable for mildly exudative wounds. They are typically applied after healthy granulation tissue has developed and after removal of gross necrotic tissue and infection (Ferrer, 2019). These dressings help maintain a moist wound environment and provide a consistent thermal environment, thereby promoting epithelialization and reducing granulation tissue formation. If excessive granulation tissue is present, it should be trimmed before applying the dressing. Foam dressings can be changed every 4 to 7 days, depending on the level of exudate (Hendrickson, 2004).

- **Antimicrobial Dressings**

Anti-microbial dressings are an approach in wound care, utilizing materials impregnated with anti-microbial agents to inhibit bacterial colonization. Unlike antiseptics, these agents cause less trauma to wound-healing cells. Examples like Kerlix A.M.D.™ incorporate polyhexamethylene biguanide (PHMB), which disrupts microbial membranes, leading to irreversible microbial death without promoting resistance. These dressings, available in various forms including gauze, are particularly effective in preventing bacterial infection in surgical incisions and wounds near synovial structures. Studies demonstrate their ability to stop bacterial penetration, highlighting their efficacy. When used on open wounds, moistening with saline is recommended to prevent drying (Hendrickson, 2004).

These dressings help control infection, a significant factor in delayed wound healing. Examples include (Caston, 2012):

- Iodine-Containing Dressings (ICDs): Release iodine to exert antibacterial effects, useful for contaminated wounds.
- Silver-Impregnated Dressings (SIDs): Release silver to kill bacteria and fungi. They vary in effectiveness and cytotoxicity.
- Activated Charcoal Dressings (ACDs): Absorb bacteria and reduce wound odor, useful for heavily infected wounds.
- Antibiotic-Impregnated Collagen Sponges (AICS): Deliver antibiotics like gentamicin directly to the wound, useful for infected and deep wounds.

Antimicrobial dressings like those with iodine and silver have varied effects on bacterial control and wound healing, with some showing significant cytotoxicity (Leise, 2018). These are recommended during the inflammatory phase and early repair phase for infected wounds. Topical antibiotics are most effective within 3 hours of injury. They can also be applied within 3 hours of debridement for new wounds (Ferrer, 2019).

Triple Antibiotic Ointment Contains bacitracin, polymixin B, and neomycin; effective against many bacteria but not *Pseudomonas aeruginosa* (Leise, 2018). Zinc in bacitracin can promote epithelialization but may slow wound contraction (Ribeiro *et al.*, 2024).

- **Biologic Dressings**

Biologic dressings, derived from natural body products, are bioactive and aid wound healing by promoting contraction and epithelialization while reducing granulation tissue formation. They also induce a beneficial mild inflammatory response. Some of them are:

- Equine Amnion (EA)

EA is considered an ideal dressing, promoting epithelialization and faster healing without causing excessive granulation tissue. It's particularly useful for distal limb wounds and pinch-

grafted wounds, often secured with super glue and stored properly for up to 6 months (Boone and Peroni, 2023).

- Equine Peritoneum (EP)

EP is rich in collagen but studies show it does not significantly enhance healing in distal extremity wounds compared to other dressings (Stashak *et al.*, 2004).

- Split-Thickness Allogeneic Skin (STS)

STS does not significantly speed up healing compared to other biological and synthetic dressings (Stashak *et al.*, 2004).

- Omentum (O)

Used in small animals for chronic wounds, O is less practical for horses due to its short attachment to the stomach (Stashak *et al.*, 2004).

- Collagen Dressings (CDs)

Collagen plays a crucial role in normal skin and wound healing, influencing the final wound strength through its production, maturation, and degradation. Exogenous collagen, available in various forms such as powders, gels, and sponges, maintains a moist wound environment and promotes epithelialization and reduced inflammation, as observed in studies with dogs. Collagen dressings serve as scaffolds for fibroblasts and chemotactic agents for white blood cells, making them beneficial during the granulation stage of wound healing. After adequate granulation tissue formation, semi-occlusive foam dressings are recommended. CDs come in various forms (gels, membranes, sponges) and are effective in humans and laboratory animals, but studies in horses show mixed results (Boone and Peroni, 2023).

- Extracellular Matrix (ECM)

Porcine ECM scaffolds, like PUBBM and PSIS, promote tissue-specific healing with minimal scarring. ECM scaffolds are not beneficial for small, naturally healing wounds (Stashak *et al.*, 2004).

- Protein-Free Dialysate of Calf Blood (PFD)

PFD accelerates initial wound healing but prolonged use can delay epithelialization. Best used during the early inflammatory phase (Boone and Peroni, 2023).

- Platelet-Rich Plasma (PRP)

PRP, derived from autologous or homologous sources, contains growth factors that promote tissue repair and is beneficial for wound healing (Iacopetti *et al.*, 2012).

- Hyaluronic acid (HA)

HA is essential for tissue structure and wound healing, influencing cell behavior and extracellular matrix organization. Modified HA products, such as equitrX, have demonstrated effectiveness in accelerating wound healing in horses, particularly the gel formulation, which is recommended for promoting healthy tissue formation during early wound stages (Ribeiro *et al.*, 2024).

- **Liquid Adhesives**

- Cyanoacrylates (CAL)

CAL like Nexaband® reduce edema and inflammatory infiltrates, effective for small, clean limb wounds (Wilson, 2009).

- Hydroxyethylated Amylopectin (HEA)

HEA forms a non-occlusive, water-soluble adhesive barrier, suitable for small, dry, clean wounds

5.1.6.2. Bandages

Bandages serve multiple functions in wound care: they protect wounds from additional trauma, desiccation, and contamination; absorb secretions; assist in removing dead tissue; lessen bleeding and swelling; and minimize movement around the wound site to allow the granulating tissue to grow (Eggleston, 2018).

The importance of a proper bandage in equine wound care cannot be overstated, despite the challenges and costs involved. While some evidence suggests that bandages can lead to exuberant granulation tissue, other studies indicate that wounds heal faster with bandages than without. A well-applied bandage can stop bleeding, prevent contamination, minimize movement around the wound site to allow the granulating tissue to grow, provide a moist healing environment, and reduce swelling. However, an improper bandage can be harmful (Eggleston, 2018).

Bandaging is often stopped prematurely, not done at all, or done incorrectly, likely due to the time and effort required. Common mistakes include insufficient padding. The standard distal limb bandage consists of three layers: primary, secondary, and tertiary, each serving specific functions crucial for wound management (Caston, 2012).

The primary layer is crucial as it is in direct contact with the wound, playing a pivotal role in wound management. Its customization according to the healing stage and desired wound effect is essential. Nevertheless, improper utilization of the primary layer can potentially harm the wound. This layer is classified based on material type, gas and fluid exchange properties, and adherence capability (Eggleston, 2018).

The secondary layer serves primarily to absorb fluids and offer extra protection for the wound. Comprising sheet or roll cotton, it provides adequate thickness for fluid absorption and wound cushioning.

On the other hand, the tertiary layer secures the bandage and can offer immobilization as needed. Constructed with cohesive bandage or self-bonding material, it allows for application with varying pressure. However, it's crucial to ensure sufficient padding from the secondary layer to prevent tissue damage caused by tightly applied tertiary layers (Eggleston, 2018).

Bandage changes are typically needed every few days but may be more frequent initially if there is ongoing bleeding or other treatments required. After the wound stabilizes, changes can be less frequent, about every 3-5 days, or up to 7-10 days if well-padded and secured. Stall confinement can help prolong bandage life but is not always necessary (Caston, 2012).

When discontinuing bandaging, owners should be warned about potential swelling. Gradually reducing bandaging time can help mitigate this issue. Increased exercise or a phased reduction in bandage application can help manage swelling and support the transition away from bandaging (Caston, 2012).

5.1.6.3. Other treatments:

- **Steroids**

Steroids have been a traditional component of equine wound care, primarily used to reduce excessive granulation tissue (Hendrickson, 2004). They work by inhibiting or decreasing the volume of such tissue. Hydrocortisone, for instance, has been found to alter the levels of plasminogen activators, crucial for wound homeostasis, while dexamethasone interferes with collagen synthesis and degradation, particularly affecting type III collagen, essential for wound healing induction. Triamcinolone has been shown to reduce vascular growth and granulation tissue formation, especially in topical administration. However, the use of steroids during wound healing may not be advisable for achieving optimal cosmetic results. Studies have demonstrated delays in wound healing associated with steroid use in various animal models. Instead, surgical

removal of excess granulation tissue and the application of moist wound healing techniques are recommended to promote efficient wound repair without excessive granulation tissue formation (Hendrickson, 2004).

- **Topical Agents**

Currently it exists multiple topical treatments that can promote and fasten the process of wound healing. Some of the most used in the equine veterinary medicine are the following:

Live Yeast Cell Derivative (LYCD): LYCD, a water-soluble extract of yeast, stimulates angiogenesis, epithelialization, and collagen formation. While beneficial in dogs, it prolonged wound healing in horses by delaying wound contraction and causing excessive granulation tissue formation. Best use is during the early repair phase (Dart *et al.*, 2005).

Honey (H): Possesses broad-spectrum antimicrobial activity, anti-inflammatory actions, and stimulates tissue growth. Varieties like Manuka honey have enhanced antimicrobial properties. It promotes granulation tissue formation and epithelialization, possibly through up-regulation of inflammatory cytokines. Best use is during the inflammatory to early repair phases (Leise, 2018).

Lanolin (L): Enhances epithelialization and dermal thickness, particularly beneficial for abrasions and during the maturation phase of wound healing (Dart *et al.*, 2005).

Phenytoin (PT): Originally an anti-seizure medication, PT shortens healing time and increases wound tensile strength. Its effects on horse wounds remain unknown (Dart *et al.*, 2005).

Gallium Nitrate (GN): Increases collagen and fibronectin expression, suppresses matrix metalloproteinase activity, and accelerates keratinocyte motility, but its clinical efficacy is unknown (Dart *et al.*, 2005).

Gentian Violet (GV): While proposed as a wound repair stimulant, evidence is lacking, and it may have adverse effects including tissue damage and carcinogenicity (Jacobsen, 2016).

Recombinant Vasoactive Protein (RVP): Enhances wound breaking strength and open wound healing, primarily during the repair phase (Dart *et al.*, 2005).

Scarlet Oil (SO): Commonly used in horse wound treatment, but it lacks of controlled studies to assess effectiveness. Can cause painful contact dermatitis (Leise, 2018).

Aminoplex (AP): Contains amino acids, trace minerals, and peptides, purported to enhance wound healing, but no data exists for its use in horses (Dart *et al.*, 2005).

Sugardine (SD): A hypertonic agent used for sub-solar abscesses, drawing exudate from the wound (Leise, 2018).

Zn7TM Equine Wound Care Formula (ZE): Contains zinc gluconate, providing anti-pruritic, antimicrobial, and wound healing benefits, primarily used during the early repair phase.

Tripeptide-Copper Complex (TCC): Promotes angiogenesis, epithelialization, and collagen deposition, best used during the repair phase (Leise, 2018).

Vitamin E (E): A lipid-soluble antioxidant with inconclusive effects on wound healing, commonly used during the maturation phase in horses. Clinical trials are lacking to support its efficacy (Dart *et al.*, 2005).

Allantoin: Allantoin is a compound that occurs naturally in plants such as comfrey, wheat sprouts, and sugar beets. It is particularly valued for its calming effects on sensitive or irritated skin (Rivera, 2023).

- **Topical Herbal Therapies**

Herbal preparations or essential oils are a component of alternative medicine, offering a variety of approaches to wound care (Ferrer, 2019). These therapies often involve small amounts of plant material combined with a delivery vehicle like ointment. Few herbal therapies have been tested for effectiveness and toxicity in horses, warranting further study for those considering their use. Some of these herbs includes: Aloe Vera, Comfrey (*Symphytum officinale*), Eucalyptus, Goldenseal (*Hydrastis canadensis*), Matihorse (*Piper angustifolium*), Propolis or Tea Tree Oil (*Melaleuca alternifolia*) (Farstvedt *et al.*, 2004).

- **Aerosol Sprays**

Some of the aerosols that we can find are: Furazolidone (F) aerosol powder, initially designed for human gastrointestinal infections, has shown promise in treating equine wounds, particularly in mitigating fight-inflicted lacerations. Alu-Spray® (AS) acts as a physical barrier against environmental contaminants and insect pests, suitable for safeguarding unbandaged surgical sites and minor lacerations. Conversely, Cut-Heal® (CH), while popular among horse owners, contains potentially irritating ingredients and is not recommended. Lastly, Blu-Kote® (BK) serves as a topical treatment for minor abrasions, consisting of sodium propionate, gentian violet, and acriflavine (Jacobsen, 2016).

- **Negative-Pressure Wound Therapy (NPWT).**

Negative-pressure wound therapy (NPWT), also known as vacuum-assisted closure (VAC), has been used in human medicine for several years. This technique involves applying continuous or intermittent sub-atmospheric pressure (approximately 125 mmHg) (Launois *et al.*, 2021). NPWT operates through several mechanisms, such as reducing dead space, removing exudates, decreasing edema by expelling proinflammatory mediators, enhancing dermal perfusion, and clearing wound debris. Additionally, the mechanical stress induced by negative pressure stimulates the release of growth factors, promoting cell proliferation and micro deformation of the wound surface, which enhances healing through granulation tissue formation. NPWT also significantly reduces bacterial load within the wound bed (Cantatore *et al.*, 2023).

In equine medicine, the use of NPWT is less common compared to human medicine. However, with the advent of smaller and lighter devices, its use in clinical cases for horses has increased. NPWT has shown to improve outcomes and reduce complications, making it an increasingly established treatment for aiding the healing of challenging wounds in horses (Cantatore *et al.*, 2023).

- **Skin graft**

Skin grafts are categorized into two main types: pedicle grafts and free grafts.

Pedicle grafts remain temporarily attached to the donor site by a pedicle, which supplies blood and nutrients, enhancing the graft's viability and likelihood of acceptance. This method transfers all skin components, resulting in excellent cosmetic outcomes (Schumacher and Hanselka, 1989).

Free grafts (Figure 2) are completely detached from the donor site before being transplanted to the recipient site. Unlike pedicle grafts, free grafts do not maintain any connection to the original blood supply. Instead, they rely on the development of new blood vessels from the recipient site to survive and integrate. Free grafts are most of the times used to cover large or complex wounds where primary closure is not possible (Schumacher and Hanselka, 1989). Their success depends on factors like the health of the recipient site, proper surgical technique, possibility of immobilization and post-operative care (Bristol, 2005).



Figure 2: Process for performing a free skin graft on a horse. Source : Equitom clinic, equitom.be, June 2021.

- **Laser therapy**

Low-level laser therapy (LLLT) utilizes light to stimulate tissue healing, reduce inflammation, and alleviate pain, without generating heat but through light energy absorption, likely within the mitochondria of treated cells. According to Jann *et al.* wounds treated with low-level laser therapy (LLLT) healed faster than control wounds, and one of the most important discovery of this research was the absence of exuberant granulation tissue in the laser-treated wounds (Ribeiro *et al.*, 2024). It fosters myofibroblast generation, collagen deposition, and keratinocyte proliferation while mitigating oxidative stress and inflammation. Though studies on wound healing vary in equipment and protocols, LLLT emerges as highly effective for acute and chronic wounds across species. Assuring the right parameter like time and amount of energy is essential for optimal outcomes. Each manufacturer has different protocols, so it's important to consult the protocol suggested by the manufacturer. Class 3B lasers, especially portable ones, are preferable in veterinary medicine. For equine wound care, large LED cluster probes covering a wide area are an advantage, it reduces swelling and promotes tissue healing. However, it's recommended to be aware with higher-power infrared single laser and laser cluster probes, to avoid damaging healing tissue. Treatment typically is applied for 30-60 seconds and repeated 2-3 times weekly for 2-3 weeks (Dahlgren, 2018).

- **Cell-Based Therapies**

Cells play a crucial role in the wound healing process. Fibroblasts secrete extracellular matrix components such as collagen and glycosaminoglycans, while myofibroblasts are responsible for wound contraction (Harman *et al.*, 2023). White blood cells aid in wound debridement, cell recruitment, and matrix production stimulation. Regenerative medicine approaches, particularly the use of mesenchymal stem cells (MSC), aim to enhance wound healing by delivering trophic mediators that stimulate and coordinate an improved healing response (Ribeiro *et al.*, 2024). Additionally, MSCs at the injury site may differentiate into mature cell types, such as fibroblasts, directly contributing to the healing process (Dahlgren, 2018).

- **Gas therapy**

Ozone: Ozone is an unstable molecule composed of three oxygen atoms, which can quickly split into free oxygen atoms, acting as a potent oxidant that eliminates microorganisms. Topical application of ozonized vegetable oils, such as olive oil, due to the formation of trioxolane from the unsaturated fatty acids in the oil, which represents the active form of ozone in these substrates. Trioxolane enhances healing and possesses antibacterial and antifungal properties (Ferrer, 2019). Araujo *et al.* found no significant differences between ozone treatments and the control group, whereas Di Filippo *et al.* (2020) reported that ozonated sunflower seed oil accelerated acute cutaneous wound repair in horses and prevented hyper-granulation tissue and infection. Studies carried out by Kim *et al.* (2009) demonstrated that the presence of ozone accelerated skin repair (Ribeiro *et al.*, 2024).

Topical oxygen therapy (TOT): Topical oxygen therapy can be used as an adjunctive advanced modality to help to treat chronic wounds failing to respond to a trial of conservative managements (Oropallo and Andersen, 2023). Some studies have shown no significant impact on wound area, epithelialization, wound contraction, histology, or culture results compared to control wounds, and no adverse effects were noted (Ribeiro *et al.*, 2024).

Hyperbaric oxygen therapy (HBOT): involves placing the animal in a pressurized chamber and administering pure oxygen at higher than atmospheric pressure. This therapy aims to increase the oxygen content in the horse's blood and tissues (Holder *et al.*, 2008). After full-thickness skin grafts the use of this technique resulted in less granulation tissue, edema, and neovascularization but increased inflammation, making the superficial portion of the graft less viable than the control. Consequently, HBOT was not recommended (Ribeiro *et al.*, 2024).

5.1.7. Calcium sulphate (CaSO₄).

Calcium sulphate, more known as cast or plaster of Paris is an unusual biocompatible material that is known to help angiogenesis, better cellular migration than other agents when in contact with the defect, along with its active role in increasing certain growth factors and their diffusion that aid in connective tissue regeneration, make it a more than appropriate candidate as an adjunct in the treatment of these injuries, promoting healing and acting as a barrier against external agents (López *et al.*, 2011). This biomaterial has been used in human medicine in dentistry and bone regeneration. This material presents many advantages one of them is to be very well tolerated by the organism, don't provoke a severe inflammatory response, creates a calcium-rich milieu in the implantation area which can help also in the coagulation phase. Calcium plays an important role in wound healing from early roles in hemostasis and inflammation to promote keratinocyte differentiation, fibroblast contraction, and angiogenesis. Recent advancements in calcium-based scaffolds in human medicine demonstrate their potential in enhancing cell attachment, promoting tissue regeneration, and accelerating wound closure (Subramaniam, 2021).

It presents many characteristics that are useful in tissue regeneration in addition to not be expensive and be very abundant (Thomas, 2005). Its application in equine medicine, particularly for treating limb wounds, is less well-documented but holds considerable promise (Thomas, 2005). The efficiency of this material was observed first in war wounds. Some doctors realize that after immobilizing a patient with a plaster, the wound underneath healed without almost any complications. This method is originally from a human medicine surgeon called Dr. Winnet (Rivera, 2023).

This product presents the advantage of being very affordable, be porous, be antiseptic and to have an easy and fast application (Rivera, 2023).

We can find two forms of application: as a powder or as a dressing. This product can be found in pharmacies or in the hardware stores, which could also sound a little strange to some owners that use this technique for the first time.

Another advantage of this technique is that in can be combined with other techniques to promote a faster healing. Some of the techniques to combine with sulphate of calcium can be manuka honey which has been shown in different studies the efficacy in promoting wound healing (Freeman *et al.*, 2021). Or also allantoin, which has been demonstrated to promote and fasten the re-establishment of normal skin in rats in studies made by Araujó *et al.* (2010). This product should be applied directly on the wounds area without any gauzes or dressing between the plaster and the wound. This is essential for the success of this technique. At the beginning some people used to think that, to prevent the possible lacerations due to the contact of the skin with the plaster, it was helpful to put a layer of gauze between the plaster and the wounds. But this only leads to accumulation of the fluids in the gauzes and make a perfect environment

for bacteria to grow and slow down the healing process, so it's important to always put this product in direct contact with the wound (Rivera, 2023).

The plaster should be changed every week or every two weeks, after cleaning the exudates that is very normal to have when using this technique. This is something that should be warned to the owner because these exudates can lead to think that the wound is infected, but this is just the normal exudate that we can find when using this technique.

One of the main disadvantages is that it's a very slow process and takes some time to see the results. This is why the main key point that we need to make this technique efficient is to have patience and explain to the owners that it will take time to heal (Rivera, 2023).

There is not much literature or studies about this technique, but a retrospective study of 49 cases made by Ketzner *et al.* (2009) in the University of Missouri Veterinary Medical Teaching Hospital, Columbia, Missouri, USA. Showed that in pastern or foot wounds treated with phalangeal cast carried a good prognosis with a total recovery in 89.4% of the cases and good cosmetic healing in 89.5% of the cases. Overall, the phalangeal casts were well-tolerated and effective. Even though, in this study they had a positive result, the main use of plaster in this study had the aim of immobilize the area with the wound to promote the healing. It wasn't used for the biological properties of the sulphate of calcium. But it's very probable that it had also promote the healing process due to the properties of this biomaterial.

5.1.8. Discussion of the narrative review.

After analyzing the scientific literature found, it's been seen that several factors can affect the wound healing process. Every phase of wound healing has a different objective and cellular mechanism, which makes the treatment of wounds a complex situation to manage for the equine practitioner. A bast number of techniques can be used in second healing wound but rarely has it been scientifically proven that one technique is more effective than another. Wound healing by second intention, is a very complex treatment that requires a very good acknowledge of the wound healing process and to determine the phase in which the wound is in the moment when it's treated. A compilation of the different techniques and studies have been made to determine the best way to approach the healing by second intention. The BEVA guidelines for evidence-based medicine on equine wound healing made by Freeman *et al.* (2021) and the best protocol to treat equine skin wounds by second intention healing: A Scoping Review of the Literature by Ribeiro *et al.* (2024) are a good summary of the current techniques and their efficacy.

The scientific literature regarding the sulphate of calcium or plaster of Paris is very limited even in human medicine. Most of the information obtained of this technique is found in conferences or congress and equine practitioner who have experience using this technique. Even though, the experience of the equine practitioners that have used this technique are very optimism with this technique, there still no scientific evidence that proves the efficacy.

In comparison with other techniques, we can see that for example, a regular absorbent dressing helps maintain as sterile an environment as possible and absorbs exudates but does not provide all the biological properties that calcium sulfate has. Calcium sulfate can serve as a scaffold for new tissue growth and may help in managing infection and promoting wound healing among other properties. Additionally, an absorbent dressing requires frequent changes and is more likely to shift and deteriorate sooner (López *et al.*, 2011). Other techniques require more attention and complex care.

5.2. Descriptive study

Firstly, a general overview of the results obtained in the cases is presented. Secondly, each case is presented showing for each case: anamnesis, treatments and outcomes.

Since the number of cases was limited, only a descriptive statistic of the data that was performed with the variables obtained from the different cases.

General overview

After collecting the cases and data from HVUZ or referring veterinarians, 8 cases met the inclusion criteria and were included in this study (n=8). All cases treated basically with the same technique of calcium sulphate, so no other technique was included in this study. After gathering all the information and determining the variables to be included in this study, we obtained the data for each case presented in Table 1.

Table 1: Summary of studied variables in the included cases.

Variable	Case 1	Case 2	Case 3	Case 4	Case 5	Case 6	Case 7	Case 8	Median
Breed	Half-bred	KWPN	French Trotter	Half-bred	Anglo-arab	PRE	KWPN	Half-bred	
Sex	Female	Male	Female	Male	Female	Female	Male	Female	
Age (years)	17	20	5	1.5	11	3	4	2	4.5
Wound location	Fetlock	Tarsus-metatarsus	Fetlock	Carpus+fetlock	Tarsus-metatarsus	Tarsus-metatarsus	Pastern	Canon	
Bone or joint exposure	No	Bone	No	Bone and joint	No	No	No	No	
Lameness	Yes 1/5	No	No	No	No	No	No	No	
NSAID's	Yes	Yes	Yes	Yes	Yes	Yes	Yes	No	
Antibiotics	Yes	Yes	No	Yes	Yes	No	No	No	
Surgery	No	Yes	No	Yes	No	No	No	No	
Bandage frequency (days)	6	8.5	7	3.5	2.5	3.5	3.5	3.5	3.5
Healing time (weeks)	7	12	6	17	4	4	6	7.5	6.8
Cost approx. (euros)	625.7	1369.3	525.8	1233.7	548.7	519.7	651.6	687.8	638.3
Complications	No	Bone sequestration	No	Bone sequestration	No	No	No	No	

Of the 8 cases under the study, 37.5 % were castrated males (geldings), and 62.5% mares. Regarding the age the median age of the patients was 4.5 years +/- IQR= 12.3, a relatively homogeneous age distribution among the sample population with a tendency towards young ages. The range age of the data obtained was between 1.5 years (minimum) and 20 years old (maximum).

Research done in human medicine shows the existence of gender-based disparities in healing outcomes for specific medical conditions. Notably, studies have revealed differences in wound healing rates and treatment responses between males and females (Stashak, 2018). In

veterinary medicine it has been proved that compared to aged females, aged males experience delayed healing in acute wounds. Hormones such as female estrogens (estrone and 17 β -estradiol), male androgens (testosterone and 5 α -dihydrotestosterone, DHT), and their precursor dehydroepiandrosterone (DHEA) have an important influence in the wound-healing process. While androgens negatively regulate cutaneous wound healing, estrogens can enhance the healing process impaired by aging. Investigations into hormonal factors, immune system variances, and genetic predispositions have been conducted to elucidate potential discrepancies in healing processes (Guo and DiPietro, 2010). Among the breeds included in this study, crossbreeds constitute the largest segment, comprising 37.5% of the total population. The French Trotter, PRE (Pura Raza Española), and Anglo-Arab breeds each contribute equally, representing 12.5% of the total. Notably, the KWPN (Dutch Warmblood) breed stands out with a representation of 25.0%, making it the second most prevalent breed in the sample, as we can see in table 3. This distribution underscores the diverse mix of breeds present in the studied population, with crossbreeds being the most numerous and KWPN exhibiting a notable presence.

Breeds have different morphology that could also affect the process of the wound healing. Thoroughbreds and other breeds with long, thin-skinned limbs have tendency to excessive granulation tissue. The poor blood supply in the limbs, due to minimal tissue between bone and skin, makes them particularly vulnerable during healing (Knottenbelt, 1997). It's been also scientific evidence that shows that the healing process in wounds of ponies are faster than in horses (Stashak and Theoret, 2008).

Systemic treatments

In the analysis of treatments administered across the dataset (Table 2) it was found that 87.5% of cases utilized NSAID's, while 12.5% did not. The use of antibiotics was evenly distributed, with 50% of cases receiving it and 50% not. Similarly, the application of both NSAID's and antibiotics exhibited an equal split, each accounting for 50% of cases. Notably, a minority of cases (12.5%) did not undergo any form of treatment, compared with the majority (87.5%) that received some form of systemic treatment.

Table 2: Table representing the treatments used in the cases of the study.

Treatments	Yes	No
Use of NSAID's	87.5%	12.5%
Use of antibiotic	50%	50%
Both	50%	50%
No treatment	12.5%	87.5%

The BEVA guidelines for evidence-based medicine on equine wound healing pointed out that in the present literature it has been shown that, silver sulfadiazine reduces antimicrobial load in wounds, but has limited or no effect on wound healing in horses time (Freeman *et al.*, 2021). Several experimental studies have assessed the impact of antimicrobial agents on the treatment of equine skin wounds, generally reporting no improvement in healing outcomes. Harmon *et al.* observed no differences in time to wound closure or histological characteristics of wound healing when comparing treatments including 1% silver sulfadiazine cream, triple antimicrobial ointment (neomycin sulfate, bacitracin zinc, and polymyxin B sulfate), hyperosmolar nanoemulsion with 0.063% thymol, and a control group (Harmon *et al.*, 2017). Similarly, Berry II and Sullins found no significant differences in healing parameters such as mean days to healing, percentage of wound contraction, or epithelialization rate between wounds treated with 1%

silver sulfadiazine cream, slow-release matrix of 1% silver sulfadiazine, povidone-iodine ointment, and untreated controls. Additionally, Bischofberger et al. reported delayed healing in wounds treated with a commercial antibiotic ointment containing bacitracin, neomycin, and polymyxin B (BNP) (Ribeiro *et al.*, 2024).

To this fact it must be added the antibiotic resistance that it's promote every time that and antibiotic is used unnecessarily (Ferrer, 2019).

The use of NSAID's in wounds have different theories. Some veterinarians would support the idea that inflammation is one of the initial phases of wound repair and that since NSAID's would reduce the inflammatory response inhibiting COX-1 and COX-2, the wound will take more time to heal (Rivera, 2023). Although studies on veterinary species are limited, substantial evidence from human and rodent research indicates that NSAIDs inhibit wound healing. The prevailing theory suggests that NSAIDs inhibit prostaglandin synthesis, which interferes with cell signaling and disrupts the coordinated healing process (Knych, 2017).

On the other hand, NSAID's are a necessary treatment to manage the swelling and reduce the pain that the patient will experience (Caston, 2012). Even though, there is strong evidence that pain and the stress response to pain can promote wound healing in the short term (Dart *et al.*, 2016).

Some studies made by Chhabra *et al.* show that NSAIDs and selective cyclooxygenase-2 (COX-2) inhibitors, commonly used as analgesics, inhibit the production of prostaglandin E2 (PGE2). It was observed that this inhibition could potentially worsen excessive scar formation, particularly when these drugs are used during the later proliferative phase of wound healing (Chhabra *et al.*, 2017). Studies made by Hussni *et al.* (2010) showed that the use of phenilbutazone delay the process in wound healing by second intention (Ribeiro *et al.*, 2024).

Location of the wounds

The wounds were in different anatomical structures. The highest frequency was observed in the tarsus-metatarsus area (37.5%), followed by the fetlock (25.00%). Other locations such as the canon, pastern, and carpus + fetlock each accounted for 12.5% of the total wounds.

Wound location can significantly impact the healing process. It's essential for equine practitioners to consider the anatomical location of wounds when developing treatment plans for horses undergoing second intention healing (Hendrickson, 2018). It's been known for years that wounds in the limbs specially in horses take more time to heal (Eggleston, 2018). This is caused by multiple factors. Influencing factors such as tissue perfusion, possibility to immobilize, and susceptibility to infection (Stashak, 2018). It has been demonstrated that wounds located in areas with high mobility or constant exposure to environmental contaminants may show a slower healing rate compared to wounds in regions easier to assure a good immobilization (Caston, 2012). It's known that the movement of the skin is higher in limb wounds that trunk wounds (Knottenbelt, 1997). Other factors such as temperature, blood supply, pH of the wounds, oxygen in the wound site or contraction rate can also affect the healing process.

Wounds heal faster at higher temperatures. Warm water hydrotherapy around 45°C can improve healing by increasing blood supply (Stashak *et al.*, 2004). However, limb wounds may heal slower due to the lower temperature compared to the trunk (Knottenbelt, 1997).

Limb perfusion is poor due to little bulk tissue between bone and skin, leading to a limited blood supply (Falanga, 1993). Damage to key arteries can cause serious tissue necrosis, while tight bandaging can reduce wound perfusion, causing further damage (Knottenbelt, 1997).

Oxygen is crucial for healing, but low oxygen tension can stimulate fibroblast activity, potentially leading to excessive granulation tissue (Falanga, 1993). Optimal oxygen levels are necessary for proper healing, but heavy dressings that are applied sometimes in limb wounds can create barriers to oxygen supply. Trunk bandages are usually less tight due to the difficulty to apply it (Falanga, 1993).

The rate of contraction of limb wounds is at best 25% of that of trunk wounds. The conversion of a fibroblast to a myofibroblast might rely on either blood-borne or local factors or both. The absence of this, or at least in the distal limb suggests that, in the horse, local factors, including tissue break-down and secretory products such as metalloproteinases and inflammatory mediators, may be more important than circulating systemic factors. The potential variation in fibroblast transformability across different body areas is an intriguing area for further research (Knottenbelt, 1997).

Complications

Regarding complications of the wound that could have an impact in the efficacy of the treatment were bone sequestration, which was the most prevalent, occurring in 20% of cases, followed by affected joints in 5% of cases. However, most of the cases (75%) presented no complications that could affect the treatment.

Knowing that the complications that were observed in these cases weren't complication derived for the treatment of sulphate calcium, but a complication of the characteristics of the wound itself. These complications of the wound could also affect the efficacy of the treatment.

We can see that wounds that had a complication also took more time to heal with the treatment since all the wounds complications needed to go through surgery and this made the healing process with this treatment longer.

Bone exposure and surgery

Among the cases with bone exposure (25%), all required surgery (100%), whereas those without bone exposure did not have surgery indicated, constituting the remaining 75% of cases. If we compare bone exposure frequency with the number of bone sequestration as a complication, we can see that it's very related.

Bone sequestration occurs when occurs when a segment of devitalized bone becomes separated from the surrounding healthy bone tissue (Hanson, 2008). this is very common in horse's limb wounds because of the lack of soft tissue to cover the bone structures of the limbs (Eggleston, 2018). Exposed bone without periosteum develops granulation tissue slowly due to its poor vascularity (Auer and Stick, 2012).

The only treatment to bone sequestration is to go to a hospital and remove the excess of periosteum under general anesthesia (Eggleston, 2018). Here we can see that only horses with this complication due to the exposure of the bone needed to go under surgery and consequently increment the cost of the treatment (Hanson, 2008).

It's important to remember that this complication of the wound may affect the healing process making it longer than usual, but this is a complication from the wound itself and it's not a complication from the treatment of sulfate of calcium.

Outcome: Lameness

Lameness was observed in only one case (12.5%), while the majority (87.5%) showed no signs of lameness. So, we can conclude that most of the cases had a good outcome and had a full recovery after treatment.

For the quantitative variables (Table 3) the median and interquartile range was performed obtaining the following information:

Table 3: Quantitative variables median and IQR.

	Median	Q1 (25th Percentile)	Q3 (75th Percentile)	IQR (Q3 - Q1)
Age (years)	4.5	2.1	14.4	12.3
Bandage Frequency (days)	3.5	2.1	5.6	3.5
Healing Time (weeks)	6.8	4.9	10.8	5.9
Cost (Euros)	638.7	236.9	638.7	401.8

A possible correlation between the data was observed. Therefore, although the initial idea was to make only descriptive statistics, to determine if the quantitative variables were statistically related, a Spearman correlation coefficient was performed. The Spearman correlation coefficient (0.9881) indicates a very strong and positive correlation between age and healing time, based on the range of observed data. This result suggests that, overall, as age increases, healing time tends to increase, although these data do not follow a normal distribution.

Wound healing is influenced by age and physical status, with younger individuals healing faster and with fewer complications than older ones. Older patients exhibit slower inflammatory responses, granulation tissue formation, and wound contraction, making them more susceptible to infection (Stashak and Theoret, 2008). Rapid, scarless healing is being seen in fetuses. While no specific data exists for horses, young horses seem to heal better than older ones. Systemic infections and diseases can delay wound healing, but these are less common in horses except for those with Cushing's disease, where high cortisol levels can suppress inflammation and delay healing (Stashak and Theoret, 2008).

The Spearman correlation coefficient between the healing time and the change of bandage frequency is approximately 0.8571. This indicates positive correlation between these two variables but not as strong as the other variables. In other words, there is a positive relationship between healing time and the frequency of bandage changes: as healing time increases, the frequency of bandage changes tends to increase.

Sulphate calcium dressing presents the advantage of being less frequently changed than occlusive dressing. A sulphate calcium dressing can be changed every week or every two weeks without any problem (Rivera, 2023). While an occlusive dressing should be changed between 3 to 5 days to prevent any complications (Eggleston, 2018).

Bandages are a very important part of the wound healing process. A good bandage should protect wounds from additional trauma, desiccation, and contamination, absorb secretions, assist in debridement, reduce hemorrhage and edema and limit wound movement (Eggleston, 2018). But some of the scientific literature shows that even though the origin of the EGT still has no specific pathogenesis known currently. Some of the hypothesis that we manage nowadays is the possibility that bandages can affect and promote this EGT (Anantama *et al.*, 2022). Full-thickness wounds on the distal limb of horses are more likely to develop excessive granulation tissue (EGT) when covered with a bandage or cast compared to similar wounds left unbandaged (Dart *et al.*, 2009).

This effect is attributed to several factors induced by bandaging or casting: an increased oxygen gradient between deeper tissues and the wound surface, which stimulates angiogenesis. A reduced oxygen tension in the wound tissues, and the creation of a moist, warm, and acidic environment that supports cellular migration and proliferation. Additionally, some dressings can irritate the wound, causing more inflammation and exudate accumulation at the surface, all of which encourage the formation of excessive granulation tissue (EGT). This explains why EGT is more common in limb wounds, as these are usually bandaged, unlike body wounds (Anantama *et al.*, 2022).

As for the healing time, sulphate of calcium has a mean of 42 days, which is similar to the NPWT treatment efficacy. A study made by Launois *et al.* (2021) shows that NPWT can be left from 1 to 7 days until it needs to be changed and a healing rate of 36 days (Launois *et al.*, 2021). But it requires the horse to be hospitalized and a more expensive treatment.

On the other hand, another study made by Carter *et al.* (2003), shows that wounds treated with Platelet Rich Plasma (PRP) gel have a healing rate of 72 days, which is almost double the time needed to treat a wound with sulphate of calcium (Carter *et al.*, 2003). With the data observed in this study, compared to other techniques the sulphate of calcium has a good healing rate, and it is also cheaper and simpler to apply (it could even be done by the owners themselves) than these other methods.

Description of included

Case 1

Anamnesis: A 17-year-old grey crossbreed mare, currently six months pregnant, primarily engaged in leisure and show jumping activities, presented with a wound on her left front fetlock on 19/10/2023. The wound caused severe lameness (grade 5/5), making weight-bearing impossible. Initial treatment included broad-spectrum antibiotic therapy with procaine penicillin IM at 22 mg/kg BID for 6 days and gentamicin IV at 6.6 mg/kg SID for 5 days. The wound site was meticulously prepared, shaved, cleansed with chlorhexidine soap and alcohol, and irrigated with saline solution under pressure.

Treatment and Bandage Changes: Despite a recommendation for joint lavage under general anesthesia, it was declined, and a bandage was applied instead. NSAIDs (flunixin meglumine) were administered at 1.1 mg/kg SID for 5 days. A week later (25/10), a fetlock dislocation was diagnosed, leading to the placement of two PVC splints for stabilization. The bandage was changed several times every week, with the final plaster dressing removed after 41 days of treatment (29/11).

Outcome: Good closure of wound without further complications, but the mare continues to exhibit a lameness level of 1/5. This case has a special interest, because it's an articular wound that didn't need any joint lavage and was only treated with sulphate or calcium and still had a very good outcome.



Figure 3: The evolution of the healing process by secondary intention in this case.

Case 2

Anamnesis: A 20-year-old Hanoverian gelding experienced an injury on 30 January due to a trailer accident, resulting in a burn on the plantaro-lateral aspect of the right hind cannon bone. Part of the rudimentary bone IV was visible. Initial wound management included cleaning with chlorhexidine and applying Aquacell hydrocolloid dressing.

Treatment and Bandage Changes: The treatment regimen started with NSAIDs (Danilon, 500 mg SID for 7 days) and antibiotics (Equibactin, sulfamide - trimethoprim, 1 oral paste syringe SID for 8 days). A Robert-Jones bandage was applied to the cannon, and confinement to a small paddock was advised. Two days later, the wound was cleaned again, and the Aquacell dressing was reapplied. A week later (8/02), necrotic tissue resection and bone debridement were performed due to black bone fragments detaching. The exterior was treated with Dermagel, and chlorhexidine was used for interior treatment. On 12/02, treatment was switched to calcium sulfate bandages, changed every 7 to 10 days with debridement as needed and cleaning with chlorhexidine.

Outcome: After nearly three months (96 days), the granulation tissue appeared healthy with a uniform pink color. However, healing progress was slower than expected, with the exposed bone still palpable and the wound not closed where bone was exposed. Suspecting bone sequestration, radiography confirmed the condition, leading to referral to a hospital for debridement of excess bone under general anesthesia.

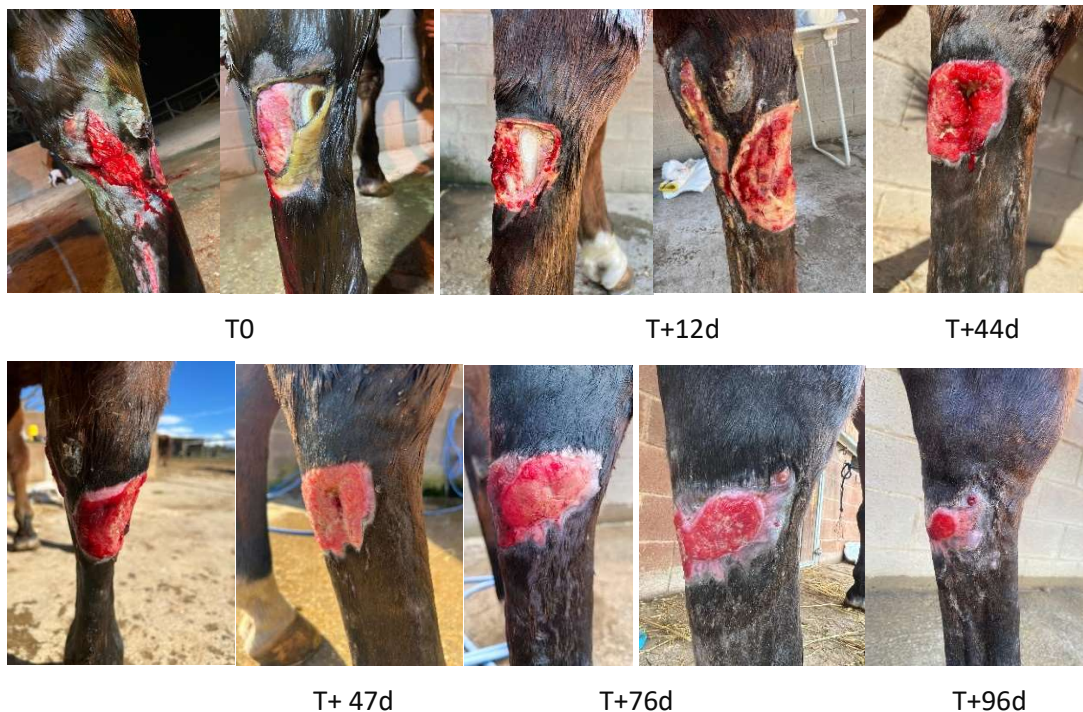


Figure 4: Evolution of healing by second intention using sulphate calcium bandages.

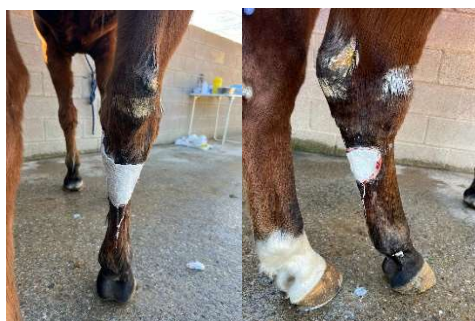

Figure 5: bandages of sulphate calcium applied in dressing form.

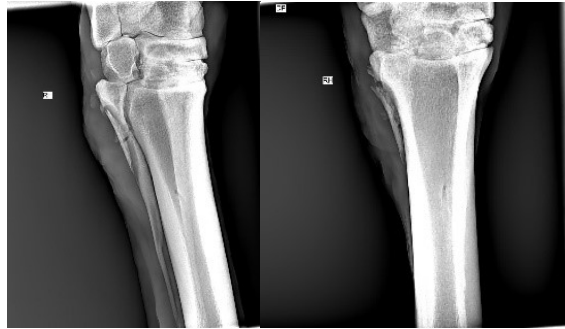


Figure 6: radiography showing bone sequestration on IV metatarsal bone.

Case 3

Anamnesis: A 5-year-old French Trotter mare presented on January 2nd with a wound sustained approximately 2.5 weeks prior in the pasture near the feeder. The wound on the right hind fetlock joint does not involve the joint itself, and there are no signs of lameness or fever. No antibiotic therapy was administered.

Treatment and Bandage Changes: Starting from January 2nd, only cold showers and calcium sulfate bandages are applied. These bandages are changed weekly until the wound closes.

Outcome: The initial management with cold showers and calcium sulfate bandages has resulted in favorable progress, with no complications such as lameness or signs of infection.



Figure 7: Evolution of healing by second intention using sulphate calcium bandages.

Case 4

Anamnesis: A year-and-a-half-old colt sustained multiple bite wounds on all four limbs from a dog attack, with the left forelimb (LF) carpus and fetlock being severely affected. The distal LF wound exposed and lacerated the digital flexor tendons, involving the tendon sheath. The carpal wound was sutured during initial treatment.

Treatment and Bandage Changes: Initially managed with calcium sulfate bandages after thorough wound irrigation, the colt was referred to a hospital for severe injuries. Surgical intervention included resection of bone sequestration and arthroscopically, irrigation of the digital flexor tendon sheath. Amikacin was administered intraarticularly, and wounds were debrided and dressed with calcium sulfate. Bandages were changed every two days for the LF fetlock and every five days for the carpus, with wound edge refreshment. Short hand walks were initiated.

Outcome: The colt showed favorable healing progress with resolution of lameness. Discharged from the hospital after 20 days, he is currently 43 days post-discharge, freely moving in a pasture, bearing weight normally on the affected limb, and the carpal and fetlock wounds are nearly completely epithelialized.

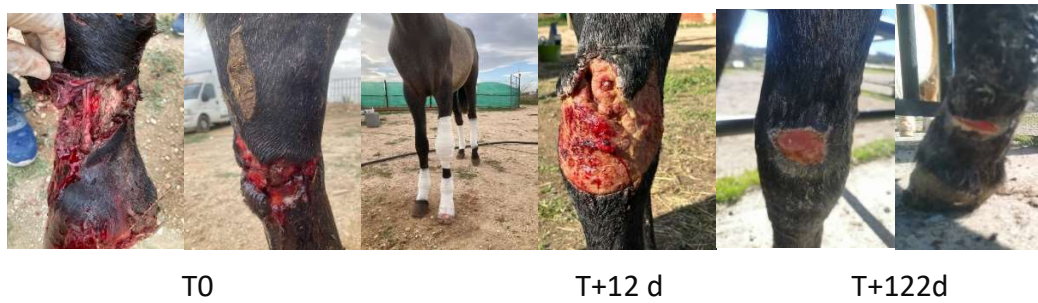

Figure (8): Evolution of healing by second intention using sulphate calcium bandages.

Case 5

Anamnesis: An 11-year-old Anglo-Arab mare used for Western riding sustained an injury on June 28, 2023, while loading into a van. The wound was cleaned and sutured despite tissue loss. A calcium sulfate dressing was applied and changed every 2-3 days.

Treatment and Bandage Changes: Broad-spectrum antibiotic therapy was started with IM penicillin and oral NSAIDs (phenylbutazone) for 12 days. Treatment initially involved topical dressings but was quickly switched back to calcium sulfate plaster dressings, which led to significant improvement and complete closure after a month of treatment.

Outcome: The mare shows a complete closure of the wound and no residual lameness following treatment.

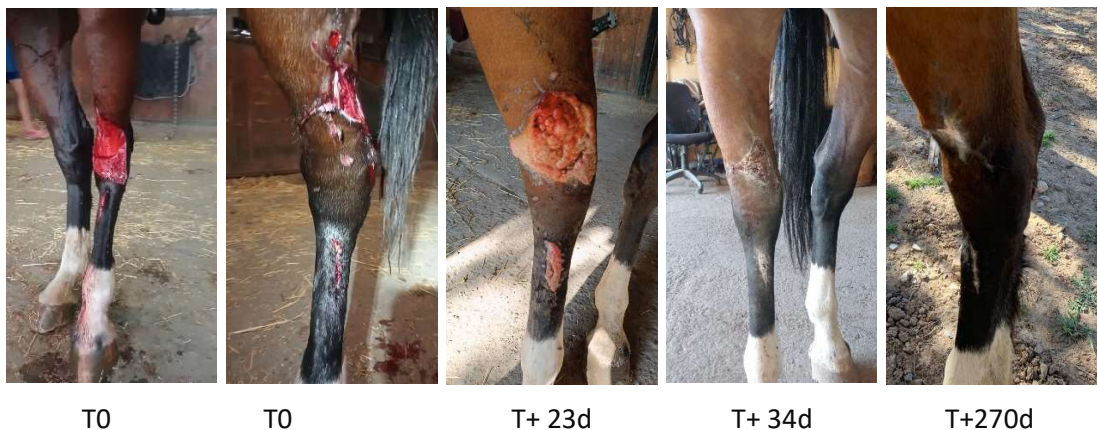

Figure 9: Evolution of healing by second intention using sulphate calcium bandages.

Case 6

Anamnesis: A 3-year-old purebred Spanish filly sustained an injury on September 25, 2023, while loading into a van. The wound did not communicate with the joint but extended distally.

Treatment and Bandage Changes: The wound was treated without systemic antibiotics. Sulphate calcium dressings were applied and changed every 3-4 days until complete closure. The last dressing was removed one month later on October 23, 2023. NSAIDs (phenylbutazone PO) were administered for one week. Afterward, topical Positon was applied twice daily for 14 days.

Outcome: The wound showed very good progress, and no residual lameness was observed.

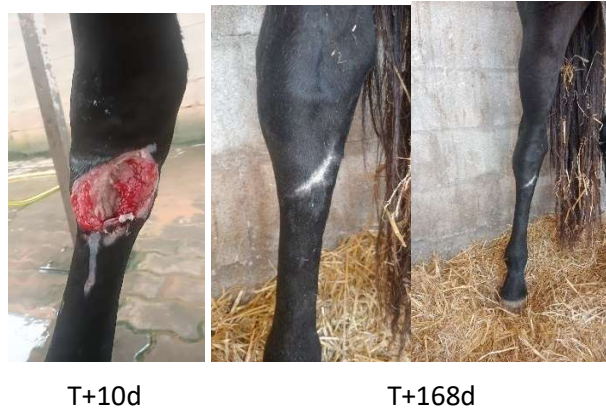

Figure 10: Evolution of healing by second intention using sulphate calcium bandages.

Case 7

Anamnesis: A 4-year-old castrated male KWPN horse sustained a wound on March 13, 2024, on the medial part of the right front leg, extending 2 cm distally and parallel to the heel line.

Treatment and Bandage Changes: The wound was treated with NSAIDs (phenylbutazone PO SID) for one week, without systemic antibiotics. Sulphate calcium dressings were applied every 3-4 days until closure of the injury.

Outcome: The wound is still in the healing process. The horse has not shown lameness or fever to the present moment.

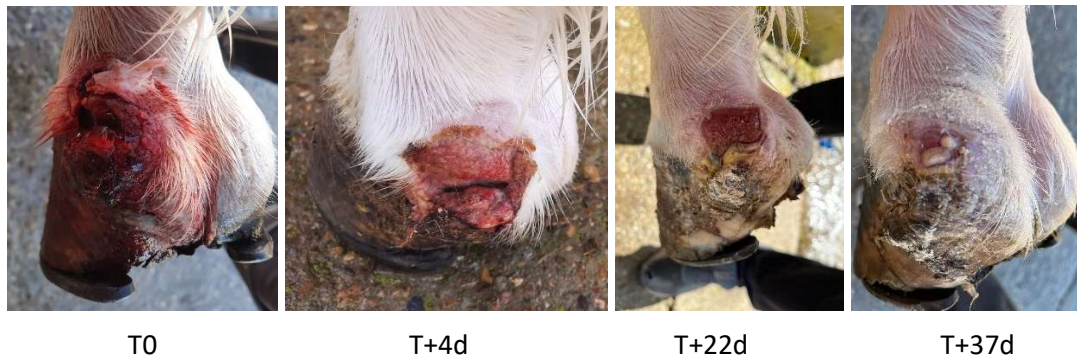

Figure 11: Evolution of healing by second intention using sulphate calcium bandages.

Case 8

Anamnesis: A 2-year-old crossbreed mare presented an injury on the medial aspect of the right forelimb canon while in a small paddock.

Treatment and Bandage Changes: The mare received calcium sulfate dressing and local wound care as the primary treatments. Bandages were change every 3 to 4 days until closure of the wound. No additional interventions or therapies were administered.

Outcome: The wound showed a good progress with an almost complete closure after 53 days of treatment. No lameness is reported in this case.

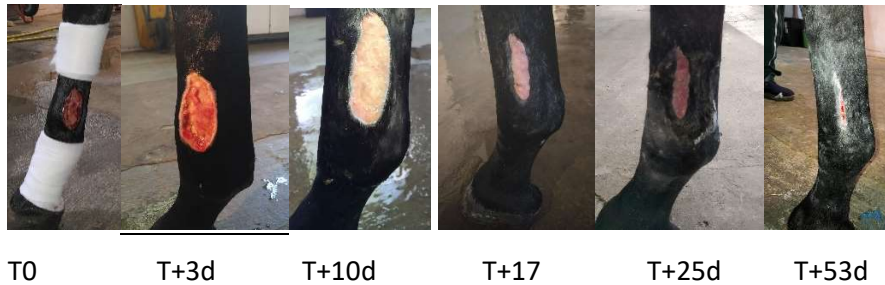

Figure 12: Evolution of healing by second intention using sulphate calcium bandages.

5.3. General discussion

After gathering all the information found in the bibliographic review and analyzing the result of the descriptive study carried out in this work, even though there is a lack of information about this technique. It's shown that compared to other technique the sulphate of calcium it's a very simple technique to use and very affordable and easy to find which is a very important advantage.

This product presents the advantage of being adapted to every phase of the wound healing that was mentioned in the first part of the narrative bibliographic review. Compared to other techniques it doesn't need a very frequent change of bandages since it's adapted for every phase of the healing process.

The simplicity of this treatment even allows the owner to make the change of bandages without needing the equine practitioner to travel to see the animal every time that a change of bandage is needed. It's a very promising technique in which there should be more studies and scientific investigation.

This descriptive study of 8 cases involving the use of calcium sulfate for second intention healing has several limitations. Firstly, the small sample size limits the generalization of the results obtained to a bigger population. It has been limited to that amount of cases, fundamentally, by the dimension and dedication of this final degree work (6 ECTS credits). Also considering that additionally to the study a narrative bibliography was also performed.

Additionally, the lack of a control group makes it difficult to compare the effectiveness of this technique against other actual treatments use for this issue. Moreover, data collection was performed remotely by veterinarians, making it impossible to assess the cases directly. Finally, the subjective assessment of healing outcomes could affect the reliability of the results.

6. Conclusions

Following a preliminary review of the scientific literature and a descriptive study of the use of calcium sulphate in these cases, under the conditions in which this work was conducted, the following conclusions can be drawn:

- I. There still a lot of controversy to determine which is the best protocol to promote the healing in second healing intention in horses. More research must be made to conclude which technique is currently the most effective.
- II. There's not enough information or studies providing scientific evidence about the efficacy of the use of sulphate calcium in wound healing in horses. However, there are empirical experiences suggesting that this could be a technique that is easy to use, cheap and effective.

- III. Even though a small number of cases were used in this small descriptive study, the results showed a very good efficacy of this treatment, showing a healing time of 6.5 weeks and no lameness in 87% of the cases.
- IV. Every year more and more equine practitioners are starting to use this technique, influenced by the experience of other vets, but without current scientific evidence of its efficacy. Even with these promising empirical results, bigger and more, well design studies are needed about this technique.

Conclusiones

Tras una revisión preliminar de la literatura científica y un estudio descriptivo sobre el uso del sulfato de calcio en estos casos, bajo las condiciones de este estudio, se pueden hacer las siguientes conclusiones:

- I. Aún existe mucha controversia para determinar cuál es el mejor protocolo para promover la cicatrización por segunda intención en caballos. Se necesitan más investigaciones para concluir cuál técnica es actualmente la más efectiva.
- II. No hay suficiente información o estudios que proporcionen evidencia científica sobre la eficacia del uso de sulfato de calcio en la cicatrización de heridas en caballos. Sin embargo, existen experiencias empíricas que sugieren que esta podría ser una técnica fácil de usar, económica y efectiva.
- III. Aunque un número reducido de casos fueron utilizados en este pequeño estudio descriptivo, los resultados mostraron una muy buena eficacia de este tratamiento, con un tiempo de cicatrización de 6,5 semanas y sin cojeras en el 87% de los casos.
- IV. Cada año, más y más veterinarios equinos están empezando a utilizar esta técnica, influenciados por la experiencia de otros veterinarios, pero sin evidencia científica actual de su eficacia. A pesar de estos prometedores resultados empíricos, se necesitan más estudios grandes y bien diseñados sobre esta técnica para determinar su eficacia.

7. Personal assessment

Completing this work has allowed me to study a species I have been passionate about since I was young and expand my knowledge on a topic that greatly interests me and has a very large field for future research. It provided an opportunity to collaborate with the host university of my exchange program, enabling me to meet many people and fully integrate into the host institution. It has been also an opportunity to practice and improve both languages that I currently speak which is French and English looking for information and consulting other teacher at other Universities. Additionally, I'm certain that the knowledge I gained through this work will be valuable for my future professional career. Moreover, this project improved my information search skills, introduced me to new platforms for finding quality articles, and taught me how to compare my results with those of other authors. Conducting both descriptive and analytical statistical studies also allowed me to apply the statistical knowledge. It has been a personal growth that has taught me how to work with more veterinarians of the equine medicine which will be my future profession.

Ever since I started my veterinary career I was really focused on the equine medicine. I started to do different externships since my first year as a veterinary student and this showed me that wounds were one of the main issues that an equine practitioner will have to face continually all along of his career. I started to see the significance in my first externship with a veterinarian,

Jorge Sánchez, that I personally met when I was working in an equestrian center in Madrid. Following this experience, I started different international externship in well known clinics such as Grosbois in Paris, France that had a lot of cases involving wound management. In my fourth year of career, I entered really motivated as an intern in the equine university hospital in Zaragoza (HVUZ) which allowed me to get a closer picture of the equine practitioner and the most common problems that are faced in equine medicine. This year, always with the best advice of my teachers specially, Paco Vázquez and Arantza Vitoria, I decided to come to France, Lyon as an Erasmus student and get to know one the most renowned clinics for the equine specie in France, Clinéquine. In that moment, we agreed with the veterinarians at this clinic that wounds were one of the main topics interesting in the equine practice and agree to collaborate in this project. Lastly, during my stay in Equitom clinic in Belgium, one of the biggest clinics for equines in Europe, allowed me to see many interesting and innovative treatments of wounds and meet great professionals that offered me directly after a week working with them a place as an intern in their clinic. I'm sure that I would like to pursue with my future career as an equine practitioner this topic and make further research in this subject as an intern in Equitom clinic, if I graduate this year, and my teachers that have always supported me.

8. Acknowledgements

I want to personally acknowledge all the support that I received during my five years of formation from my family and specially my teachers, Paco Vázquez and Arantza Vitoria that have always supported me and motivated me to be better every day.

To all the veterinarians that help in this work providing information and images about the different cases, specially to Olivier Lepage for letting me in the Clinéquine of Lyon to help and learn more about this topic and get to know this wonderful clinic. They have been an essential help to be able to do this work: HV-UZ and HCV-UCM equine services staff, Laura Tibau López, Carlos Sánchez Cuéllar, Helena Corina Pérez, Nekane Ardanaz, Coline Puidupin, Charlotte Pandaveine and Charles de Chaisemartin.

9. References

1. Anantama, N. A., Du Cheyne, C., Martens, A., Roth, S. P., Burk, J., De Spiegelare, W., *et al.* (2022). The granulation (t)issue: A narrative and scoping review of basic and clinical research of the equine distal limb exuberant wound healing disorder. *The Veterinary Journal*, 280, 105790. doi:10.1016/j.tvjl.2022.105790
2. Araújo, L. U., Grabe-Guimarães, A., Mosqueira, V. C., Carneiro, C. M., & Silva-Barcellos, N. M. (2010). Profile of wound healing process induced by allantoin. *Acta cirurgica brasileira*, 25(5), 460–466. <https://doi.org/10.1590/s0102-86502010000500014>
3. Auer, J. A., & Stick, J. A. (2012). *Equine surgery* Elsevier/Saunders.
4. Beuerlein, M. J., & McKee, M. D. (2010). Calcium sulfates: what is the evidence?. *Journal of orthopaedic trauma*, 24 Suppl 1, S46–S51. <https://doi.org/10.1097/BOT.0b013e3181cec48e>.
5. Bischofberger, A. S., Dart, C. M., Perkins, N. R., Kelly, A., Jeffcott, L., & Dart, A. J. (2013). The effect of short- and long-term treatment with manuka honey on second intention healing of contaminated and noncontaminated wounds on the distal aspect of the forelimbs in horses. *Veterinary surgery : VS*, 42(2), 154–160. <https://doi.org/10.1111/j.1532-950X.2012.01083.x>

6. Boone, L., & Peroni, J. (2023). Introduction to equine biologic and regenerative therapies. *Veterinary Clinics of North America: Equine Practice*, 39(3), 419-427. doi:10.1016/j.cveq.2023.06.006
7. Bristol, D. G. (2005). Skin grafts and skin flaps in the horse. *Veterinary Clinics of North America: Equine Practice*, 21(1), 125-144. doi:10.1016/j.cveq.2004.11.007
8. Cantatore F, Pagliara E, Marcatili M, Bertuglia A. Negative-Pressure Wound Therapy (NPWT) in Horses: A Scoping Review. *Vet Sci*. 2023 Aug 6;10(8):507. doi: 10.3390/vetsci10080507.
9. Carter, C. A., Jolly, D. G., Worden, C. E., Hendren, D. G., & Kane, C. J. M. (2003). Platelet-rich plasma gel promotes differentiation and regeneration during equine wound healing. *Experimental and Molecular Pathology*, 74(3), 244-255. doi:10.1016/S0014-4800(03)00017-0
10. Chhabra, S., Chhabra, N., Kaur, A., & Gupta, N. (2017). Wound Healing Concepts in Clinical Practice of OMFs. *Journal of maxillofacial and oral surgery*, 16(4), 403–423. <https://doi.org/10.1007/s12663-016-0880-z>
11. Dahlgren LA. Regenerative Medicine Therapies for Equine Wound Management. *Vet Clin North Am Equine Pract*. 2018 Dec;34(3):605-620. doi: 10.1016/j.cveq.2018.07.009. PMID: 30447771.
12. Dart, A. J., Perkins, N. R., Dart, C. M., Jeffcott, L. B., & Canfield, P. (2009). Effect of bandaging on second intention healing of wounds of the distal limb in horses. *Australian veterinary journal*, 87(6), 215–218. <https://doi.org/10.1111/j.1751-0813.2009.00428.x>
13. Dart, A. J., Cries, L., Jeffcott, L. B., Hodgson, D. R., & Rose, R. J. (2002). Effects of 25% propylene glycol hydrogel (Solugel) on second intention wound healing in horses. *Veterinary Surgery*, 31(4), 309-313. <https://doi.org/10.1053/jvet.2002.33585>
14. Dart, A. J., Dowling, B. A., & Smith, C. L. (2005). Topical treatments in equine wound management. *The Veterinary Clinics of North America. Equine Practice*, 21(1), 77–vii., , 77–vii. doi:<https://doi.org/10.1016/j.cveq.2004.11.003>
15. Dart, A. J., Sole-Guitart, A., Stashak, T. S., & Theoret, C. (2016). Management practices that influence wound infection and healing. *Equine wound management* (pp. 47-74) doi:10.1002/9781118999219.ch4
16. Dart, A. J., Sole-Guitart, A., Stashak, T. S., & Theoret, C. (2016). Selected factors that negatively impact healing. *Equine wound management*, 30-46. DOI:[10.1002/9781118999219.ch3](https://doi.org/10.1002/9781118999219.ch3)
17. Dart, A.J., Bischofberger, A.S., Dart, C.M. and Jeffcott, L.B. (2015), A review of research into second intention equine wound healing using manuka honey: Current recommendations and future applications. *Equine Vet Educ*, 27: 658-664. <https://doi.org/10.1111/eve.12379>
18. Di Filippo, P. A., Ribeiro, L. M. F., Gobbi, F. P., Lemos, G. B., Ribeiro, R. B., Jerdy, H., ... & Quirino, C. R. (2020). Effects of pure and ozonated sunflower seed oil (*Helianthus annuus*) on hypergranulation tissue formation, infection and healing of equine lower limb wounds. *Brazilian Journal of Veterinary Medicine*, 42(1), e113520-e113520. <https://doi.org/10.29374/2527-2179.bjvm1115321>
19. Eggleston R. B. (2018). Equine Wound Management: Bandages, Casts, and External Support. *The Veterinary clinics of North America. Equine practice*, 34(3), 557–574. <https://doi.org/10.1016/j.cveq.2018.07.010>
20. Eggleston, R. B. (2018). Wound management: Wounds with special challenges. *Veterinary Clinics of North America: Equine Practice*, 34(3), 511-538. doi:10.1016/j.cveq.2018.07.003
21. Elce, Y. A. (2016). Approaches to wound closure. *Equine wound management*, 157-172. <https://doi.org/10.1002/9781118999219.ch8>

22. Falanga, V. (1993). Chronic wounds: Pathophysiologic and experimental considerations. *Journal of Investigative Dermatology*, 100(5), 721-725. doi:10.1111/1523-1747.ep12472373
23. Falanga, V., Isseroff, R. R., Soulika, A. M., Romanelli, M., Margolis, D., Kapp, S., Granick, M., & Harding, K. (2022). Chronic wounds. *Nature reviews. Disease primers*, 8(1), 50. <https://doi.org/10.1038/s41572-022-00377-3>
24. Farstvedt, E., Stashak, T. S., & Othic, A. (2004). Update on topical wound medications. *Clinical Techniques in Equine Practice*, 3(2), 164-172. doi:10.1053/j.ctep.2004.08.003
25. Freeman, S. L., Ashton, N. M., Elce, Y. A., Hammond, A., Hollis, A. R., & Quinn, G. (2021). BEVA primary care clinical guidelines: Wound management in the horse. *Equine veterinary journal*, 53(1), 18–29. <https://doi.org/10.1111/evj.13289>
26. Fretz, P. B., & Li, Z. (1992). Low energy laser irradiation treatment for second intention wound healing in horses. *The Canadian veterinary journal = La revue veterinaire canadienne*, 33(10), 650–653.
27. Guo, S. A., & DiPietro, L. A. (2010). Factors affecting wound healing. *Journal of dental research*, 89(3), 219-229. <https://doi.org/10.1177/0022034509359125>
28. Gomez, J. H., & Hanson, R. R. (2005). Use of dressings and bandages in equine wound management. *The Veterinary clinics of North America. Equine practice*, 21(1), 91–vii. <https://doi.org/10.1016/j.cveq.2004.11.004>
29. Hanson R. R. (2008). Complications of equine wound management and dermatologic surgery. *The Veterinary clinics of North America. Equine practice*, 24(3), 663–ix. <https://doi.org/10.1016/j.cveq.2008.10.005>
30. Harman, R. M., Rajesh, A., & Van de Walle, G. R. (2023). Use of biologics and stem cells for wound healing in the horse. *Veterinary Clinics of North America: Equine Practice*, 39(3), 525-539. doi:10.1016/j.cveq.2023.06.003
31. Harmon, C. C. G., Hawkins, J. F., Li, J., Connell, S., Miller, M., Saenger, M., & Freeman, L. J. (2017). Effects of topical application of silver sulfadiazine cream, triple antimicrobial ointment, or hyperosmolar nanoemulsion on wound healing, bacterial load, and exuberant granulation tissue formation in bandaged full-thickness equine skin wounds. *American journal of veterinary research*, 78(5), 638–646. <https://doi.org/10.2460/ajvr.78.5.638>
32. Holder, T. E., Schumacher, J., Donnell, R. L., Rohrbach, B. W., & Adair, H. S. (2008). Effects of hyperbaric oxygen on full-thickness meshed sheet skin grafts applied to fresh and granulating wounds in horses. *American journal of veterinary research*, 69(1), 144–147. <https://doi.org/10.2460/ajvr.69.1.144>
33. Howard, R. D., Stasbak, T. S., & Baxter, G. M. (1993). Evaluation of occlusive dressings for management of full-thickness excisional wounds on the distal portion of the limbs of horses. *American journal of veterinary research*, 54(12), 2150-2154.
34. Hendrickson, A. (2004). *Wound care management for the equine practitioner*. Tenton NewMedia.
35. Hernigou P. (2016). Plaster of Paris: the orthopaedic surgeon heritage. *International orthopaedics*, 40(8), 1767–1779. <https://doi.org/10.1007/s00264-016-3179-2>
36. Hussni, C. A., GroH, T. M., ALves, A. L. G., CroCCi, A. J., de Mello Nicoletti, J. L., & WATAnAbe, M. J. (2010). Efeitos da fenilbutazona na cicatrização de feridas cutâneas experimentais em equinos. *Brazilian Journal of Veterinary Research and Animal Science*, , 262-267.
37. Iacopetti, I., Perazzi, A., Ferrari, V., & Busetto, R. (2012). Application of platelet-rich gel to enhance wound healing in the horse: A case report. *Journal of Equine Veterinary Science*, 32(3), 123-128. doi:10.1016/j.jevs.2011.08.012

38. Jacobs, K. A., Leach, D. H., Fretz, P. B., & Townsend, H. G. G. (1984). Comparative aspects of the healing of excisional wounds on the leg and body of horses. *Veterinary Surgery*, 13(2), 83-90. DOI:[10.1111/j.1532-950X.1984.tb00765.x](https://doi.org/10.1111/j.1532-950X.1984.tb00765.x).
39. Jørgensen, E., Bay, L., Bjarnsholt, T., Bundgaard, L., Sørensen, M. A., & Jacobsen, S. (2017). The occurrence of biofilm in an equine experimental wound model of healing by secondary intention. *Veterinary Microbiology*, 204, 90-95. doi:10.1016/j.vetmic.2017.03.011
40. Kamus, L., & Theoret, C. (2018). Choosing the best approach to wound management and closure. *Veterinary Clinics of North America: Equine Practice*, 34(3), 499-509. doi:10.1016/j.cveq.2018.07.005
41. Ketzner, K. M., Stewart, A. A., Byron, C. R., Stewart, M., Gaughan, E. M., Vanharreveld, P. D., & Lillich, J. D. (2009). Wounds of the pastern and foot region managed with phalangeal casts: 50 cases in 49 horses (1995-2006). *Australian veterinary journal*, 87(9), 363–368. <https://doi.org/10.1111/j.1751-0813.2009.00471.x>
42. Kim, H. S., Noh, S. U., Han, Y. W., Kim, K. M., Kang, H., Kim, H. O., & Park, Y. M. (2009). Therapeutic effects of topical application of ozone on acute cutaneous wound healing. *Journal of Korean medical science*, 24(3), 368–374. <https://doi.org/10.3346/jkms.2009.24.3.368>
43. Knych, H. K. (2017). Nonsteroidal anti-inflammatory drug use in horses. *Veterinary Clinics of North America: Equine Practice*, 33(1), 1-15. doi:10.1016/j.cveq.2016.11.001
44. Knottenbelt, D. C. (1997). Equine wound management: Are there significant differences in healing at different sites on the body? *Veterinary Dermatology*, 8(4), 273-290. doi:10.1111/j.1365-3164.1997.tb00273.x
45. Laia Ferrer Gordó. (2019). Use of antibiotics in second intention equine wound healing: Problems and alternatives. *Zaguan*.
46. Launois, T., Moor, P., Berthier, A., Merlin, N., Rieu, F., Schlotterer, C., et al. (2021). Use of negative pressure wound therapy in the treatment of limb wounds: A case series of 42 horses. *Journal of Equine Veterinary Science*, 106, 103725. doi:10.1016/j.jevs.2021.103725
47. Leekha, S., Terrell, C. L., & Edson, R. S. (2011). General principles of antimicrobial therapy. *Mayo Clinic proceedings*, 86(2), 156–167. <https://doi.org/10.4065/mcp.2010.0639>
48. Leise, B. S. (2018). Topical wound medications. *Veterinary Clinics of North America: Equine Practice*, 34(3), 485-498. doi:10.1016/j.cveq.2018.07.006
49. Lew, D. P., & Waldvogel, F. A. (2004). "Osteomyelitis." *The Lancet*, 364(9431), 369-379. [https://doi.org/10.1016/S0140-6736\(04\)16727-5](https://doi.org/10.1016/S0140-6736(04)16727-5)
50. López, J., & Alarcón, M. (2011). Sulfato de calcio: propiedades y aplicaciones clínicas. *Revista clínica de periodoncia, implantología y rehabilitación oral*, 4(3), 138-143. DOI:[10.4067/S0719-01072011000300012](https://doi.org/10.4067/S0719-01072011000300012)
51. Maher, M., & Kuebelbeck, L. (2018). Nonhealing wounds of the equine limb. *Veterinary Clinics of North America: Equine Practice*, 34(3), 539-555. doi:10.1016/j.cveq.2018.07.007
52. Marchant, K., Hendrickson, D.A. & Pezzanite, L.M. (2024) Review of the role of biofilms in equine wounds: Clinical indications and treatment strategies. *Equine Veterinary Education*, 36, 152–168. Available from: <https://doi.org/10.1111/eve.13919>
53. May, S. R. (1991). The effects of biological wound dressings on the healing process. *Clinical materials*, 8(3-4), 243-249. [https://doi.org/10.1016/0267-6605\(91\)90037-g](https://doi.org/10.1016/0267-6605(91)90037-g)
54. Morán, J. M., Kretzschmar, B. H., & Lepage, O. M. (2007). The use of calcium sulphate (plaster of Paris) in a two step surgery for the treatment of a facial fracture in a foal. *Equine Veterinary Education*, 19(7), 370-373. DOI:[10.2746/095777307X218905](https://doi.org/10.2746/095777307X218905).

55. Nesse LL, O. A., Vestby LK. (2023). The role of biofilms in the pathogenesis of animal bacterial infections. *Microorganisms*, 11(3), 608. doi:<https://doi.org/10.3390/microorganisms11030608>
56. Peterson LC, Kim SE, Lewis DD, Johnson MD, Ferrigno CRA.(2021).Calcium sulfate antibiotic-impregnated bead implantation for deep surgical site infection associated with orthopedic surgery in small animals. *Veterinary Surgery* ;50: 748–757. <https://doi.org/10.1111/vsu.13570>
57. Orsini, J. A., Elce, Y. A., & Kraus, B. (2016). Management of severely infected wounds. *Equine wound management* (pp. 449-475) doi:10.1002/9781118999219.ch19
58. Oropallo, A., & Andersen, C. A. (2023). Topical Oxygen. In *StatPearls*. StatPearls Publishing.
59. Ribeiro, G., Carvalho, L., Borges, J., & Prazeres, J. (2024). The Best Protocol to Treat Equine Skin Wounds by Second Intention Healing: A Scoping Review of the Literature. *Animals : an open access journal from MDPI*, 14(10), 1500. <https://doi.org/10.3390/ani14101500>
60. Rivera,P. (2023) Tratamientos de heridas mediante la aplicación de yesos.AVEE.
61. Schumacher, J., & Hanselka, D. V. (1989). Skin grafting of the horse. *Veterinary Clinics of North America: Equine Practice*, 5(3), 591-614. [https://doi.org/10.1016/s0749-0739\(17\)30577-1](https://doi.org/10.1016/s0749-0739(17)30577-1)
62. Schwartz, A. J., Wilson, D. A., Keegan, K. G., Ganjam, V. K., Sun, Y., Weber, K. T., & Zhang, J. (2002). Factors regulating collagen synthesis and degradation during second-intention healing of wounds in the thoracic region and the distal aspect of the forelimb of horses. *American journal of veterinary research*, 63(11), 1564-1570. <https://doi.org/10.2460/ajvr.2002.63.1564>
63. Seid, A. M., & Birhan, M. (2019). A review on equine wound management and healing process. *Online J.Anim.Feed Res*, 9(2), 68.
64. Shimada, K., Ojima, Y., Ida, Y., & Matsumura, H. (2021). Efficacy of versajet hydrosurgery system in chronic wounds: A systematic review. *International Wound Journal*, 18(3), 269-278. doi:10.1111/iwj.13528
65. Silver, I. A. (1982). Basic physiology of wound healing in the horse. *Equine Veterinary Journal*, 14(1), 7-15. doi:10.1111/j.2042-3306.1982.tb02326.x
66. Stashak, T. S. (2003). Update-wound dressings and other topical wound agents: Parts I & II. DOI:[10.1053/j.ctep.2004.08.006](https://doi.org/10.1053/j.ctep.2004.08.006)
67. Stashak, T. S., Farstvedt, E., & Othic, A. (2004). Update on wound dressings: Indications and best use. *Clinical Techniques in Equine Practice*, 3(2), 148-163. doi:10.1053/j.ctep.2004.08.006
68. Stephanie S. Caston. (2012).Wound Care in Horses.Veterinary Clinics of North America: Equine Practice.Volume 28, Issue 1.Pages 83-100.ISSN 0749-0739. <https://doi.org/10.1016/j.cveq.2012.01.001>.
69. Subramaniam, T., Fauzi, M. B., Lokanathan, Y., & Law, J. X. (2021). The Role of Calcium in Wound Healing. *International journal of molecular sciences*, 22(12), 6486. <https://doi.org/10.3390/ijms22126486>
70. Ted S. Stashak, C. T. (2008). *Equine wound management*. Iowa, USA: Wiley-Blackwell.
71. Theoret, C. L. (2005). The pathophysiology of wound repair. *Veterinary Clinics of North America: Equine Practice*, 21(1), 1-13. doi:10.1016/j.cveq.2004.11.001
72. Theoret, C. (2004). Wound repair in the horse: problems and innovative solutions. <https://doi.org/10.1053/j.ctep.2004.08.010>
73. Theoret, C. L., & Wilmink, J. M. (2013). Aberrant wound healing in the horse: Naturally occurring conditions reminiscent of those observed in man. *Wound Repair and Regeneration*, 21(3), 365-371. doi:10.1111/wrr.12018

74. Theoret, C., & Wilmink, J. M. (2016). Exuberant granulation tissue. *Equine wound management*, 369-384. DOI:[10.1002/9781118999219.ch15](https://doi.org/10.1002/9781118999219.ch15).
75. Thomas, M. V., Puleo, D. A., & Al-Sabbagh, M. (2005). Calcium sulfate: a review. *Journal of long-term effects of medical implants*, 15(6), 599–607. <https://doi.org/10.1615/jlongtermeffmedimplants.v15.i6.30>
76. Wilmink, J. M., & van Weeren, P. R. (2004). Differences in wound healing between horses and ponies: Application of research results to the clinical approach of equine wounds. *Clinical Techniques in Equine Practice*, 3(2), 123-133. doi:10.1053/j.ctep.2004.08.011
77. Wilson, D. A. (2009). 4.3 new and innovative. *Equine Wound Management*, 225.
78. Young, A., & McNaught, C. (2011). The physiology of wound healing. *Surgery (Oxford)*, 29(10), 475-479. doi:10.1016/j.mpsur.2011.06.011