

Long-term functional outcomes of the terrible triad of the elbow

Muñoz-Mahamud E, Estrada JA, Ballesteros JR, Combalia A, Fernández-Valencia JA.

Department of Orthopaedic Surgery and Traumatology. Hospital Clínic. University of Barcelona. Spain.

Abstract

Introduction: The published literature regarding the terrible triad of the elbow has historically shown a high rate of unacceptable outcomes. The objective of the present study was to evaluate the long-term functional outcomes and repercussions in patients who suffered the terrible triad of the elbow.

Material and methods: A retrospective analysis of a prospectively-recruited consecutive series of cases registered from August 2005 to August 2009, involving 27 patients from which 16 complied with inclusion criteria for the study. The mean follow-up period was 8.6 years (range: 6.9 to 10.6). Two different final quality of life evaluation questionnaires were performed by telephone: the EuroQol Five Dimensions Questionnaire (EQ-5D) and the patient answered questionnaire portion of the Liverpool Elbow Score (PAQ-LES).

Results: Fifteen (93.7%) patients were intervened surgically whereas only 1 case was treated conservatively. EQ-5D-rated outcome averaged 0.87 (range: 0.36 to 1) and the PAQ-LES averaged 33.5 (range: 17 to 36). Five (31.2%) presented pain or discomfort, 4 (25.0%) had some kind of difficulties in their daily activity and 3 (18.7%) founded some limitations with their personal hygiene. Only 6 cases (37.5%) declared to be fully asymptomatic.

Conclusion: The terrible triad of the elbow remains a challenging injury that entails the presence of chronic pain and discomfort in almost one third of the cases at a long-term follow-up.

Keywords

Elbow; dislocation; ulna fracture; terrible triad; coronoid fracture.



Introduction

The terrible triad of the elbow remains a challenging injury that consists of a dislocation of the elbow with fractures of the radial head and coronoid process of the ulna. The mechanism of injury usually involves a fall with the arm in semiflexion, supination of the forearm and an elbow in a valgus position (1).

Because of the complexion of this kind of injury, it is usually difficult to treat, with a reserved medium to long-term prognosis (2,3), characterized by joint stiffness and osteoarthritis (4).

Conservative treatment involves prolonged immobilization and has shown poor outcomes, leading to stiffness, instability and early joint osteoarthritis (5).

Open reduction, internal fixation of the fractures and ligament repair is thus the treatment of choice in almost all cases so as to provide elbow stabilization and early motion (1,6).

However, some issues remain controversial regarding the surgical strategy, such as whether and how to repair the anterior elbow capsule and/or the coronoid process fracture, whether to excise or replace complex radial head fractures, whether to repair the medial collateral ligament, and what circumstances should be managed with the placement of an external fixator (7,8). However, until recently reported outcomes have been considered suboptimal based on both objective measurements as well as a wide variety of functional scoring systems (9,10). The objective of this

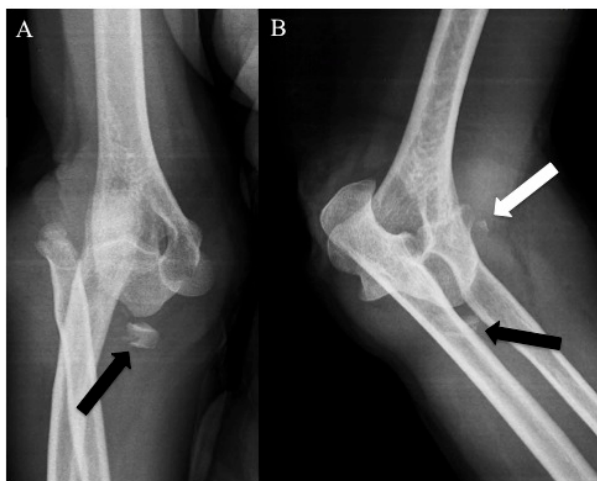


Figure 1. Anteroposterior (A) and lateral (B) radiographs showing a posterolateral dislocation of the right elbow prior to reduction. Fractures of the radial head (black arrows) and the coronoid process of the ulna (white arrow) are depicted.

study was to evaluate the long-term functional outcomes of patients with terrible triad of the elbow.

Material and methods

A retrospective evaluation from a series of cases registered prospectively from August 2005 to August 2009 was performed, involving those patients presenting with a terrible triad of the elbow and that accepted to participate in the study.

The demographics, medical records and comorbidities of the patients were registered.

Two different final quality of life evaluation questionnaires were performed by telephone. The EuroQoL 5D questionnaire or EuroQol Five Dimensions Questionnaire (EQ-5D) was performed, which consists of 5 questions covering health domains of mobility, self-care, usual activity, pain and anxiety/depression (11-14). Each domain has three levels of severity: no problems, some or moderate problems and severe problems. Utility weights can then be attached to the EQ-5D health state provided by the questionnaire. Utility values range from 1 (best possible health), through 0 (death) to -0.59 (worse than death) (15). The algorithm for calculating the EQ-5D index was used in this study (16).

Additionally, patients answered the questionnaire (PAQ) portion of the Liverpool Elbow Score (LES) (17,18), which consists of a 9-item patient-answered questionnaire about the daily function of the elbow during the last four weeks prior to the follow-up. The score ranges from 0 to 36 points, assigning a maximum of 36 points to those painless well functional elbows.

Results

A total of 16 out of 27 patients presenting with a terrible triad of the elbow during the study period were located and accepted to participate in the study. The series included 10 females and 6 males with a mean age of 56 years-old (range: 23 to 82). The mean follow-up period was 8.6 years (range: 6.9 to 10.6).

Fifteen (93.7%) patients were intervened surgically whereas only 1 case was treated conservatively.

According to the Regan-Morrey Classification (19), the coronoid process fractures were classified as: 5 type I, 7 type II and 4 type III (Figure 1). In reference with their management, 8 cases were surgically repaired using preloaded suture anchors, 1 case was repaired using nonabsorbable braided surgical suture, 1 case was fixated with a screw and the rest of the cases was not fixed. According to the Broberg-Morrey modification of the Mason classification (20), radial head fractures were classified as: 3 type I, 5 type II, 0 type III and 8 type IV.

Regarding their management, 12 cases were treated with internal fixation using headless compression screws, 1 case underwent radial head excision, 1 case underwent radial head arthroplasty, and 1 case was treated with percutaneous needle fixation (Figure 2). Two cases needed to be reoperated: in 1 case a radial head excision was performed owing to pain and 1 case a radial head prosthesis was implanted owing to elbow instability. The external collateral ligament was repaired using suture anchors in 8 cases (Figure 3).

EuroQol-5D-rated outcome averaged 0.87 (range: 0.36 to 1) and the PAQ portion of the LES averaged 33.5 (range: 17 to 36). According to both scales, the most common symptom turned out to be the pain. The PAQ-LES evidenced pain during the last 4 weeks in 7 patients (43.7%) whereas the EQ-5D revealed chronic pain in 5 cases (31.2%). No patients referred problems

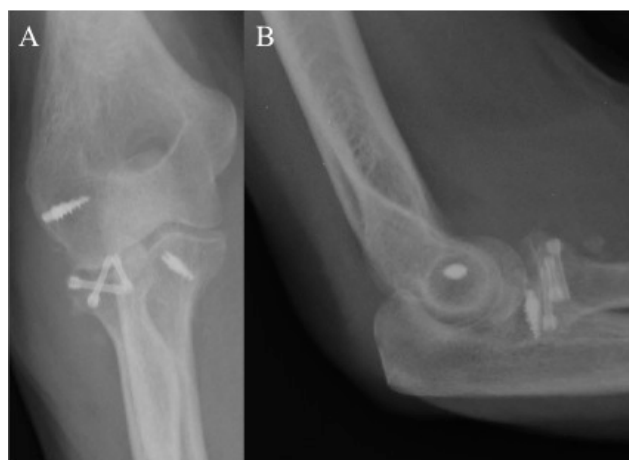


Figure 2. Anteroposterior (A) and lateral (B) postoperative radiographs of the case shown in Figure 1. Radial head was fixated with three low-profile headless compression screws and the both the coronoid process and the collateral ligament were fixated with suture anchors.

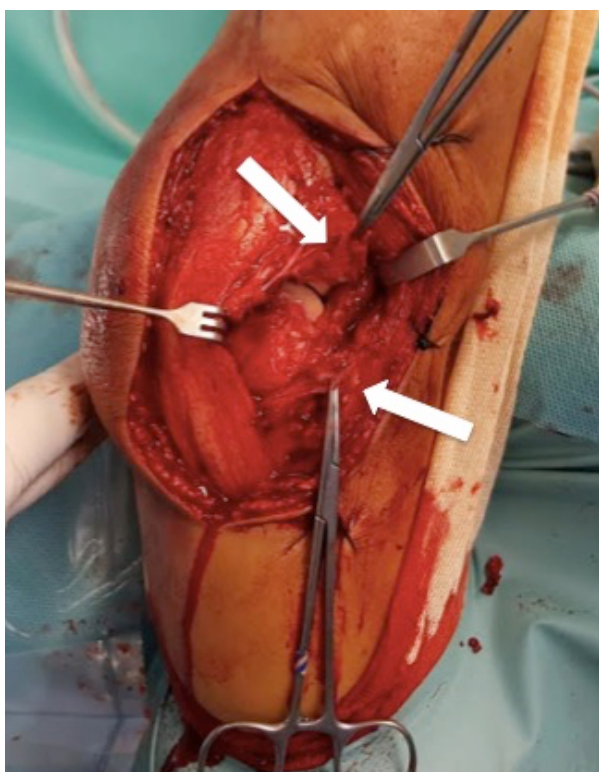


Figure 3. Intraoperative photography showing the torn collateral ligament complex (white arrows).

or difficulty eating but 3 patients (18.7%); they referred some difficulties (2 severe and 1 slight) with daily home tasks. Regarding the personal hygiene, the PAQ-LES stated 2 patients showing some difficulties in the last four weeks, while the EQ-5D, only revealed one patient presenting with slight difficulty with personal hygiene the same day the questionnaire was performed. According to the EQ-5D, 4 patients stated having difficulties (3 slight and 1 moderate) at work, home chores, and hobbies as well as with their everyday life activity.

In all, out of the 16 cases, 5 (31.2%) presented pain or discomfort, 4 (25.0%) had some kind of difficulties in their daily activity and 3 (18.7%) founded some limitations with their personal hygiene. Only 6 cases (37.5%) declared to be fully asymptomatic.

Discussion

The terrible triad of the elbow is a serious and potentially disabling injury that remains challenging. This study consisted on a retrospective review of patients who had sustained a terrible triad of the elbow and report the results, including validated functional outcome measures at a long-term follow-up.

Several studies reporting retrospective series of cases have been recently published in the literature. The mean age of the patients of our series at the time of injury was 56 years old, which remains in concordance

Table 1. Long-term outcomes of the patients included in the series. EQ-5D: EuroQol Five Dimensions Questionnaire. PAQ-LES: Patient-Answered Questionnaire of the Liverpool Elbow Score. F: female. M: male. L: left. R: right.

N	Age	Gender	Side	Dominance	Regan-Morrey	Mason	EQ-5D	PAQ-LES
1	59	F	R	R	I	I	1	34
2	78	M	L	R	II	I	0.78	35
3	58	F	R	R	II	II	0.75	27
4	39	M	L	R	I	II	1	36
5	65	F	R	R	II	IV	1	36
6	27	F	L	R	I	IV	1	36
7	30	M	R	R	II	II	0.71	34
8	80	F	L	R	III	IV	0.74	34
9	73	F	R	R	II	IV	1	35
10	48	M	R	R	III	II	0.87	34
11	61	F	L	R	II	IV	0.87	35
12	23	M	R	L	II	IV	1	36
13	56	F	L	R	I	II	1	36
14	71	M	L	R	III	IV	0.87	35
15	65	F	R	R	III	IV	0.36	17
16	65	F	R	R	I	I	1	36

with other authors (6,9,21,22). Despite existing heterogeneity in reference with the operative approach, it is accepted that the vast majority of these injuries need to be operated in order to properly stabilize the elbow (1,6,9,23,24). However, conservative treatment has been advocated in those selected cases in which the elbow is well aligned and both the coronoid and the radial head fractures are non-displaced and relatively small after closed reduction in absence of mechanical block to motion (25). In our series, only one case was conservatively treated owing to severe comorbidities that contraindicated the surgery at the moment the injury was produced.

Whether and how to repair the coronoid process is still a matter of controversy. Most of the authors reconstruct it depending on the fracture pattern and the stability of the elbow, whereas some others recommend its reconstruction independently of the type of the fracture [6,26]. Several different techniques have been advocated so as to repair the coronoid process, such as suture fixation, screw fixation, suture anchors, a lasso suture technique, plate fixation, fibrin sealant application or resection (1,6-9,23,24,27,28). Since the radial head is a secondary stabilizer of the elbow in valgus stress, its preservation is recommended whenever feasible. However, when facing with a severe comminuted radial head that can not be preserved, then its preferred treatment is the prosthetic replacement (10). Some studies have compared patients with terrible triad injuries whose radial head was treated with either internal fixation or radial head arthroplasty in terms of clinical, functional and radiographic measures, and found no significant differences between both groups (29-31). Since these injuries are commonly related to young patients, it must be ascertained whether the apparent benefits of radial head arthroplasty are jeopardized by late complications, for instance loosening or impingement. In our series, one prosthesis was removed owing to pain secondary to implant overlenghtening.

It is accepted that the stability of the coronoid and repair of the lateral ulnar collateral ligament are the most important factors in overall elbow stability and thus this ligament should be repaired in all cases (7,9,23). However, as the assessment of stability after coronoid and lateral ulnar collateral ligament repair is somehow subjective, there is a wide span of different variations in surgical treatment. After repairing all the structures, the elbow must be tested for stability. To be confident that the elbow is stable, it should be possible to extend the elbow nearly completely without redislocation (32). If appropriate stability is not obtained, a dynamic external fixation should be considered in order to allow early motion in a safe range (21,24,33).

In reference with the functional outcome, we used two different final quality of life evaluation questionnaires that do not include the achieved range of motion (ROM) of the patient. Some studies have compared clinical and functional outcomes concluding that remains discordance between both, existing the

possibility of obtaining good or excellent scores even if there are limitations on pronation and supination (34). In fact, it is not unusual to find good and excellent functional outcomes regardless diminished elbow ROM. This apparent paradox is also notorious when comparing the PAQ portion of LES with the final ROM, suggesting that outcome assessment is possible by postal questionnaire. Thus, it can be assumed that the patient is able to provide reliable and valid judgments of health status and of the benefits of treatment (18). In our series, it is highlighted the fact that almost one third of the cases (31.2%) complained about somehow pain or discomfort after more than 8 years after the injury, 25% of the cases had some kind of trouble in their daily activity and only 37.5% of the cases remained fully asymptomatic. Miyazaki et al. (34) founded that only 26.7% of the results were satisfactory (good or excellent) according to the Bruce functional score. Other authors have reported their functional scores according to the DASH score, reporting scores ranging from 13 to 28 compared with a normative value of 10 (7-9,23,35).

This study has several inherent limitations. Most importantly, because of its retrospective nature, certain biases might have influenced the results. However, much of the data analyzed is unlikely to be affected by this fact. Also the fact that different surgical approaches were used, that becomes a heterogeneous factor of the study. Another potential limitation of the study has to do with the limited number of cases, which may affect the extent to which our findings can be generalized beyond the specific cases studied. However, we present a prospectively-recruited consecutive series of patients with similar fracture pattern and with a long follow-up, treated by a single surgical team and lastly followed by an independent observer. It can be assumed that further evaluations are needed to replicate the findings in different contexts and surroundings.

Conclusion

The terrible triad of the elbow remains a challenging injury that entails the presence of chronic pain and discomfort in almost one third of the cases at a long-term follow-up. The 25% of the cases present some trouble in their daily activity and only 37.5% of the cases remain totally asymptomatic.

References

1. Ohly NE, Murray IR, Keating JF, Pugh DM, McKee MD. The "terrible triad" of the elbow. *Tech Hand Up Extrem Surg* 2002; 6: 21-9.
2. H L. Lill H, Korner J, Rose T, Hepp P, Verheyden P, Josten C. Fracture-dislocations of the elbow joint-strategy for treatment and results. *Arch Orthop Trauma Surg* 2001; 121:31-7.
3. Hotchkiss RN. Fractures and dislocations of the elbow. In: Rockwood CA, Green DP, Bucholz RW, et al. *Rockwood and Green's fractures in adults*. 4th ed. Philadelphia: Lippincott-Raven 1996: 929-1024.

4. Broberg MA, Morrey BF. Results of treatment of fracture-dislocations of the elbow. *Clin Orthop Relat Res* 1987; 216: 109-19.
5. Gomide LC, Campos DO, Ribeiro de Sá JM, Sousa MR, Carmo TC, Andrada FB. Terrible triad of the elbow: evaluation of the surgical treatment. *Rev Bras Ortop* 2011; 46: 374-9.
6. Brigato RM, Mouraria GG, Kikuta FK, Coelho SP, Cruz MA, Zoppi Filho A. Functional evaluation of patients with surgically treated terrible triad of the elbow. *Acta Ortop Bras* 2015; 23: 138-41
7. Forthman C, Henket M, Ring D. Elbow dislocation with intra-articular fracture: the results of operative treatment without repair of the medial collateral ligament. *J Hand Surg Am* 2007; 32: 1200-9.
8. Egol KA, Immerman I, Paksima N, Tejwani N, Koval KJ. Fracture-dislocation of the elbow functional outcome following treatment with a standardized protocol. *Bull NYU Hosp Jt Dis* 2007; 65: 263-70.
9. Fitzgibbons PG, MD; Louie D, Dyer GS, Blazar P, Earp B. Functional outcomes after fixation of "Terrible Triad" Elbow Fracture Dislocations. *Orthopedics* 2014; 2: 1-7.
10. Ring D, Jupiter JB, Zilberfarb J. Posterior dislocation of the elbow with fractures of the radial head and coronoid. *J Bone Joint Surg Am* 2002; 84: 547-51.
11. Herdman M. La medición de la calidad de vida relacionada con la salud. *Med Clin (Barc)* 2004; 114: 22-5.
12. Badia X, Carné X. La evaluación de la calidad de vida en el contexto del ensayo clínico. *Med Clin (Barc)* 1998; 110: 550-6.
13. Brooks R. EuroQol: the current state of play. *Health Policy* 1996; 37: 53-72.
14. Rabin R, de Charro F. EQ-5D: a measure of health status from the EuroQol Group. *Ann Med* 2001; 33(5): 337-43.
15. Badia X, Schiaffino A, Alonso J, Herdman M. Using the Euro-Qol 5-D in the Catalan general population: feasibility and construct validity. *Qual Life Res* 1998; 7: 311-22.
16. Roset M, Badia X, Benavides A, Herdman M. The validity of the EQ-5D in children with asthma. *Proceedings of the 16th Plenary Meeting of the EuroQol Group. Barcelona: Institut Universitari de Salut Pública de Catalunya* 1999; 13-26.
17. Sathyamoorthy P, Kemp GJ, Rawal A, Rayner V, Frostick SP. Development and validation of an elbow score. *Rheumatology (Oxford)*, 2004; 43:1434-40.
18. Ashmore AM, Gozzard C, Blewitt N. Use of the Liverpool Elbow Score as a postal questionnaire for the assessment of outcome after total elbow arthroplasty. *J Shoulder Elbow Surg* 2007; 16: S55-8.
19. Regan W, Morrey BF. Classification and treatment of coronoid process fractures. *Orthopedics* 1992; 15: 845-8.
20. Morrey BF. *The elbow and its disorders*. Third ed. Philadelphia: WB Saunders 1993; 382-99.
21. Rodriguez-Martin J, Pretell-Mazzini J, Andres-Esteban EM, Larrainzar-Garijo R. Outcomes after terrible triads of the elbow treated with the current surgical protocols. A review. *Int Orthop (SICOT)* 2010; 35:851-60.
22. Giannicola G, Calella P, Piccioli A, Scacchi M, Gumina S. Terrible triad of the elbow: is it still a troublesome injury? *Injury* 2015; 46: S68-76.
23. Bohn K, Ipaktchi K, Livermore M, Cao J, Banegas R. Current Treatment Concepts for "Terrible Triad" Injuries of the Elbow. *Orthopedics* 2014; 37:831-7.
24. Chemama B, Bonneville N, Peter O, Mansat P, Bonneville P. Terrible triad injury of the elbow: how to improve outcomes? *Orthop Traumatol Surg Res* 2010; 96:147-54.
25. Guittou TG, Ring D. Nonsurgically treated terrible triad injuries of the elbow: report of four cases. *J Hand Surg Am* 2010; 35:464-7.
26. Papatheodorou LK, Rubright JH, Heim KA, Weiser RW, Sotereanos DG. Terrible Triad Injuries of the Elbow: Does the Coronoid Always Need to Be Fixed? *Clin Orthop Relat Res* 2014; 472:2084-91.
27. Zhang C, Zhong B, Luo CF. Treatment strategy of terrible triad of the elbow: Experience in Shanghai 6th People's Hospital. *Injury* 2014; 45:942-8.
28. Seijas R, Ares-Rodríguez O, Orellana A, Albareda D, Collado D, Llusa. *J Orthop Surg* 2009; 17:335-9.
29. Gonçalves LBJ, Neto JAS, Correa Filho MRC, de Andrade RP, de Andrade MAP, Gomes AH, et al. Terrible triad of the elbow: influence of radial head treatment. *Rev Bras Ortop* 2014; 49:328-33.
30. Leigh WB, Ball CM. Radial head reconstruction versus replacement in the treatment of terrible triad injuries of the elbow. *J Shoulder Elbow Surg* 2012; 21:1336-41.
31. Watters TS, Garrigues GE, Ring D, Ruch DS. Fixation versus replacement of radial head in terrible triad: is there a difference in elbow stability and prognosis? *Clin Orthop Relat Res* 2014; 472:2128-35.
32. Ring D, Jupiter JB. Fracture-dislocation of the elbow. *J Bone Joint Surg Am* 1998; 80:566-580.
33. Chen NC, Ring D. Terrible Triad Injuries of the Elbow. *J Hand Surg Am* 2015; 40:2297-303.
34. Miyazaki AN, Checchia CS, Fagotti L, Fregonez M, Santos PD, da Silva LA, et al. Evaluation of the results from surgical treatment of the terrible triad of the elbow. *Rev Bras Ortop* 2014; 49:271-8.
35. Zeiders GJ, Patel MK. Management of unstable elbows following complex fracture- dislocations: the "terrible triad" injury. *J Bone Joint Surg Am* 2008; 90:75-84.

Copyright

Copyright © 2018 Muñoz-Mahamud E et al. This is an open access article distributed under the [Creative Commons Attribution License](#), which permits unrestricted use, distribution, and reproduction in any medium, provided the original work is properly cited.

Conflicts of interest statement

The authors certify that they have no affiliations with or involvement in any organisation or entity with any financial interest, or non-financial interest in the subject matter or materials discussed in this manuscript.

Correspondence

Ernesto Muñoz-Mahamud

Department of Orthopaedic Surgery and Department of Human Anatomy and Embriology, Hospital Clínic, Institut d'Investigació August Pi I Sunyer (IDIBAPS), Barcelona, Spain.

Address: C/ Villarroel 170. Barcelona 08036 (Spain).

E-mail: e.munoz.mahamud@gmail.com

Phone: 00+34+932275533 / Fax: 00+34+932279871

How to cite

Muñoz-Mahamud E, Estrada JA, Ballesteros JR, Combalia A, Fernández-Valencia JA. Long-term functional outcomes of the terrible triad of the elbow. Int J Adv Jt Reconstr. 2018; 5(1): 8-13.