

Twenty-five years of research in cardiac imaging in electrophysiology procedures for atrial and ventricular arrhythmias

Antonio Berruezo ^{1*}, Diego Penela ², Beatriz Jáuregui ³,
Carlo de Asmundis ⁴, Giovanni Peretto ⁵, Nassir Marrouche ⁶,
Natalia Trayanova ^{7,8,9}, and Christian de Chillou ¹⁰

¹Arrhythmia Unit, Teknon Medical Centre, Carrer de Vilana, 12, 08022 Barcelona, Spain; ²Arrhythmia Unit, Humanitas Research Hospital, Via Alessandro Manzoni, 56, 20089 Rozzano Milan, Italy; ³Arrhythmia Unit - Miguel Servet University Hospital, P.º de Isabel la Católica, 1-3, 50009 Zaragoza, Spain; ⁴Heart Rhythm Management Centre, Universitair Ziekenhuis Brussel-Vrije Universiteit Brussel, Blvd Général Jacques 137, 1050 Ixelles, Brussels, Belgium; ⁵Arrhythmia Unit, Ospedale San Raffaele Hospital, Via Olgettina, 60, 20132 Milan, Italy; ⁶Department of Cardiology, Tulane University School of Medicine, 1430 Tulane Ave, New Orleans, LA 70112, USA; ⁷Department of Biomedical Engineering, Johns Hopkins University, Baltimore, MD 21218, USA; ⁸Department of Applied Math and Statistics, Johns Hopkins University, Baltimore, MD 21218, USA; ⁹Division of Cardiology, Department of Medicine, Johns Hopkins University, Baltimore, MD 21218, USA; and ¹⁰INSERM IADI U1254, University Hospital Nancy, University of Lorraine, 29 Av. du Maréchal de Lattre de Tassigny, 54000 Nancy, France

Received 14 June 2023; accepted after revision 14 June 2023; online publish-ahead-of-print 25 August 2023

Abstract

Catheter ablation is nowadays considered the treatment of choice for numerous cardiac arrhythmias in different clinical scenarios. Fluoroscopy has traditionally been the primary imaging modality for catheter ablation, providing real-time visualization of catheter navigation. However, its limitations, such as inadequate soft tissue visualization and exposure to ionizing radiation, have prompted the integration of alternative imaging modalities. Over the years, advancements in imaging techniques have played a pivotal role in enhancing the safety, efficacy, and efficiency of catheter ablation procedures. This manuscript aims to explore the utility of imaging, including electroanatomical mapping, cardiac computed tomography, echocardiography, cardiac magnetic resonance, and nuclear cardiology exams, in helping electrophysiology procedures. These techniques enable accurate anatomical guidance, identification of critical structures and substrates, and real-time monitoring of complications, ultimately enhancing procedural safety and success rates. Incorporating advanced imaging technologies into routine clinical practice has the potential to further improve clinical outcomes of catheter ablation procedures and pave the way for more personalized and precise ablation therapies in the future.

Keywords

Imaging • Cardiac computed tomography • Cardiac magnetic resonance • Echocardiography • Electroanatomical mapping • Single-photon-emission computed tomography • Positron emission tomography

Introduction

Supraventricular tachycardia catheter ablation (CA) procedures, in general, are considered low risk interventions and have a high success rate. Electroanatomic mapping (EAM) systems and imaging are both considered not essential to improve safety or outcomes in this setting. However, some re-entrant atrial tachycardias and atrial fibrillation ablation procedures could significantly benefit from using these technologies.

Ventricular arrhythmia (VA) ablation procedures are complex, associated to a non-negligible rate of complications and require expertise and advanced electrophysiologist's skills. They have been commonly performed in high volume centres by highly experienced operators. The VA ablation therapy has evolved tremendously in the last 25 years,

largely associated to a big progress in the understanding of the important role that the fibrotic tissue plays in the development of sustained ventricular tachycardia.¹

Along with great improvement in catheter ablation technologies, cardiac imaging has undergone a great evolution. Different imaging modalities are nowadays considered essential tools to ensure procedure safety, assist in pre-procedure planification and help in catheter ablation guidance. Its usefulness has also been recognized and recommended to identify the VA substrate and improving outcomes in VA consensus document and guidelines.^{2,3} Cardiac imaging implementation in the standard VA management and treatment workup has importantly contributed to the widespread of these complex ablation procedures and to offer VA ablation earlier in the evolution of the disease.

* Corresponding author. Tel: +34932 90 62 00. E-mail address: antonio.berruezo@quironsalud.es

© The Author(s) 2023. Published by Oxford University Press on behalf of the European Society of Cardiology.

This is an Open Access article distributed under the terms of the Creative Commons Attribution-NonCommercial License (<https://creativecommons.org/licenses/by-nc/4.0/>), which permits non-commercial re-use, distribution, and reproduction in any medium, provided the original work is properly cited. For commercial re-use, please contact journals.permissions@oup.com

The role of different imaging modalities in substrate identification, procedure planning and guidance for both, and atrial and ventricular arrhythmias, will be summarized in this issue.

Cardiac imaging for atrial arrhythmias procedures

Electroanatomical mapping

Traditionally, electrophysiological studies and ablation of atrial arrhythmias (AA) have been performed under fluoroscopic guidance, with the consequent⁴ exposure to radiation. The EAM using electroanatomical navigation systems has made it possible to reduce the need for fluoroscopy in atrioventricular nodal re-entrant tachycardia, atrioventricular re-entrant tachycardia, atrial flutter, and atrial fibrillation (AF) ablation procedures^{5–8} without compromising either efficacy or safety.^{6–8}

The EAM permits recording bipolar, unipolar, or multipolar voltages; local activation times, or identifying certain characteristics of the electrograms (EGMs), such as the presence of Complex Fractionated Atrial EGMs, or rotors in AF. Additional information, such as conduction velocity, activation direction, and propagation can be evaluated. Far beyond anatomically based procedures in AF [pulmonary vein isolation (PVI)], functional atrial mapping has gained special relevance, allowing to identify potential—and amenable to ablation—arrhythmogenic substrate outside the PV. An international position paper has recently reviewed all available AF mapping technologies.⁹ Cardiac magnetic resonance (CMR) imaging, cardiac computed tomography (CT), and intracardiac echocardiography (ICE) can be integrated into EAM systems during AF and other complex AA ablation procedures, as Figure 1 shows. This may result in better procedural outcomes and

efficiency, and less fluoroscopy utilization.^{10–14} The CMR atrial tissue fibrosis has been independently associated with the likelihood of recurrent AF,¹⁵ although a CMR fibrosis-guided AF ablation appears to be not superior to a pure PVI-based strategy.¹⁵ Conversely, macro-re-entrant AA after AF ablation may benefit from this CMR-guided strategy.¹⁶ Nonetheless, large discrepancies between CMR fibrosis and low voltage zones (LVZ) may still be found.¹⁷ Atrial anatomy assessment is best obtained from CT images due to their great spatial resolution. The CT-EAM fusion may improve the efficacy of AF ablation procedures, although it still remains a matter of debate.¹⁸ Still, CT can define the cardiac anatomy, included uncommon variants and the atrial wall thickness (WT);¹⁹ and may improve procedural safety: detection of thrombi,²⁰ oesophageal position²¹ coronary disease, etc.

Atrial fibrosis promotes heterogeneous slow conduction, increasing AF vulnerability and the likelihood of AF recurrence.²² The PVI clinical outcomes in persistent AF may be improved when adding a voltage-guided substrate modification approach targeting LVZ.²³ Yet, the presence of LVZ can predict AF recurrences, while there is a bad correlation between the extent of LVZ and the indexed left atrial volume.²⁴ Moreover, the presence of any deceleration zone in sinus rhythm is also an independent predictor of AF recurrence, not always correlated to the presence of LVZ.^{25,26}

Echocardiography

Ultrasound (US) imaging has been increasingly used for electrophysiology (EP) procedures. Pre-, peri-, and post-procedural imaging is critical to improve the procedural safety and success; as a matter of fact, each interventional stage can potentially benefit from real-time visualization of the underlying anatomy, thereby avoiding any anatomical assumptions that may be incorrect and potentially dangerous.

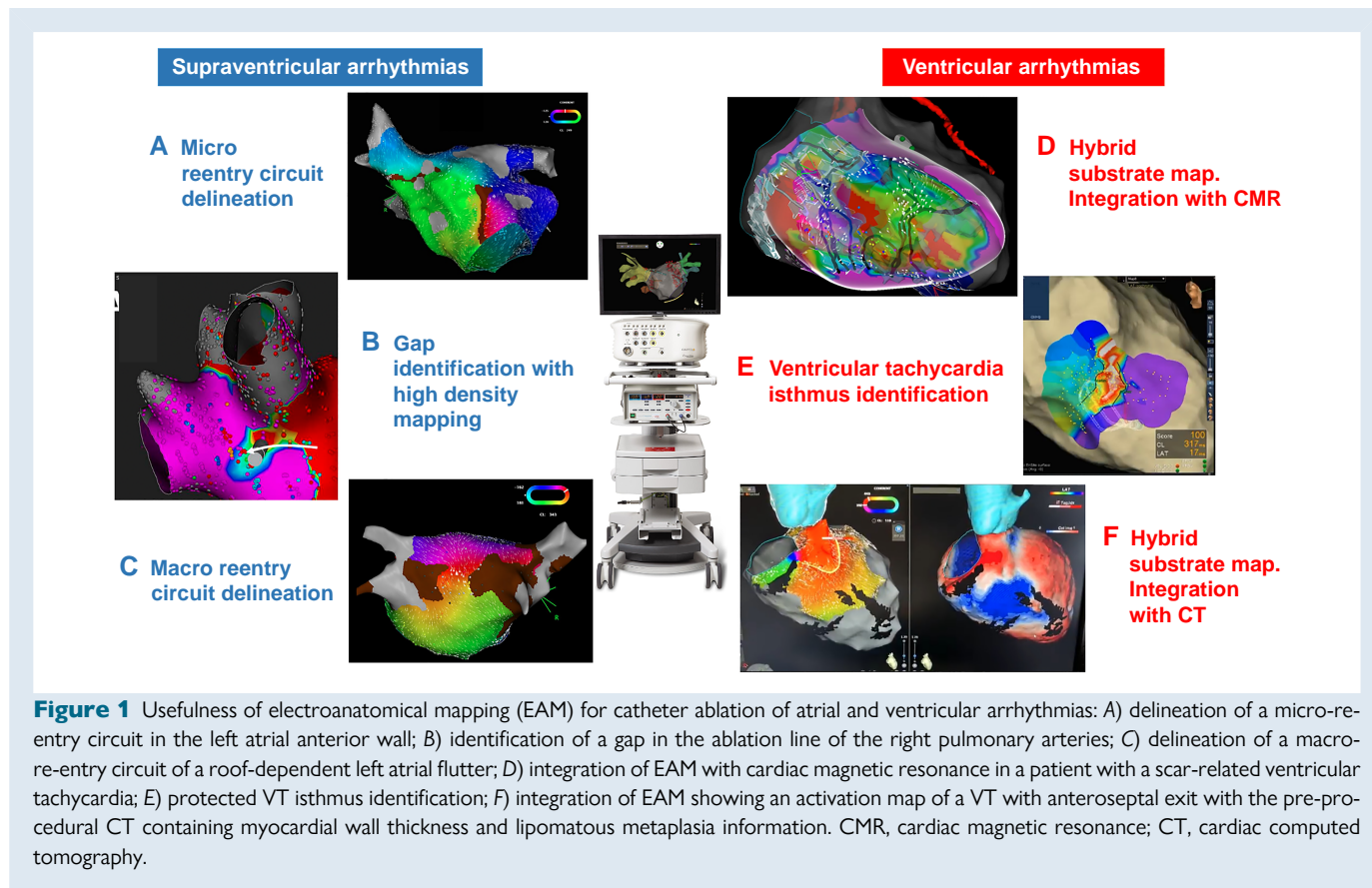


Figure 1 Usefulness of electroanatomical mapping (EAM) for catheter ablation of atrial and ventricular arrhythmias: A) delineation of a micro-re-entrant circuit in the left atrial anterior wall; B) identification of a gap in the ablation line of the right pulmonary arteries; C) delineation of a macro-re-entrant circuit of a roof-dependent left atrial flutter; D) integration of EAM with cardiac magnetic resonance in a patient with a scar-related ventricular tachycardia; E) protected VT isthmus identification; F) integration of EAM showing an activation map of a VT with anteroseptal exit with the pre-procedural CT containing myocardial wall thickness and lipomatous metaplasia information. CMR, cardiac magnetic resonance; CT, cardiac computed tomography.

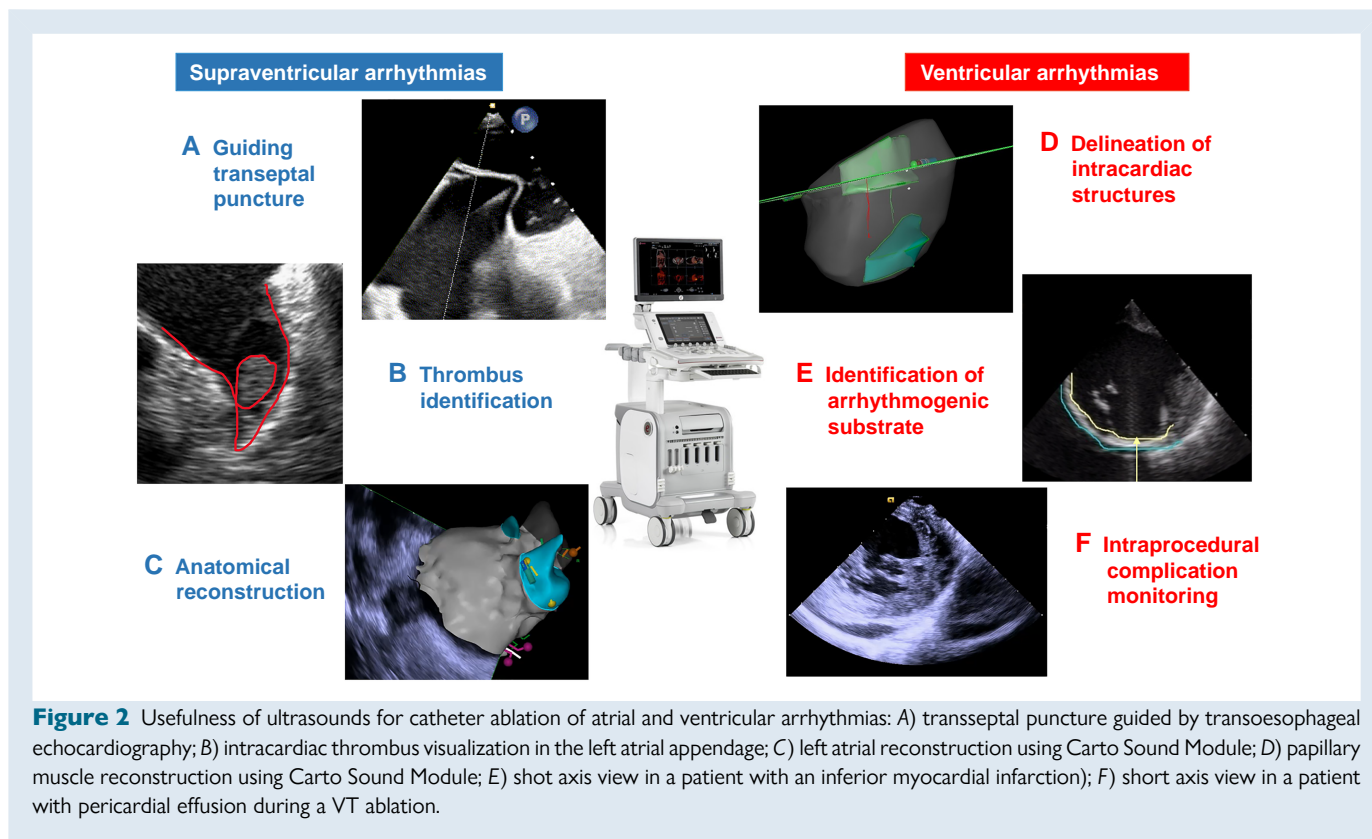


Figure 2 Usefulness of ultrasounds for catheter ablation of atrial and ventricular arrhythmias: A) transeptal puncture guided by transoesophageal echocardiography; B) intracardiac thrombus visualization in the left atrial appendage; C) left atrial reconstruction using Carto Sound Module; D) papillary muscle reconstruction using Carto Sound Module; E) shot axis view in a patient with an inferior myocardial infarction; F) short axis view in a patient with pericardial effusion during a VT ablation.

Conventionally performed via a palpation-based approach, vascular access is the procedural step associated with the highest number of complications, with an incidence ranging between 1% and 13%.^{27–30} The US guidance has been demonstrated to significantly decrease (up to 65%) the risk of major vascular complications compared to an anatomical landmark-based approach. Similarly, this approach may successfully reduce the risk of minor complications (e.g. groin haematoma and inadvertent arterial puncture), thereby promoting a beneficial effect on comorbidities, hospitalization duration, and healthcare expenditure.³¹ The US-guided access may be especially beneficial for EP procedures requiring a large bore access into the femoral vein [e.g. single-shot devices and percutaneous left atrial appendage (LAA) occlusion]^{32–34}; additionally, vascular US has been also adopted to guide vascular closure device deployment.^{35,36}

Transseptal access is another critical step of left-sided EP procedures and can be associated with serious complications (e.g. cardiac tamponade, aortic puncture, and systemic embolism). Transoesophageal echocardiography (TEE) is commonly used to guide septal puncture (Figure 2). The main limitation of TEE is that it relies on a second operator to allow active and cooperative septal visualization optimization while the main operator is focused on manoeuvring the apparatus for transseptal access. The ICE is a valid alternative to TEE for transseptal access, as well as for a wide variety of other uses, as it allows direct, real-time visualization of many cardiac structures that are critical for EP procedures. The ICE currently plays a central role for fluorless ablation procedures.³⁷ One of the most important features of ICE is continuous monitoring and early detection of peri-procedural complications, including steam pops, thrombus formation, and pericardial effusion/tamponade (Figure 2). Another advantage of this technology is the lack of need for general anaesthesia or an additional operator for TEE manoeuvring. The ICE catheter can also be advanced into the left atrium and is also currently used for LAA occlusion guidance; this approach has been demonstrated to

reduce procedural duration and patient turnover.^{38,39} Additionally, novel 3D-ICE probes feature direct anatomical visualization in multi-plane/multislice and 3D modes.^{40,41}

Computed tomography

Computed tomography has undergone significant technical evolution since its inception in the 1970s. This imaging modality has become an increasingly important tool for the non-invasive evaluation of cardiovascular anatomy and function. The evolution of cardiac CT has resulted in improvements in spatial and temporal resolution, image quality, motion artefact reduction, radiation dose reduction, and advanced post-processing techniques. These advancements have made cardiac CT an increasingly valuable tool for helping CA procedures.

Due to its great spatial resolution, cardiac CT provides detailed anatomical information of the atrium, including the size, shape, location of vessels, and their relationship with extracardiac structures (Figure 3). In the setting of PVI, the integration of CT images into the EAM^{42,43} allows visualization of the fossa ovalis⁴⁴ anatomy and identification of unexpected anatomical PV variants,⁴⁵ facilitating procedural planning. This information can be particularly useful during cryoballoon ablation, as PV ostium shape and orientation can predict PV occlusion during the procedure, identifying unfavourable anatomies in which a point-by-point strategy might be more appropriate.⁴⁶

Cardiac CT also allows to obtain information of the left atrial WT, a major determinant of lesion transmuralty.^{19,47} Left atrial WT-guided titration of radiofrequency delivery for paroxysmal and persistent AF ablation has been proved to allow for highly efficient and effective procedures.⁴⁷ Moreover, CT information can be used to increase procedure safety, allowing 3D visualization of the left atrium's relationship with the oesophagus,^{48,49} the left superior pulmonary veins' relationship with the bronchi,⁵⁰ and the distance between the right upper PV and the right pericardiophrenic artery, an indirect marker of the phrenic nerve course.⁵¹

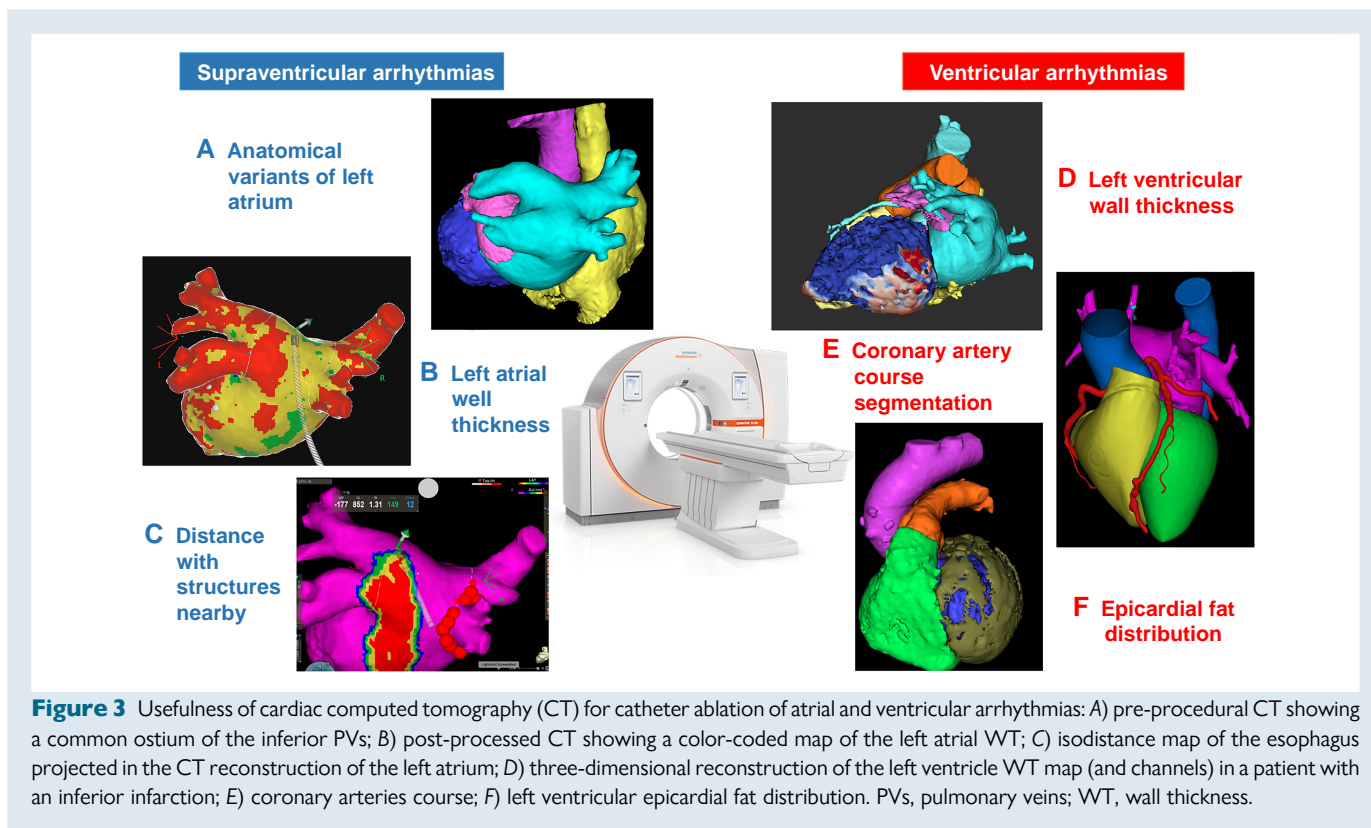


Figure 3 Usefulness of cardiac computed tomography (CT) for catheter ablation of atrial and ventricular arrhythmias: A) pre-procedural CT showing a common ostium of the inferior PVs; B) post-processed CT showing a color-coded map of the left atrial WT; C) isodistance map of the esophagus projected in the CT reconstruction of the left atrium; D) three-dimensional reconstruction of the left ventricle WT map (and channels) in a patient with an inferior infarction; E) coronary arteries course; F) left ventricular epicardial fat distribution. PVs, pulmonary veins; WT, wall thickness.

All this information allows us to move towards a personalized ablation strategy based on the patient's specific anatomy, preventing injury to sensible extracardiac structures during ablation. Cardiac CT also plays a major role in post-procedural handling, as it is the gold standard for verification of different complication diagnoses, such as the atrio-oesophageal fistula⁵² or PV stenosis. Although initially designed for atrial fibrillation ablation, CT-image integration into the EAM may also improve the efficacy of CA in other complex atrial arrhythmic substrates. The use of CT scans may help to identify the origin of atrial ectopic focus.⁵³ Moreover, cardiac CT provides detailed information to properly select the course of the linear ablation lesions in patients with left⁵⁴ or right⁵⁵ atrial macro-re-entrant circuits. Conversely, left atrial WT maps have shown to be helpful in visualizing previous linear ablations and gaps, facilitating activation map interpretation in left atrial flutters.

Cardiac magnetic resonance

Pre-ablation cavotricuspid isthmus (CTI) visualization has gained significant attention in recent years with the development of the CMR-EP system.⁵⁶ This innovative technique allows for high-resolution visualization of the anatomy, substrate, and ablation lesions without the need for fluoroscopy, making it particularly useful in procedures requiring detailed anatomical visualization like CTI ablation.⁵⁶ This can lead to a reduction in radiation exposure for both the patient and the operator.

The use of real-time CMR, if translated to AF procedures, could be immensely beneficial. The prevalence and health burden of AF are much higher than atrial flutter, and there is a need to further improve procedural management of AF.

The use of CMR in the management of AF has a lot of benefits. For instance, it has been previously demonstrated that CMR can be used to assess underlying disease tissue or atrial fibrosis, as Figure 4 shows.⁵⁷ These increasing levels of atrial fibrosis were independently linked to

hard clinical outcomes like major cerebrovascular and cardiovascular events.⁵⁸ Also, the extent of disease in the left atrium has been shown to be a significant predictor of recurrence after CA. This was proved in the multicenter DECAAF I study, where patients were divided into four different groups of atrial fibrosis with high discrepancies in outcomes depending on the quantity of fibrosis.¹⁵

A sub-analysis of this study by Akoum *et al.*⁵⁹ showed that covering more fibrosis by ablation lesions can lead to fewer recurrences after the procedure. The DECAAF II trial was designed to prospectively test this hypothesis. So, patients were randomly assigned to receive either PVI-only or PVI plus fibrosis-guided ablation. However, the study results showed no significant differences between the two arms.⁶⁰

Nonetheless, the application of CMR remains valuable, especially pre- and post-procedures. As mentioned earlier, the evaluation of baseline left atrial fibrosis provides valuable prognostic information for patients after the procedure. Additionally, the evaluation of the distance between the atrium and the oesophagus is a critical determinant of oesophageal injury due to CA.^{61,62} Therefore, getting an image before the ablation can guide us on efficacy and safety outcomes. On the other hand, post-procedural CMR can also help guide redo ablations. Studies have shown that using CMR to guide redo ablations can lead to shorter procedural time and lower chances of recurrence.⁶³

Positron emission tomography-scan and single-photon-emission computed tomography-scan

Nuclear cardiology exams (NCEs), namely single-photon-emission computed tomography (SPECT) and positron emission tomography (PET), constitute relevant imaging tools for cardiovascular diseases. To date, the main clinical applications of NCEs involve myocardial ischaemia, ranging from coronary artery disease (CAD) to coronary

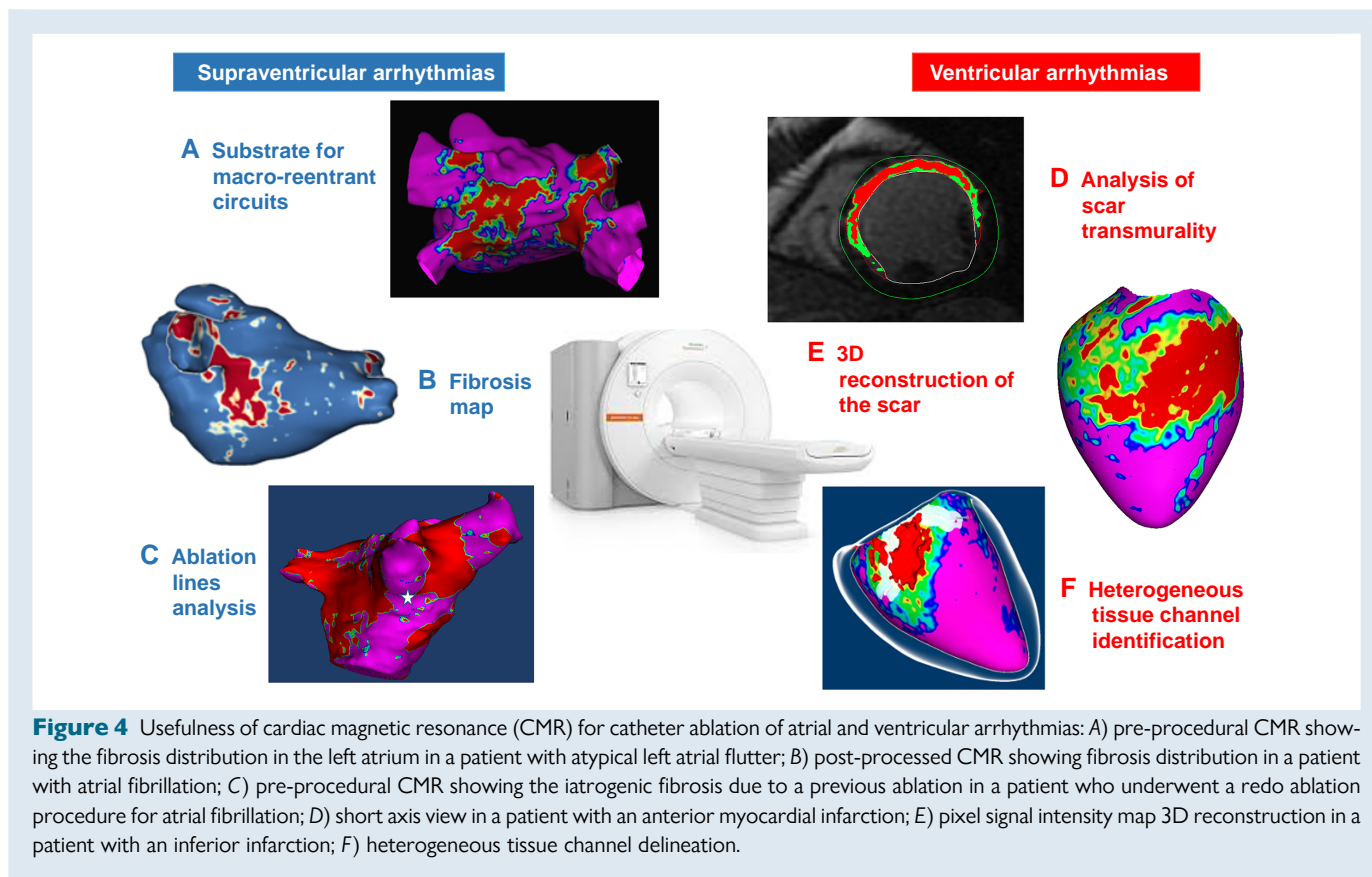


Figure 4 Usefulness of cardiac magnetic resonance (CMR) for catheter ablation of atrial and ventricular arrhythmias: A) pre-procedural CMR showing the fibrosis distribution in the left atrium in a patient with atypical left atrial flutter; B) post-processed CMR showing fibrosis distribution in a patient with atrial fibrillation; C) pre-procedural CMR showing the iatrogenic fibrosis due to a previous ablation in a patient who underwent a redo ablation procedure for atrial fibrillation; D) short axis view in a patient with an anterior myocardial infarction; E) pixel signal intensity map 3D reconstruction in a patient with an inferior infarction; F) heterogeneous tissue channel delineation.

microvascular dysfunction.⁶⁴ In detail, while stress/rest SPECT can identify ischaemic and necrotic areas, specific tracers in PET scan allow investigation of myocardial metabolism (18F-FDG-PET), and quantitative measurement of myocardial perfusion (H215O-PET or 13N-PET).⁶⁴

To date, the clinical role of NCEs in cardiac arrhythmias is still limited. In fact, CMR and CT scan constitute the gold standard for substrate characterization and morpho-functional assessment of most myocardial diseases.³ In selected cases, however, NCEs can provide significant information to guide diagnosis, prognostic assessment, and treatment strategies for patients with arrhythmias.

Among supraventricular arrhythmias, NCEs have been mainly applied to AF. For instance, 99mTc-MIBI SPECT perfusion imaging has been proposed to identify CAD as a substrate for unexplained AF.⁶⁵ In the setting of AF, however, the diagnostic value of SPECT has recently shown a low predictive value for CAD.⁶⁶ In fact, fast and irregular heartbeat may frequently account for poor image quality and subsequent inaccuracy in assessing ischaemia-induced regional wall motion abnormalities.⁶⁷ Instead, quantitative data from perfusion PET have shown that, even in the absence of epicardial CAD, myocardial blood flow and coronary flow reserve are abnormal in patients with persistent AF.⁶⁸ These data suggest that coronary microvascular dysfunction may be the consequence rather than the cause of AF,⁶⁸ and deserve further investigation by future studies.

NCEs have been employed also to characterize supraventricular arrhythmogenic substrates before CA. In one study,⁶⁹ SPECT was used in combination with other imaging techniques to identify atrial cardiomyopathy in young patients undergoing CA of atrial tachycardia. More recently, hybrid 99mTc-Pyrophosphate SPECT/CT has been proposed to detect latent inflammatory processes in patients with AF and biopsy-proven myocarditis.⁷⁰ Overall, these data indicate that an improved detection of atrial scars and inflammation may help identifying non-

responders to CA, even in the absence of significant left atrial dilation.³ Finally, a role for I-123-Metaiodobenzylguanidine SPECT imaging has been suggested to investigate dysautonomic manifestations in patients with AF undergoing CA.⁷¹ Again, the clinical value of NCEs in defining suitable ablation targets and in predicting procedural outcomes is still to be proved.

Cardiac imaging for ventricular arrhythmias procedures

Electroanatomical mapping

The advent of 3D-EAM systems in the late 1990s clearly marked a major historical turning point for cardiac EP, particularly with respect to CA of VA in patients with structural heart disease.⁷²

The 3D-EAM systems combine three important⁷² features: (i) real-time visualization of catheters without the use of X-rays, (ii) 3D display of the virtual anatomy of heart chambers in relation to local EGM data, and (iii) fusion with non-invasive images of the heart (ICE, CT scan, CMR...). The 3D-EAM systems, which are very effective to reduce patient and staff exposure to fluoroscopy,⁷³ are currently widely used in daily practice for all types of CA procedures⁷⁴ in particular in over 90% of all ventricular tachycardia (VT) ablation procedures.^{75,76}

With respect to VT ablation, one of the key innovative features of 3D-EAM systems was, for the first time, the complete virtual visualization of VT circuits through complete endocardial activation maps of the ventricles,^{77,78} thus, allowing an accurate characterization of critical VT isthmuses, including not only their dimensions but also the elements that form their lateral boundaries (see [Supplementary material online, Video](#)).

The presence of slow conduction zones related to myocardial scars of various aetiologies (post-infarction, post-myocarditis...) is the pathophysiological substrate for macro-re-entry, which is the predominant mechanism of VT in patients with structural heart disease. Such scars harbour local abnormal ventricular activities (so-called LAVAs) in terms of voltage, duration, and morphology (i.e. split/fractionated EGM, late potentials...). Cross-correlation studies with CMR,^{79,80} histology,⁸¹ and VT mapping⁷⁹ have shown the accuracy of bipolar/unipolar voltage mapping in unmasking scars, with unipolar voltage mapping being more appropriate to detect intramural scars⁸² and possibly diffuse fibrosis that cannot be easily imaged by CMR.⁸³

Because many VTs are poorly tolerated, which impedes VT mapping,⁸⁴ substrate-based VT ablation that circumvents this issue, by targeting LAVAs, has early become very popular.⁷⁵ LAVAs related to VT circuits⁸⁵ can be directly⁸⁶ or indirectly⁸⁷ identified during 3D-EAM. Areas harbouring slow conduction can also be unveiled by pace-mapping⁸⁸ or by pacing with double ventricular extrastimuli.⁸⁷

In patients with structural heart disease, a recent meta-analysis of the literature⁸⁹ showed that substrate-based ablation (aimed at modifying the substrate) was associated with better outcomes than 'standard' ablation (aimed at ablating stable VT) for the combined endpoint of VA recurrence and all-cause mortality.

Merging 3D-EAM maps with other cardiac imaging modalities is very useful when planning VT ablation procedures. Thus, ICE is a key exam to visualize papillary muscles that can hardly be outlined by 3D-EAM systems. The CT scan and CMR⁹⁰ are also important tools for the identification of ventricular arrhythmogenic substrate in patients with structural heart disease, with VT channels meandering through scars highlighted by a dedicated software applied to CMR.⁹¹

Echocardiography

The role of ultrasound assessment in VAs procedures is wide and includes the following tools: transthoracic echocardiography, TEE, and ICE.

Transthoracic echocardiography is useful in pre-procedural planning to evaluate the patient risk of VAs and to rule out left ventricle thrombus (contrast echocardiography may be considered in this case).⁹² Global function of the left ventricle should be assessed with left ventricular ejection fraction (LVEF). The LVEF is a parameter integrated in the current risk stratification for pre-procedural mechanical support, besides its role as a known marker of VAs risk.⁹³ However, the absolute number of sudden cardiac death (SCD) victims is higher in the group of patients with LVEF >50%.⁹⁴ For this reason, a mildly reduced or normal LVEF should not be used to rule out VAs. If a patient is planned for a VT ablation, regional function evaluation by transthoracic echocardiography is useful to guide towards the scar area, in case of a suspected scar-dependent VT.² On the other hand, if a patient is evaluated for a premature ventricular contraction (PVC) ablation, transthoracic echocardiography can predict the recovery of LVEF in case of suspected PVC-induced cardiomyopathy. In a seminal study by Penela et al.,⁹⁵ an LV end-diastolic diameter >63 mm identified patients who will not normalize LVEF after PVC ablation.

Transthoracic echocardiography or TEE or ICE should be always available in the EP lab during VA ablation to rule out pericardial puncture/bleeding.² Indeed, PVC ablation is associated with a 2% complication rate, with pericardial effusion being the most frequent (40% of total complications).⁹⁶ Furthermore, during epicardial procedures with unintended puncture of the right ventricle can occur in up to 17% of cases.²

The TEE or ICE can be used to guide transeptal puncture. Being the LV with an inferior and anterior structure compared to the septum, the preferred position for the transeptal access should be the antero-inferior portion of interatrial septum.

Finally, ICE is recommended to localize the ostia of the coronary arteries prior to ablation in the sinuses of Valsalva.² It is also beneficial to

identify and target the papillary muscles with ablation and to assess for catheter stability.⁹⁷ In particular, ICE allows a direct visualization of the papillary muscle during mapping and helps to correctly identify the anatomical site of the arrhythmogenic focus; during CA, it confirms contact between the ablation catheter and the target, avoiding collateral damage to surrounding anatomical structures (mitral valve chordae and leaflets).⁹⁸ It may be useful, during the procedure, as an adjuvant technique to identify wall segments with wall thinning, wall motion abnormalities, and segments with increased echogenicity, and also to identify intracardiac thrombi.²

Computed tomography

Several studies have demonstrated the potential of cardiac CT for pre-procedural planning in VT ablation. Wall thickness assessment using cardiac CT has recently emerged as an alternative cardiac imaging method to characterize arrhythmogenic substrate before VT ablation procedures,⁹⁹ showing a good correlation with low voltage areas and LAVAs.¹⁰⁰ Ghannam et al.¹⁰¹ described that WT correctly identify the ablation targets in a population of post-infarction patients who underwent VT ablation. However, compared to CMR, cardiac CT presents a lower contrast-to-noise ratio, a characteristic that reduces the cardiac CT capability for scar characterization. As consequences, CT may not accurately identify non-transmural areas of myocardial scar, especially in cases where the scar is in the sub-endocardium in ischaemic patients.⁹⁰ In patients with non-ischaemic cardiomyopathy, who typically do not show myocardial thinning in scarred areas, the usefulness of CT may be also inferior compared to CMR.

The other side of the coin is the high spatial resolution of CT. While CMR spatial resolution usually ranges from 1.4 to 2 mm, CT spatial resolution is typically close to 0.5 mm. This results in better identification of the coronary arteries, phrenic nerve, and epicardial fat distribution^{102,103} (Figure 3). Yamashita et al.¹⁰⁴ previously showed how the integration of cardiac CT during epicardial VT ablation can increase the safety of the procedure avoiding radiofrequency delivery in the very proximity of these structures. Furthermore, cardiac CT can easily identify lipomatous metaplasia, which facilitates the propensity of re-entry VT circuits in healed myocardial infarction.¹⁰⁵ Moreover, CT identifies intracardiac thrombus, which can be present in up to 11% of patients referred for scar-related VT-CA, as recently reported.¹⁰⁶ Finally, cardiac CT can be useful in the setting of PVC ablation. First, it can help to identify the site of origin in patients with outflow-tract PVCs by analysing the presence of anatomical modifications due to chronic overload.¹⁰⁷ Moreover, CT imaging integration into the EAM can be useful for aiding ablation procedures of PVC originating from complex intracardiac structures, such as the papillary muscles¹⁰⁸ for the aortic cusps.

The use of cardiac CT has shown to be a valuable tool in assisting CA of VA and can be easily integrated into the procedure workflow. However, it is important to carefully consider the potential limitations of the technique, such as limited soft tissue contrast and the risk of radiation exposure, particularly in patients requiring multiple scans.

Cardiac magnetic resonance

Fibrotic tissue has been recognized to be the main substrate for VA, is present in various degrees even in the case of a focal origin, and supports re-entry circuits. Contrast-enhanced CMR has proved its capacity to identify with high precision this scarred tissue, which confers an increased arrhythmia susceptibility.¹ Scar identification and quantification have demonstrated to help identify those patients at higher risk for VA in both ischaemic and non-ischaemic cardiomyopathies in various clinical scenarios, in a significant number of studies.¹⁰⁹⁻¹¹¹

The identification of myocardial scar and its distribution pattern through the myocardial WT has been shown to be of help to focus mapping and ablation on the area of interest and also to decide the

endocardial approach vs. epicardial approach for free wall VTs or the right access vs. left access for septal scar-related VTs.¹¹²

The CMR also permits to differentiate between dense non-excitabile scar and border zone fibrotic tissue surrounding the scar or creating channels through the scar or between the scar and an anatomical obstacle like a valve annulus. These channels can be identified using dedicated software for CMR post-processing.⁹¹ The capacity of CMR to identify these channels is superior to that of the CT, the latter failing to detect the presence of arrhythmogenic substrate in one-third of patients with subendocardial myocardial infarction. However, the performance of CT improves in the presence of transmural scars.⁹⁰ A significant number of patients undergoing VT ablation have implantable cardioverter-defibrillator (ICD) that can cause image artefacts in CMR. In those patients, wideband CMR sequences have shown to decrease these artefacts while maintaining similar accuracy for substrate characterization.¹¹³

The presence of channels and the border zone channel mass has been shown to be the strongest determinant of VA occurrence after a myocardial infarction after adjustment for other variables related with the LV function and scar.¹¹⁴ These channels also distinguish patients at higher risk of VTs during follow-up in other clinical situations like cardiac resynchronization therapy and even in non-ischaemic cardiomyopathy.^{109,111,115}

The 3D reconstruction of the information obtained with the CMR displaying the heart anatomy, the scar, and the 3D structure of the conducting channels can be imported into the navigation system and integrated with the EAM. The CMR scar and channels have been shown to have a good correlation with the low voltage areas and channels identified with EAM.^{80,116} The CMR allows to recognize the substrate architecture and distribution along the VT, otherwise, neither visible nor mappable with standard mapping and ablation catheters that only obtain direct information from the endocardial or epicardial surface.^{79,80,116} The use of the information provided by the CMR once integrated into the navigation system has demonstrated to help performing more efficient procedures and obtain better outcomes. As compared with the standard VT ablation guided solely by the EAM, CMR-guided VT ablation is feasible and safe, significantly reduces the procedural, fluoroscopy, and radiofrequency times, and is associated to a higher non-inducibility rate and lower VT recurrence.^{117,118}

Positron emission tomography-scan and single-photon-emission computed tomography-scan

In patients with VA, the applications of NCEs are wider and encompass ischaemic and non-ischaemic diseases. In patients with mid-to-high pre-test probability of CAD and stress-induced ectopies from the LV, SPECT can predict epicardial vessel stenosis, even in the absence of LV systolic dysfunction.¹¹⁹ Nonetheless, NCEs are not currently recommended by the ESC in the diagnostic workup of CAD-related VA.³ Instead, FDG-PET has a recognized role in diagnosing both cardiac and extracardiac sarcoidosis.³ In addition, FDG-PET scan has been proved clinically helpful in lymphocytic myocarditis with VA, in particular when CMR is contraindicated or unsuitable due to ICD-related artefacts.¹²⁰ Finally, recent studies suggested that FDG-PET is capable of identifying even the 'hot-phases' of primary cardiomyopathies of the dilated and arrhythmogenic spectrum.¹²¹

Beyond their diagnostic value, NCEs have shown a prognostic role in CAD,^{65,122} as well as in other clinical scenarios. For instance, 99mTc-MIBI myocardial perfusion SPECT has been found useful to quantify LV scarring, and predicts outcomes in response to cardiac resynchronization therapy.¹²² Consistently, the beneficial effects of biven-tricular pacing on septal metabolism can be proved by PET.¹²³

In patients with inflammatory cardiomyopathy, the anteroseptal localization of FDG-PET abnormalities, more commonly found in cardiac sarcoidosis rather than classic lymphocytic myocarditis, is capable of predicting worse arrhythmic outcomes.¹²⁰ In inflammatory cardiomyopathy, the documentation of active myocarditis by multimodal work-up including FDG-PET has shown to predict major VA recurrences even after CA.¹²⁴

In light of their diagnostic role, NCEs have been investigated also to guide treatment strategies, such as CA of VA. For instance, SPECT-CT fusion imaging has been found time-sparing and useful to characterize LV substrate and scars.¹²⁵ In addition, areas with perfusion/innervation mismatch on SPECT scans could identify sites of LAVA on EAM to guide CA procedures.¹²⁶ Due to the lack of strong evidence, however, NCEs are not mentioned by the last ESC guidelines among the imaging tools recommended before CA procedures in patients with VA.^{2,3} Exception is made for PET-CT scan in patients with inflammatory heart diseases like myocarditis or cardiac sarcoidosis,³ who will likely benefit also from PET-CMR fusion imaging in the near future.¹²⁷ Finally, in the absence of artefacts from right ventricular pacing,¹²⁸ FDG-PET may find application in following-up ICD carriers with myocarditis, to allow disease restaging and guide the withdrawal of immunosuppressive therapies.¹²⁰

Future directions

The future of cardiac imaging in arrhythmia and EP will be shaped by advances in technology and a greater understanding of the underlying arrhythmia mechanisms. Progress in these directions will be intertwined, leading to improved patient outcomes and increased efficiency of healthcare delivery.

A clearly charted direction would be the use of 3D imaging technologies, which are expected to become widespread, improving our ability to acquire unappreciated structural and disease-induced remodelling detail. Native T1 mapping and extracellular volume acquisition are making inroads, allowing to better characterize diffuse fibrosis.¹²⁹ Furthermore, fusion imaging, the integration of multiple imaging modalities, will enrich our ability to assess disease-modified heart structure/function. Indeed, hybrid PET/CMR scanners have already become commercially available¹³⁰; the trend of fusion imaging will continue to grow.

Development of real-time imaging technologies will allow feedback during EP procedures. For instance, ICE, a high-resolution visualization of cardiac structures, enables integration of real-time images with EAM. Novel developments, such as electromechanical wave imaging, a high-frame rate ultrasound technique,¹³¹ have made initial advances in non-invasively mapping the electromechanical activation of arrhythmias. Furthermore, while commercial systems for electrocardiographic imaging already exist, they do not yet have the spatial resolution necessary to clearly delineate targets for ablation; improved approaches are likely to be developed in near future.

The most rapid advances in technology will likely be made by artificial intelligence (AI). In addition to its widening use in electrocardiogram (ECG) analysis,¹³² AI has also been used in segmentation, scar/fibrosis assessment, and clinical parameter extraction.¹³³ We are witnessing the first application of deep learning on raw CMRs and the use of multi-modality deep learning to predict risk of arrhythmia and time to SCD.¹³⁴ Future AI advances will enable identification of additional imaging patterns and biomarkers that are associated with specific types of arrhythmias.

Finally, digital twin technology is poised to play important role in personalized treatment planning and in prognostication of patients' disease trajectory. Heart digital twins (mechanistically-based personalized computational models of patients' hearts) have already made novel contributions to uncovering arrhythmogenic mechanisms¹³⁵ and to the guidance of atrial¹³⁶ and VAs.¹³⁷ The benefit of the digital twin technology is that treatment can be tailored based on the patient's response to

therapy. The AI is also being combined with digital twins,¹³⁸ helping broaden clinical data inclusion in the models. In the future, we will witness the creation of continuously-adjustable heart digital twins based on patients' tracked data.

Supplementary material

Supplementary material is available at *Europace* online.

Conflict of interest: None declared.

References

- Schmidt A, Azevedo CF, Cheng A, Gupta SN, Bluemke DA, Foo TK et al. Infarct tissue heterogeneity by magnetic resonance imaging identifies enhanced cardiac arrhythmia susceptibility in patients with left ventricular dysfunction. *Circulation* 2007;**115**: 2006–14.
- Cronin EM, Bogun FM, Maury P, Peichl P, Chen M, Nambodiri N et al. 2019 HRS/EHRA/APHS/LAHS expert consensus statement on catheter ablation of ventricular arrhythmias. *Europace* 2019;**21**:1143–4.
- Zeppenfeld K, Tfelt-Hansen J, de Riva M, Winkel BG, Behr ER, Blom NA et al. 2022 ESC guidelines for the management of patients with ventricular arrhythmias and the prevention of sudden cardiac death. *Eur Heart J* 2022;**43**:3997–4126.
- Estner HL, Bongioni MG, Chen J, Dagues N, Hernandez-Madrid A, Blomström-Lundqvist C et al. Use of fluoroscopy in clinical electrophysiology in Europe: results of the European Heart Rhythm Association survey. *Europace* 2015; **17**:1149–52.
- Earley MJ, Showkathali R, Alzetani M, Kistler PM, Gupta D, Abrams DJ et al. Radiofrequency ablation of arrhythmias guided by non-fluoroscopic catheter location: a prospective randomized trial. *Eur Heart J* 2006;**27**:1223–9.
- Casella M, Dello Russo A, Pelargonio G, Del Greco M, Zingarini G, Piacenti M et al. Near zero fluoroscopic exposure during catheter ablation of supraventricular arrhythmias: the NO-PARTY multicentre randomized trial. *Europace* 2016;**18**: 1565–72.
- Chen G, Wang Y, Proietti R, Wang X, Ouyang F, Ma CS et al. Zero-fluoroscopy approach for ablation of supraventricular tachycardia using the Ensite NavX system: a multicenter experience. *BMC Cardiovasc Disord* 2020;**20**:48.
- Falasconi G, Penela D, Soto-Iglesias D, Jáuregui B, Chauca A, Antonio RS et al. A standardized stepwise zero-fluoroscopy approach with transesophageal echocardiography guidance for atrial fibrillation ablation. *J Interv Card Electrophysiol* 2022;**64**: 629–39.
- de Groot NMS, Shah D, Boyle PM, Anter E, Clifford GD, Deisenhofer I et al. Critical appraisal of technologies to assess electrical activity during atrial fibrillation: a position paper from the European Heart Rhythm Association and European Society of Cardiology working group on eCardiology in collaboration with the Heart Rhythm Society, Asia Pacific Heart Rhythm Society, Latin American Heart Rhythm Society and Computing in Cardiology. *Europace* 2022;**24**:313–30.
- Scaglione M, Caponi D, Di Donna P, Riccardi R, Bocchiardo M, Azzaro G et al. Typical atrial flutter ablation outcome: correlation with isthmus anatomy using intracardiac echo 3D reconstruction. *Europace* 2004;**6**:407–17.
- Kistler PM, Rajappan K, Jahngir M, Earley MJ, Harris S, Abrams D et al. The impact of CT image integration into an electroanatomic mapping system on clinical outcomes of catheter ablation of atrial fibrillation. *J Cardiovasc Electrophysiol* 2006;**17**:1093–101.
- Bertaglia E, Della Bella P, Tondo C, Proclemer A, Bottoni N, De Ponti R et al. Image integration increases efficacy of paroxysmal atrial fibrillation catheter ablation: results from the CartoMerge Italian Registry. *Europace* 2009;**11**:1004–10.
- Caponi D, Corleto A, Scaglione M, Blandino A, Biasco L, Cristoforetti Y et al. Ablation of atrial fibrillation: does the addition of three-dimensional magnetic resonance imaging of the left atrium to electroanatomic mapping improve the clinical outcome?: a randomized comparison of Carto-Merge vs. Carto-XP three-dimensional mapping ablation in patients with paroxysmal and persistent atrial fibrillation. *Europace* 2010; **12**:1098–104.
- Sommer P, Bertagnolli L, Kircher S, Arya A, Bollmann A, Richter S et al. Safety profile of near-zero fluoroscopy atrial fibrillation ablation with non-fluoroscopic catheter visualization: experience from 1000 consecutive procedures. *Europace* 2018;**20**:1952–8.
- Marrouche NF, Wilber D, Hindricks G, Jais P, Akoum N, Marchlinski F et al. Association of atrial tissue fibrosis identified by delayed enhancement MRI and atrial fibrillation catheter ablation: the DECAAF study. *JAMA* 2014;**311**:498–506.
- Fochler F, Yamaguchi T, Kheirkhahan M, Kholmovski EG, Morris AK, Marrouche NF. Late gadolinium enhancement magnetic resonance imaging guided treatment of post-atrial fibrillation ablation recurrent arrhythmia. *Circ Arrhythm Electrophysiol* 2019;**12**:e007174.
- Eichenlaub M, Mueller-Edenborn B, Minners J, Figueras I, Ventura RM, Forcada BR et al. Comparison of various late gadolinium enhancement magnetic resonance imaging methods with high-definition voltage and activation mapping for detection of atrial cardiomyopathy. *Europace* 2022;**24**:1102–11.
- Mammadi A, Demirtola AI, Diker E. Impact of image integration on clinical and procedural outcomes of radiofrequency catheter ablation of atrial fibrillation: a meta-analysis of randomized controlled trials. *J Arrhythmia* 2021;**37**:550–5.
- Teres C, Soto-Iglesias D, Penela D, Jáuregui B, Ordoñez A, Chauca A et al. Personalized paroxysmal atrial fibrillation ablation by tailoring ablation index to the left atrial wall thickness: the 'Ablate by-LAW' single-centre study—a pilot study. *Europace* 2022; **24**:390–9.
- Romero J, Husain SA, Kelesidis I, Sanz J, Medina HM, Garcia MJ. Detection of left atrial appendage thrombus by cardiac computed tomography in patients with atrial fibrillation: a meta-analysis. *Circ Cardiovasc Imaging* 2013;**6**:185–94.
- Teres C, Soto-Iglesias D, Penela D, Falasconi G, Viveros D, Meca-Santamaria J et al. Relationship between the posterior atrial wall and the esophagus: esophageal position and temperature measurement during atrial fibrillation ablation (AWESOME-AF). A randomized controlled trial. *J Interv Card Electrophysiol* 2022;**65**:651–61.
- Masuda M, Fujita M, Iida O, Okamoto S, Ishihara T, Nanto K et al. Left atrial low-voltage areas predict atrial fibrillation recurrence after catheter ablation in patients with paroxysmal atrial fibrillation. *Int J Cardiol* 2018;**257**:97–101.
- Junarta J, Siddiqui MU, Riley JM, Dikdan SJ, Patel A, Frisch DR. Low-voltage area substrate modification for atrial fibrillation ablation: a systematic review and meta-analysis of clinical trials. *Europace* 2022;**24**:1585–98.
- Bergonti M, Spera FR, Ferrero TG, Nsahlai M, Bonomi A, Tijssens M et al. Characterization of atrial substrate to predict the success of pulmonary vein isolation: the prospective, multicenter MASH-AF II (Multipolar Atrial Substrate High Density Mapping in Atrial Fibrillation) study. *J Am Heart Assoc* 2023;**12**:e027795.
- Ohguchi S, Iden Y, Yanagisawa S, Fujita R, Yasuda K, Katagiri K et al. Regional left atrial conduction velocity in the anterior wall is associated with clinical recurrence of atrial fibrillation after catheter ablation: efficacy in combination with the ipsilateral low voltage area. *BMC Cardiovasc Disord* 2022;**22**:457.
- Kuo M-J, Ton AN-K, Lo L-W, Lin Y-J, Chang S-L, Hu Y-F et al. Abnormal conduction zone detected by isochronal late activation mapping accurately identifies the potential atrial substrate and predicts the atrial fibrillation ablation outcome after pulmonary vein isolation. *Circ Arrhythm Electrophysiol* 2023;**16**:e011149.
- Benali K, Khairy P, Hammache N, Petzl A, Da Costa A, Verma A et al. Procedure-related complications of catheter ablation for atrial fibrillation. *J Am Coll Cardiol* 2023;**81**:2089–99.
- Hussain SK, Eddy MM, Moorman L, Malhotra R, Darby AE, Bilchick K et al. Major complications and mortality within 30 days of an electrophysiological procedure at an academic medical center: implications for developing national standards. *J Cardiovasc Electrophysiol* 2015;**26**:527–31.
- Della Rocca DG, Di Biase L, Mohanty S, Trivedi C, Gianni C, Romero J et al. Targeting non-pulmonary vein triggers in persistent atrial fibrillation: results from a prospective, multicentre, observational registry. *Europace* 2021;**23**:1939–49.
- Pannone L, Mouram S, Della Rocca DG, Sorgente A, Monaco C, Del Monte A et al. Hybrid atrial fibrillation ablation: long-term outcomes from a single-centre 10-year experience. *Europace* 2023;**25**:eua114.
- Wang TKM, Wang MTM, Martin A. Meta-analysis of ultrasound-guided vs conventional vascular access for cardiac electrophysiology procedures. *J Arrhythmia* 2019;**35**: 858–62.
- Del Monte A, Almorad A, Pannone L, Della Rocca DG, Bisognani A, Monaco C et al. Pulmonary vein isolation with the radiofrequency balloon catheter: a single centre prospective study. *Europace* 2023;**25**:896–904.
- Della Rocca DG, Del Monte A, Bala G, Pannone L, Ströker E, Monaco C et al. Transient inferior ST-segment elevation and ventricular fibrillation after cavotricuspid isthmus pulsed-field ablation. *JACC Clin Electrophysiol* 2023;**9**:704–6.
- Del Monte A, Chierchia GB, Della Rocca DG, Pannone L, Sorgente A, Bala G et al. Posterior wall isolation via a multi-electrode radiofrequency balloon catheter: feasibility, technical considerations, endoscopic findings and comparison with cryoballoon technologies. *J Interv Card Electrophysiol* 2023. doi: 10.1007/s10840-023-01549-1 (Online ahead of print).
- Mohanty S, Trivedi C, Beheiry S, Al-Ahmad A, Horton R, Della Rocca DG et al. Venous access-site closure with vascular closure device vs. manual compression in patients undergoing catheter ablation or left atrial appendage occlusion under uninterrupted anticoagulation: a multicentre experience on efficacy and complications. *Europace* 2019;**21**:1048–54.
- Del Prete A, Della Rocca DG, Calcagno S, Di Pietro R, Del Prete G, Biondi-Zoccai G et al. Perclose Proglide™ for vascular closure. *Future Cardiol* 2021;**17**:269–82.
- Canpolat U, Faggioni M, Della Rocca DG, Chen Q, Ayhan H, Vu AA et al. State of fluorless procedures in cardiac electrophysiology practice. *J Innov Card Rhythm Manag* 2020;**11**:4018–29.
- Berti S, Paradossi U, Meucci F, Trianni G, Tzikas A, Rezzaghi M et al. Periprocedural intracardiac echocardiography for left atrial appendage closure: a dual-center experience. *JACC Cardiovasc Interv* 2014;**7**:1036–44.

39. Gianni C, Horton RP, Della Rocca DG, Mohanty S, Al-Ahmad A, Bassiouny MA *et al*. Intracardiac echocardiography- versus transesophageal echocardiography-guided left atrial appendage occlusion with Watchman FLX. *J Cardiovasc Electrophysiol* 2021;**32**: 2781–4.
40. Della Rocca DG, Gianni C, Magnocavallo M, Mohanty S, Al-Ahmad A, Tschopp DR *et al*. 3-Dimensional intracardiac echocardiography-guided percutaneous closure of a residual leak via radiofrequency applications after LAAO. *JACC Clin Electrophysiol* 2022;**8**:1609–12.
41. Messele LF, Khan MZ, Darden D, Agarwal S, Krishan S, Pasupula DK *et al*. Outcomes of percutaneous left atrial appendage occlusion device implantation in atrial fibrillation patients based on underlying stroke risk. *Europace* 2023;**25**:1415–22.
42. Tops LF, Schalij MJ, den Uijl DW, Abraham TP, Calkins H, Bax JJ. Image integration in catheter ablation of atrial fibrillation. *Europace* 2008;**10**:iii48–56.
43. Niinuma H, George RT, Arbab-Zadeh A, Lima JAC, Henrikson CA. Imaging of pulmonary veins during catheter ablation for atrial fibrillation: the role of multi-slice computed tomography. *Europace* 2008;**10**:iii14–21.
44. Graham LN, Melton IC, MacDonald S, Crozier IG. Value of CT localization of the fossa ovalis prior to transeptal left heart catheterization for left atrial ablation. *Europace* 2007;**9**:417–23.
45. Marazzi R, De Ponti R, Lumia D, Fugazzola C, Salerno-Uriarte JA. Common trunk of the inferior pulmonary veins: an unexpected anatomical variant detected before ablation by multi-slice computed tomography. *Europace* 2007;**9**:121.
46. Sorgente A, Chierchia GB, de Asmundis C, Sarkozy A, Namdar M, Capulzini L *et al*. Pulmonary vein ostium shape and orientation as possible predictors of occlusion in patients with drug-refractory paroxysmal atrial fibrillation undergoing cryoballoon ablation. *Europace* 2011;**13**:205–12.
47. Falasconi G, Penela D, Soto-Iglesias D, Francia P, Teres C, Saglietto A *et al*. Personalized pulmonary vein antrum isolation guided by left atrial wall thickness for persistent atrial fibrillation. *Europace* 2023;**25**:euaad118.
48. Li Y-G, Yang M, Li Y, Wang Q, Yu L, Sun J. Spatial relationship between left atrial roof or superior pulmonary veins and bronchi or pulmonary arteries by dual-source computed tomography: implication for preventing injury of bronchi and pulmonary arteries during atrial fibrillation ablation. *Europace* 2011;**13**:809–14.
49. Gavin AR, Singleton CB, McGavigan AD. Assessment of oesophageal position by direct visualization with luminal contrast compared with segmentation from pre-acquired computed tomography scan-implications for ablation strategy. *Europace* 2014;**16**: 1304–8.
50. Canpolat U, Aytмир K, Hizal M, Hazirolan T, Yorgun H, Sahiner L *et al*. Imaging before cryoablation of atrial fibrillation: is phrenic nerve palsy predictable? *Europace* 2014;**16**: 505–10.
51. Schley P, Gülker H, Horlitz M. Atrio-oesophageal fistula following circumferential pulmonary vein ablation: verification of diagnosis with multislice computed tomography. *Europace* 2006;**8**:189–90.
52. Pérez-Castellano N, Villacastín J, Moreno J, Macaya C. Pivotal role of integrated electroanatomic mapping with three-dimensional multislice computed tomography scan in the ablation of a left atrial ectopic focus. *Europace* 2007;**9**:119–20.
53. Cho Y, Lee W, Park E-A, Oh I-Y, Choi E-K, Seo J-W *et al*. The anatomical characteristics of three different endocardial lines in the left atrium: evaluation by computed tomography prior to mitral isthmus block attempt. *Europace* 2012;**14**:1104–11.
54. Klemm HU, Weber TF, Johnsen C, Begemann PGC, Meinertz T, Ventura R. Anatomical variations of the right coronary artery may be a source of difficult block and conduction recurrence in catheter ablation of common-type atrial flutter. *Europace* 2010;**12**:1608–15.
55. Falasconi G, Penela D, Soto-Iglesias D, Terés C, Jáuregui B, Martí-Almor J *et al*. Multidetector computed tomography identification of previous ablation lines: insights for left atrial flutter ablation. *Heart Rhythm* 2022;**19**:1753–4.
56. Chubb H, Harrison JL, Weiss S, Krueger S, Koken P, Bloch LØ *et al*. Development, pre-clinical validation, and clinical translation of a cardiac magnetic resonance-electrophysiology system with active catheter tracking for ablation of cardiac arrhythmia. *JACC Clin Electrophysiol* 2017;**3**:89–103.
57. Oakes RS, Badger TJ, Kholmovski EG, Akoum N, Burgon NS, Fish EN *et al*. Detection and quantification of left atrial structural remodeling with delayed-enhancement magnetic resonance imaging in patients with atrial fibrillation. *Circulation* 2009;**119**: 1758–67.
58. King JB, Azadani PN, Suksaranjit P, Bress AP, Witt DM, Han FT *et al*. Left atrial fibrosis and risk of cerebrovascular and cardiovascular events in patients with atrial fibrillation. *J Am Coll Cardiol* 2017;**70**:1311–21.
59. Akoum N, Wilber D, Hindricks G, Jais P, Cates J, Marchlinski F *et al*. MRI assessment of ablation-induced scarring in atrial fibrillation: analysis from the DECAAF study. *J Cardiovasc Electrophysiol* 2015;**26**:473–80.
60. Marrouche NF, Wazni O, McGann C, Greene T, Dean JM, Dagher L *et al*. Effect of MRI-guided fibrosis ablation vs conventional catheter ablation on atrial arrhythmia recurrence in patients with persistent atrial fibrillation: the DECAAF II randomized clinical trial. *JAMA* 2022;**327**:2296–305.
61. Khoshknab M, Kuo L, Zghaib T, Arkles J, Santangeli P, Marchlinski FE *et al*. Esophageal luminal temperature rise during atrial fibrillation ablation is associated with lower radiofrequency electrode distance and baseline impedance. *J Cardiovasc Electrophysiol* 2021;**32**:1857–64.
62. Ayoub T, El Hajjar AH, Singh Sidhu GD, Bhatnagar A, Zhang Y, Mekhael M *et al*. Esophageal temperature during atrial fibrillation ablation poorly predicts esophageal injury: an observational study. *Heart Rhythm* 2021;**2**:570–7.
63. Quinto L, Cozzari J, Benito E, Alarcón F, Bisbal F, Trotta O *et al*. Magnetic resonance-guided re-ablation for atrial fibrillation is associated with a lower recurrence rate: a case-control study. *Europace* 2020;**22**:1805–11.
64. Schofield R, Menezes L, Underwood SR. Nuclear cardiology: state of the art. *Heart* 2021;**107**:954–61.
65. Askew JW, Miller TD, Hodge DO, Gibbons RJ. The value of myocardial perfusion single-photon emission computed tomography in screening asymptomatic patients with atrial fibrillation for coronary artery disease. *J Am Coll Cardiol* 2007;**50**:1080–5.
66. Smit MD, Tio RA, Slart RHJA, Zijlstra F, Van Gelder IC. Myocardial perfusion imaging does not adequately assess the risk of coronary artery disease in patients with atrial fibrillation. *Europace* 2010;**12**:643–8.
67. Wichter T. Impaired myocardial perfusion in atrial fibrillation cause or effect? *Europace* 2010;**12**:611–3.
68. Range FT, Schäfers M, Acil T, Schäfers KP, Kies P, Paul M *et al*. Impaired myocardial perfusion and perfusion reserve associated with increased coronary resistance in persistent idiopathic atrial fibrillation. *Eur Heart J* 2007;**28**:2223–30.
69. Ju W, Li M, Wang DW, Yang B, Shao Y, Wang J *et al*. Idiopathic isolated fibrotic atrial cardiomyopathy underlies unexplained scar-related atrial tachycardia in younger patients. *Europace* 2018;**20**:1657–65.
70. Ilyushenkova J, Sazonova S, Zavadovsky K, Batalov R, Rogovskaya Y, Anfinogenova Y *et al*. Diagnostic efficacy of cardiac scintigraphy with 99mTc-Pyrophosphate for latent myocardial inflammation in patients with atrial fibrillation. *Cardiol Res Pract* 2020;**2020**: 5983751.
71. Lemery R, Ben-Haim S, Wells G, Ruddy TD. I-123-Metaiodobenzylguanidine imaging in patients with atrial fibrillation undergoing cardiac mapping and ablation of autonomic ganglia. *Heart Rhythm* 2017;**14**:128–32.
72. Knackstedt C, Schauer P, Kirchhof P. Electro-anatomic mapping systems in arrhythmias. *Europace* 2008;**10**:iii28–34.
73. Heidebuchel H, Wittkamp FHM, Vano E, Ernst S, Schilling R, Picano E *et al*. Practical ways to reduce radiation dose for patients and staff during device implantations and electrophysiological procedures. *Europace* 2014;**16**:946–64.
74. Marinskis G, Bongiorno MG, Dagues N, Lewalter T, Pison L, Blomstrom-Lundqvist C *et al*. X-ray exposure hazards for physicians performing ablation procedures and device implantation: results of the European Heart Rhythm Association survey. *Europace* 2013;**15**:444–6.
75. Dagues N, Cantu F, Geelen P, Lewalter T, Proclemer A, Blomstrom-Lundqvist C. Current practice of ventricular tachycardia ablation in patients with implantable cardioverter-defibrillators. *Europace* 2012;**14**:135–7.
76. Titz RR, Lenarczyk R, Scherr D, Haugaa KH, Iliodromitis K, Pürerfellner H *et al*. Management of ventricular tachycardia in the ablation era: results of the European Heart Rhythm Association survey. *Europace* 2018;**20**:209–13.
77. de Chillou C, Lacroix D, Klug D, Magnin-Poull I, Marquié C, Messier M *et al*. Isthmus characteristics of reentrant ventricular tachycardia after myocardial infarction. *Circulation* 2002;**105**:726–31.
78. Miljoen H, State S, de Chillou C, Magnin-Poull I, Dotto P, Andronache M *et al*. Electroanatomic mapping characteristics of ventricular tachycardia in patients with arrhythmogenic right ventricular cardiomyopathy/dysplasia. *Europace* 2005;**7**:516–24.
79. Vijnmaalen AP, van der Geest RJ, van Huls van Taxis CFB, Siebelink H-MJ, Kroft LJM, Bax JJ *et al*. Head-to-head comparison of contrast-enhanced magnetic resonance imaging and electroanatomical voltage mapping to assess post-infarct scar characteristics in patients with ventricular tachycardias: real-time image integration and reversed registration. *Eur Heart J* 2011;**32**:104–14.
80. Codreanu A, Odille F, Aliot E, Marie P-Y, Magnin-Poull I, Andronache M *et al*. Electroanatomic characterization of post-infarct scars. *J Am Coll Cardiol* 2008;**52**: 839–42.
81. Ghashan CA, Androulakis AFA, Tao Q, Ghashan RN, Wisse LJ, Ebert M *et al*. Whole human heart histology to validate electroanatomical voltage mapping in patients with non-ischaemic cardiomyopathy and ventricular tachycardia. *Eur Heart J* 2018; **39**:2867–75.
82. Bazan V, Frankel DS, Santangeli P, Garcia FC, Tschabrunn CM, Marchlinski FE. Three-dimensional myocardial scar characterization from the endocardium: usefulness of endocardial unipolar electroanatomic mapping. *J Cardiovasc Electrophysiol* 2019;**30**: 427–37.
83. Muser D, Nucifora G, Castro SA, Enriquez A, Chahal CAA, Magnani S *et al*. Myocardial substrate characterization by CMR T1 mapping in patients with NICM and no LGE undergoing catheter ablation of VT. *JACC Clin Electrophysiol* 2021;**7**:831–40.
84. Della Bella P, Baratto F. Evolving patterns of ventricular tachycardia modifying our mapping techniques. *Europace* 2012;**14**:ii1–2.

85. Battaglia A, Odille F, Magnin-Poull I, Sellal J-M, Hoyland P, Hooks D V et al. An efficient algorithm based on electrograms characteristics to identify ventricular tachycardia isthmus entrance in post-infarct patients. *Europace* 2020;**22**:109–16.
86. Acosta J, Penela D, Andreu D, Cabrera M, Carlosena A, Vassanelli F et al. Multielectrode vs. point-by-point mapping for ventricular tachycardia substrate ablation: a randomized study. *Europace* 2018;**20**:512–9.
87. Acosta J, Andreu D, Penela D, Cabrera M, Carlosena A, Korshunov V et al. Elucidation of hidden slow conduction by double ventricular extrastimuli: a method for further arrhythmic substrate identification in ventricular tachycardia ablation procedures. *Europace* 2018;**20**:337–46.
88. de Chillou C, Groben L, Magnin-Poull I, Andronache M, Abbas M, Zhang N et al. Localizing the critical isthmus of postinfarct ventricular tachycardia: the value of pace-mapping during sinus rhythm. *Heart Rhythm* 2014;**11**:175–81.
89. Briceño DF, Romero J, Villablanca PA, Londoño A, Diaz JC, Maraj I et al. Long-term outcomes of different ablation strategies for ventricular tachycardia in patients with structural heart disease: systematic review and meta-analysis. *Europace* 2018;**20**:104–15.
90. Jáuregui B, Soto-Iglesias D, Zucchelli G, Penela D, Ordóñez A, Terés C et al. Arrhythmogenic substrate detection in chronic ischaemic patients undergoing ventricular tachycardia ablation using multidetector cardiac computed tomography: compared evaluation with cardiac magnetic resonance. *Europace* 2021;**23**:82–90.
91. Andreu D, Ortiz-Pérez JT, Fernández-Armenta J, Guiu E, Acosta J, Prat-González S et al. 3D delayed-enhanced magnetic resonance sequences improve conducting channel delineation prior to ventricular tachycardia ablation. *Europace* 2015;**17**:938–45.
92. Siebelink H-MJ, Scholte AJHA, Van de Veire NR, Holman ER, Nucifora G, van der Wall EE et al. Value of contrast echocardiography for left ventricular thrombus detection postinfarction and impact on antithrombotic therapy. *Coron Artery Dis* 2009;**20**:462–6.
93. Pannone L, Falasconi G, Cianfanelli L, Baldetti L, Moroni F, Spoladore R et al. Sudden cardiac death in patients with heart disease and preserved systolic function: current options for risk stratification. *J Clin Med* 2021;**10**:1823.
94. Stecker EC, Vickers C, Waltz J, Socoteanu C, John BT, Mariani R et al. Population-based analysis of sudden cardiac death with and without left ventricular systolic dysfunction: two-year findings from the Oregon Sudden Unexpected Death study. *J Am Coll Cardiol* 2006;**47**:1161–6.
95. Penela D, Fernández-Armenta J, Aguinaga L, Tercedor L, Ordoñez A, Bisbal F et al. Clinical recognition of pure premature ventricular complex-induced cardiomyopathy at presentation. *Heart Rhythm* 2017;**14**:1864–70.
96. Wang J-S, Shen Y-G, Yin R-P, Thapa S, Peng Y-P, Ji K-T et al. The safety of catheter ablation for premature ventricular contractions in patients without structural heart disease. *BMC Cardiovasc Disord* 2018;**18**:177.
97. Vergara P, Scarfò I, Esposito A, Colantoni C, Palmisano A, Altizio S et al. Characterization of the electrophysiological substrate in patients with Barlow's disease. *J Cardiovasc Electrophysiol* 2021;**32**:3179–86.
98. Vergara P, Altizio S, Falasconi G, Pannone L, Gulletta S, Della Bella P. Electrophysiological substrate in patients with Barlow's disease. *Arrhythmia Electrophysiol Rev* 2021;**10**:33–7.
99. Bourier F, Martin R, Martin CA, Takigawa M, Kitamura T, Frontera A et al. Is it feasible to offer 'targeted ablation' of ventricular tachycardia circuits with better understanding of isthmus anatomy and conduction characteristics? *Europace* 2019;**21**:i27–33.
100. Komatsu Y, Cochet H, Jadidi A, Sacher F, Shah A, Derval N et al. Regional myocardial wall thinning at multidetector computed tomography correlates to arrhythmogenic substrate in postinfarction ventricular tachycardia: assessment of structural and electrical substrate. *Circ Arrhythm Electrophysiol* 2013;**6**:342–50.
101. Ghanam M, Cochet H, Jais P, Sermesant M, Patel S, Siontis KC et al. Correlation between computer tomography-derived scar topography and critical ablation sites in postinfarction ventricular tachycardia. *J Cardiovasc Electrophysiol* 2018;**29**:438–45.
102. Sramko M, Hoogendoorn JC, Glashan CA, Zeppenfeld K. Advancement in cardiac imaging for treatment of ventricular arrhythmias in structural heart disease. *Europace* 2019;**21**:383–403.
103. Piers SRD, van Huls van Taxis CFB, Tao Q, van der Geest RJ, Askar SF, Siebelink H-MJ et al. Epicardial substrate mapping for ventricular tachycardia ablation in patients with non-ischaemic cardiomyopathy: a new algorithm to differentiate between scar and viable myocardium developed by simultaneous integration of computed tomography and contrast-enhanced magnetic resonance imaging. *Eur Heart J* 2013;**34**:586–96.
104. Yamashita S, Sacher F, Mahida S, Berte B, Lim HS, Komatsu Y et al. Role of high-resolution image integration to visualize left phrenic nerve and coronary arteries during epicardial ventricular tachycardia ablation. *Circ Arrhythm Electrophysiol* 2015;**8**:371–80.
105. Xu L, Zahid S, Khoshknab M, Moss J, Berger RD, Chrispin J et al. Lipomatous metaplasia prolongs repolarization and increases repolarization dispersion within post-infarct ventricular tachycardia circuit sites. *Europace* 2023;**25**:496–505.
106. Bonnin T, Roumegou P, Sridi S, Mahida S, Bustin A, Duchateau J et al. Prevalence and risk factors of cardiac thrombus prior to ventricular tachycardia catheter ablation in structural heart disease. *Europace* 2023;**25**:487–95.
107. Korshunov V, Penela D, Linhart M, Acosta J, Martinez M, Soto-Iglesias D et al. Prediction of premature ventricular complex origin in left vs. right ventricular outflow tract: a novel anatomical imaging approach. *Europace* 2019;**21**:147–53.
108. Rivera S, de la Paz Ricapito M, Tomas L, Parodi J, Molina GB, Banega R et al. Results of cryoenergy and radiofrequency-based catheter ablation for treating ventricular arrhythmias arising from the papillary muscles of the left ventricle, guided by intracardiac echocardiography and image integration. *Circ Arrhythm Electrophysiol* 2016;**9**:e003874.
109. Thomsen AF, Bertelsen L, Jøns C, Jabbari R, Lønborg J, Kyhl K et al. Scar border zone mass and presence of border zone channels assessed with cardiac magnetic resonance imaging are associated with ventricular arrhythmia in patients with ST-segment elevation myocardial infarction. *Europace* 2023;**25**:978–88.
110. Fernandez-Armenta J, Berruezo A, Mont L, Sitges M, Andreu D, Silva E et al. Use of myocardial scar characterization to predict ventricular arrhythmia in cardiac resynchronization therapy. *Europace* 2012;**14**:1578–86.
111. Leonardi S, Raineri C, De Ferrari GM, Ghio S, Scelsi L, Pasotti M et al. Usefulness of cardiac magnetic resonance in assessing the risk of ventricular arrhythmias and sudden death in patients with hypertrophic cardiomyopathy. *Eur Heart J* 2009;**30**:2003–10.
112. Andreu D, Ortiz-Pérez JT, Boussy T, Fernández-Armenta J, de Caralt TM, Perea RJ et al. Usefulness of contrast-enhanced cardiac magnetic resonance in identifying the ventricular arrhythmia substrate and the approach needed for ablation. *Eur Heart J* 2014;**35**:1316–26.
113. Roca-Luque I, Van Breukelen A, Alarcon F, Garre P, Tolosana JM, Borrás R et al. Ventricular scar channel entrances identified by new wideband cardiac magnetic resonance sequence to guide ventricular tachycardia ablation in patients with cardiac defibrillators. *Europace* 2020;**22**:598–606.
114. Jáuregui B, Soto-Iglesias D, Penela D, Acosta J, Fernández-Armenta J, Linhart M et al. Cardiovascular magnetic resonance determinants of ventricular arrhythmic events after myocardial infarction. *Europace* 2022;**24**:938–47.
115. Linhart M, Doltra A, Acosta J, Borrás R, Jáuregui B, Fernández-Armenta J et al. Ventricular arrhythmia risk is associated with myocardial scar but not with response to cardiac resynchronization therapy. *Europace* 2020;**22**:1391–400.
116. Fernández-Armenta J, Berruezo A, Andreu D, Camara O, Silva E, Serra L et al. Three-dimensional architecture of scar and conducting channels based on high resolution ce-CMR: insights for ventricular tachycardia ablation. *Circ Arrhythm Electrophysiol* 2013;**6**:528–37.
117. Andreu D, Penela D, Acosta J, Fernández-Armenta J, Perea RJ, Soto-Iglesias D et al. Cardiac magnetic resonance-aided scar dechanneling: influence on acute and long-term outcomes. *Heart Rhythm* 2017;**14**:1121–8.
118. Soto-Iglesias D, Penela D, Jáuregui B, Acosta J, Fernández-Armenta J, Linhart M et al. Cardiac magnetic resonance-guided ventricular tachycardia substrate ablation. *JACC Clin Electrophysiol* 2020;**6**:436–47.
119. Bière L, Mezdad T-H, Dupuis J-M, Vervueren L, Rakotonirina H, Prunier F et al. Long-term prognostic significance of right bundle-branch morphology ventricular ectopy induced during stress test in patients with intermediate to high probability of coronary artery disease. *Europace* 2018;**20**:528–34.
120. Peretto G, Busnardo E, Ferro P, Palmisano A, Vignale D, Esposito A et al. Clinical applications of FDG-PET scan in arrhythmic myocarditis. *JACC Cardiovasc Imaging* 2022;**15**:1771–80.
121. Peretto G, Sommariva E, Di Resta C, Rabino M, Villatore A, Lazzeroni D et al. Myocardial inflammation as a manifestation of genetic cardiomyopathies: from bedside to the bench. *Biomolecules* 2023;**13**:646.
122. Morishima I, Okumura K, Tsuboi H, Morita Y, Takagi K, Yoshida R et al. Impact of basal inferolateral scar burden determined by automatic analysis of 99mTc-MIBI myocardial perfusion SPECT on the long-term prognosis of cardiac resynchronization therapy. *Europace* 2017;**19**:573–80.
123. Neri G, Zanco P, Zanon F, Buchberger R. Effect of biventricular pacing on metabolism and perfusion in patients affected by dilated cardiomyopathy and left bundle branch block: evaluation by positron emission tomography. *Europace* 2003;**5**:111–5.
124. Peretto G, Sala S, Basso C, Rizzo S, Radinovic A, Frontera A et al. Inflammation as a predictor of recurrent ventricular tachycardia after ablation in patients with myocarditis. *J Am Coll Cardiol* 2020;**76**:1644–56.
125. Friehling M, Menon PG, Ludwig DR, Schwartzman D. Single-photon emission computed tomographic-multidetector computed tomographic fusion image integration: a potential aid to left ventricular substrate ablation. *Europace* 2014;**16**:1860–3.
126. Gimelli A, Menichetti F, Soldati E, Liga R, Scelza N, Zucchelli G et al. Predictors of ventricular ablation's success: viability, innervation, or mismatch? *J Nucl Cardiol* 2021;**28**:175–83.
127. Palmisano A, Vignale D, Peretto G, Busnardo E, Calcagno C, Campochiaro C et al. Hybrid FDG-PET/MR or FDG-PET/CT to detect disease activity in patients with persisting arrhythmias after myocarditis. *JACC Cardiovasc Imaging* 2021;**14**:288–92.
128. Preumont N, Jansens J-L, Berkenboom G, van de Borne P, Stoupeul E, Goldman S. Effects of right ventricular pacing on regional myocardial glucose metabolism. *Europace* 2005;**7**:584–91.

129. Kammerlander AA, Marzluft BA, Zotter-Tufaro C, Aschauer S, Duca F, Bachmann A *et al*. T1 mapping by CMR imaging: from histological validation to clinical implication. *JACC Cardiovasc Imaging* 2016;**9**:14–23.
130. Nensa F, Bamberg F, Rischpler C, Menezes L, Poeppel TD, la Fougère C *et al*. Hybrid cardiac imaging using PET/MRI: a joint position statement by the European Society of Cardiovascular Radiology (ESCR) and the European Association of Nuclear Medicine (EANM). *Eur Radiol* 2018;**28**:4086–101.
131. Grubb CS, Melki L, Wang DY, Peacock J, Dizon J, Iyer V *et al*. Noninvasive localization of cardiac arrhythmias using electromechanical wave imaging. *Sci Transl Med* 2020;**12**: eaax6111.
132. Attia ZI, Noseworthy PA, Lopez-Jimenez F, Asirvatham SJ, Deshmukh AJ, Gersh BJ *et al*. An artificial intelligence-enabled ECG algorithm for the identification of patients with atrial fibrillation during sinus rhythm: a retrospective analysis of outcome prediction. *Lancet* 2019;**394**:861–7.
133. Popescu DM, Abramson HG, Yu R, Lai C, Shade JK, Wu KC *et al*. Anatomically informed deep learning on contrast-enhanced cardiac magnetic resonance imaging for scar segmentation and clinical feature extraction. *Cardiovasc Digit Health J* 2022;**3**:2–13.
134. Popescu DM, Shade JK, Lai C, Aronis KN, Ouyang D, Moorthy MV *et al*. Arrhythmic sudden death survival prediction using deep learning analysis of scarring in the heart. *Nat Cardiovasc Res* 2022;**1**:334–43.
135. Sung E, Prakosa A, Zhou S, Berger RD, Chrispin J, Nazarian S *et al*. Fat infiltration in the infarcted heart as a paradigm for ventricular arrhythmias. *Nat Cardiovasc Res* 2022;**1**: 933–45.
136. Boyle PM, Zghaib T, Zahid S, Ali RL, Deng D, Franceschi WH *et al*. Computationally guided personalized targeted ablation of persistent atrial fibrillation. *Nat Biomed Eng* 2019;**3**:870–9.
137. Prakosa A, Arevalo HJ, Deng D, Boyle PM, Nikolov PP, Ashikaga H *et al*. Personalized virtual-heart technology for guiding the ablation of infarct-related ventricular tachycardia. *Nat Biomed Eng* 2018;**2**:732–40.
138. Shade JK, Prakosa A, Popescu DM, Yu R, Okada DR, Chrispin J *et al*. Predicting risk of sudden cardiac death in patients with cardiac sarcoidosis using multimodality imaging and personalized heart modeling in a multivariable classifier. *Sci Adv* 2021;**7**: eabi8020.