

# Current Perspectives on the Use of Anti-VEGF Drugs as Adjuvant Therapy in Glaucoma

Vanessa Andrés-Guerrero · Lucía Perucho-González · Julián García-Feijoo ·  
Laura Morales-Fernández · Federico Saenz-Francés · Rocío Herrero-Vanrell ·  
Luis Pablo Júlvez · Vicente Polo Llorens · José María Martínez-de-la-Casa ·  
Anastasios-Georgios P. Konstas

Received: October 17, 2016

© The Author(s) 2016. This article is published with open access at Springerlink.com

## ABSTRACT

The approval of one of the first anti-vascular endothelial growth factor (VEGF) agents for the treatment of neovascular age-related macular degeneration one decade ago marked the beginning of a new era in the management of several sight-threatening retinal diseases. Since then, emerging evidence has demonstrated the utility of these therapies for the treatment of

other ocular conditions characterized by elevated VEGF levels. In this article we review current perspectives on the use of anti-VEGF drugs as adjuvant therapy in the management of neovascular glaucoma (NVG). The use of anti-VEGFs for modifying wound healing in glaucoma filtration surgery (GFS) is also reviewed. Selected studies investigating the use of anti-VEGF agents or antimetabolites in GFS or the management of NVG have demonstrated that these agents can improve surgical outcomes. However, anti-VEGF agents have yet to demonstrate specific advantages over

**Enhanced content** To view enhanced content for this article go to <http://www.medengine.com/Redeem/4237F06040074294>.

V. Andrés-Guerrero · L. Perucho-González ·  
J. García-Feijoo · L. Morales-Fernández ·  
F. Saenz-Francés · R. Herrero-Vanrell ·  
L. P. Júlvez · V. P. Llorens · J. M. Martínez-de-la-Casa  
Ocular Pathology National Net OFTARED of the  
Institute of Health Carlos III, Madrid, Spain

V. Andrés-Guerrero · L. Perucho-González ·  
J. García-Feijoo · L. Morales-Fernández ·  
F. Saenz-Francés · J. M. Martínez-de-la-Casa  
Department of Ophthalmology, Hospital Clínico  
San Carlos, Complutense University of Madrid,  
Madrid, Spain

V. Andrés-Guerrero · L. Perucho-González ·  
J. García-Feijoo · L. Morales-Fernández ·  
F. Saenz-Francés · R. Herrero-Vanrell ·  
J. M. Martínez-de-la-Casa  
Sanitary Research Institute of the San Carlos Clinical  
Hospital, Madrid, Spain

R. Herrero-Vanrell  
Department of Pharmacy and Pharmaceutical  
Technology, Faculty of Pharmacy, Complutense  
University of Madrid, Madrid, Spain

L. P. Júlvez · V. P. Llorens  
Department of Ophthalmology, Hospital  
Universitario Miguel Servet, Saragossa, Spain

L. P. Júlvez · V. P. Llorens  
Aragon Health Sciences Institute, Saragossa, Spain

A.-G. P. Konstas (✉)  
1st and 3rd University Departments of  
Ophthalmology, AHEPA Hospital, Aristotle  
University of Thessaloniki, 1 Kyriakidi Street,  
546 36 Thessaloniki, Greece  
e-mail: konstas@med.auth.gr

the more established agents commonly used today. Further studies are needed to evaluate the duration of action, dosing intervals, and toxicity profile of these treatments.

**Keywords:** Angiogenesis; Aflibercept; Bevacizumab; Glaucoma filtration surgery; Neovascular glaucoma; Ranibizumab; VEGF; Wound modulation

## INTRODUCTION

Glaucoma comprises a group of disorders characterized by a distinctive optic neuropathy that leads to progressive asymptomatic visual field loss. It is thought that loss of vision in glaucoma is associated with damage to the optic nerve and retina that results in irreversible retinal ganglion cell damage. Glaucoma is currently the leading cause of irreversible blindness worldwide. It has been estimated that the total number of patients with glaucoma will be close to 80 million by 2020 [1].

Because glaucomatous neuropathy is usually associated with elevation of intraocular pressure (IOP), the main objective of all available treatment options comprises a meaningful IOP reduction to a predetermined level, which is commensurate with either stability or delayed progression of visual loss [2]. When medical and laser therapies fail to control IOP, glaucoma filtration surgery (GFS) is usually necessary. GFS techniques lower the IOP by establishing an surgical outflow channel through which the aqueous humor drains continuously from the anterior chamber to the sub-Tenon and subconjunctival space [3].

Nevertheless, the long-term success of GFS is often compromised by the relentless wound-healing process ultimately blocking the surgically created outflow pathway at the

conjunctival and episcleral plane. Diverse molecular and cellular processes such as collagen deposition, angiogenesis, and the activation and proliferation of fibroblasts are implicated in the healing process which eventually obstructs aqueous outflow [4]. As a result, glaucoma surgery often fails to adequately control IOP and the patient's visual decline continues [5, 6]. The success of GFS has improved considerably following the intraoperative and postoperative application of antimetabolites such as 5-fluorouracil and mitomycin C. However, it should be emphasized that the mechanism by which these molecules prevent healing is nonspecific and can lead to excessive collateral tissue damage. Excessive prevention of wound healing observed in antimetabolite-augmented GFS is associated with complications such as postoperative hypotony, infections, corneal toxicity, and a thin-walled avascular bleb, which is prone to leakage [7-9]. Consequently, approaches to modulate the wound-healing response with medications that have an improved safety profile are under investigation.

Angiogenesis is a key element of the wound-healing process and is essential for the ultimate formation of granulation tissue. Vascular endothelial growth factor (VEGF) is a potent inducer of angiogenesis known to promote the migration of inflammatory cells and fibroblasts as well as having a direct effect upon the activity of fibroblasts [10]. On the basis of this hypothesis, the adjunctive use of VEGF inhibitors has been recently tried in GFS [11-14]. It has been postulated that the use of these selective wound modulators may enhance surgical efficacy and, at the same time, offer a more favorable safety profile.

As a result of their mechanism of action, anti-vascular endothelial growth factor (anti-VEGF) molecules have been investigated

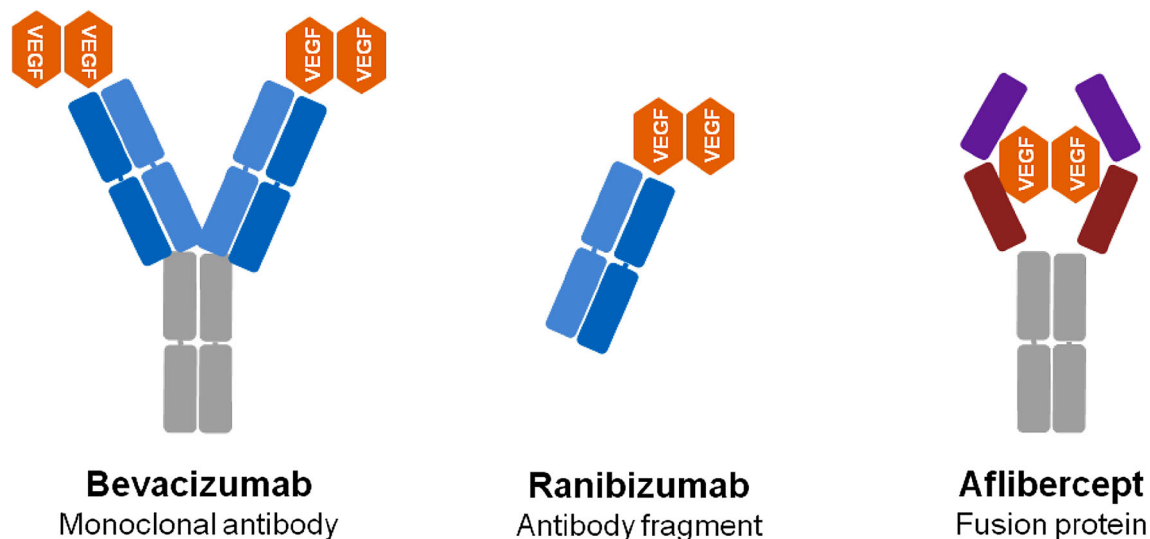
and found to be clinically useful in several conditions in which angiogenesis plays an important role, e.g., neovascular glaucoma (NVG) [15–17]. Importantly, most NVG cases are caused by ischemic diseases such as diabetic retinopathy and central retinal vein occlusion [15–17]. Ocular ischemia initiates the development and gradual growth of subtle new vessels over the trabecular meshwork that subsequently forms a fibrovascular membrane. The development of this membrane obstructs the aqueous humor outflow and causes a significant IOP elevation leading ultimately to a refractory secondary glaucoma [15–17]. This is characterized as a secondary angle closure glaucoma since the contraction of the fibrovascular membrane pulls the peripheral iris into the anterior chamber angle [18]. Comprehensive retinal laser photocoagulation is currently considered the gold standard in eliminating ischemia and the subsequent neovascularization. However, the laser not only destroys the ischemic retinal tissue responsible for the vasoproliferative stimulus but also damages healthy cells that are not involved in the pathologic process of hypoxia [19]. Moreover, it takes a few weeks to obtain a meaningful regression of neovascularization and most patients need intensive IOP-lowering therapy before the beneficial effect of laser photocoagulation is established. A number of recent studies [20–25] have investigated the role of anti-VEGF molecules in the management of NVG. This research explores whether these agents can facilitate IOP control and the preservation of the integrity of healthy retinal cells. It should be emphasized, however, that their precise role as adjuvant therapy in this pathological process is still under investigation. This review examines the current role of anti-VEGF drugs as adjuvant therapy in NVG and their utility in modulating the

postoperative wound-healing response in GFS. We searched the databases of the Cochrane Library, Pubmed, and Embase from the time of their inception to April 2016. This article is based on previously conducted studies, and does not involve any new studies of human or animal subjects performed by any of the authors.

## ANTI-VASCULAR ENDOTHELIAL GROWTH FACTORS

VEGF is a homodimeric glycoprotein characterized by an amino acid homology shared with platelet-derived growth factor [26]. The VEGF family of molecules consists of various ligands [VEGF-A, VEGF-B, VEGF-C, VEGF-D, and placental growth factor (PlGF)] with VEGF-A being the dominant mediator of pro-angiogenic signaling. VEGF-A exists in five isoforms that differ in the average chain lengths (121, 145, 165, 189, and 206 amino acids). VEGF<sub>165</sub> (45 kDa) is the predominant isoform and the key agent in neovascularization [27]. The function of these molecules is primarily mediated by binding and activating two transmembrane tyrosine kinase receptors, VEGFR-1 and VEGFR-2 [28, 29]. Additionally, VEGF binds to isoform-specific VEGF receptors (neuropilins) expressed in endothelial and non-endothelial cells [30, 31]. Several therapies have been developed with the aim of inhibiting VEGF and optimizing the management of several ocular pathologies. These therapeutic applications include three VEGF inhibitors: bevacizumab, ranibizumab, and aflibercept (Fig. 1).

Bevacizumab (BVZ) (Avastin; Genetech, South San Francisco, CA, USA) is a full-size recombinant humanized IgG1 kappa monoclonal antibody against all isoforms of VEGF. This molecule has a total molecular mass



**Fig. 1** Anti-vascular endothelial growth factor drugs for ocular diseases

of 149 kDa, is N-glycosylated in its Fc region and requires mammalian cell lines CHO DP-12 for production [32]. Its function is mediated by binding to both transmembrane tyrosine kinase receptors VEGFR-1 and VEGFR-2, downregulating the mitogenic, angiogenic, and permeability-enhancing effects of VEGF [33]. BVZ was approved by the US Food and Drug Administration (FDA) in 2005 for the treatment of colorectal and breast cancers, but it is also used extensively off-label in several ocular conditions [34].

Ranibizumab (RBZ) (Lucentis; Genetech, South San Francisco, CA, USA) is an antibody binding fragment (Fab) of a recombinant humanized IgG1 kappa isotype murine monoclonal antibody against all isoforms of VEGF, thereby preventing binding of VEGF to its receptors VEGFR-1 and VEGFR-2 [35]. RBZ was developed by selection of a Fab genetically engineered to obtain an increased binding affinity and inhibition of VEGF [36, 37] that differs from the corresponding part in BVZ by six amino acids. RBZ has a total molecular mass of 48 kDa, is not glycosylated, and can be easily produced in *Escherichia coli* cells by

recombinant DNA technology [38]. Owing to its simple structure and its higher affinity for VEGF, RBZ requires lower molar amounts than BVZ to neutralize an equal amount of VEGF [39, 40]. It was approved by the FDA in 2006 and is indicated in adults for the treatment of choroidal neovascularization due to age-related macular degeneration (AMD), the treatment of visual impairment due to diabetic macular edema (DME), macular edema secondary to retinal vein occlusion, and for the treatment of visual impairment due to choroidal neovascularization secondary to pathologic myopia.

Aflibercept (AFB) (Eylea; Regeneron Pharmaceuticals, Tarrytown, NY, USA) is a glycosylated recombinant fusion protein with a total molar mass of 115 kDa. AFB is composed of the combination of a fusion of the second Ig domain of human VEGFR-1 and the third Ig binding domain of human VEGFR-2 with the constant fragment crystallizable portion of the human IgG1 [41]. Produced from hamster ovary cells, AFB binds to all isoforms of VEGF-A with a higher affinity than BVZ and RBZ, also binding to VEGF-B and PlGF. It forms stable, inert,

homogeneous complexes with VEGF that do not induce platelet aggregation or tissue deposits in the systemic circulation [42], unlike what has been hypothesized for heterogeneous multimeric immune complexes formed by BVZ and VEGF [43]. AFB was approved by the FDA for the treatment of choroidal neovascularization due to AMD, DME, and diabetic retinopathy in patients with DME (in 2011, 2014, and 2015, respectively). European Commission regulators subsequently approved AFB in 2015 for the treatment of visual impairment due to macular edema secondary to central or branch retinal vein occlusion.

## ANTI-VEGF DRUGS IN GLAUCOMA MANAGEMENT

### Neovascular Glaucoma

As stated above, NVG is a potentially devastating form of secondary angle-closure glaucoma. As a result of either delayed diagnosis or insufficient management, the prognosis is often poor and can result in visual loss and uncontrollable pain. Clinical conditions associated with ischemia such as proliferative diabetic retinopathy, ischemic central retinal vein occlusion, and ocular ischemic syndrome are the most common entities associated with the development of NVG [44], although in some cases NVG is related to inflammation without clear-cut evidence of ischemia [45]. The pathogenesis of NVG involves the promotion of neovascularization in the anterior chamber angle and specifically the iris. Neovascularization is mediated by pro-angiogenic factors produced in the retina as a result of ischemia; these factors eventually

diffuse into the anterior chamber. As a result, a fibrovascular membrane forms in the iris, the anterior chamber angle, or both. The subsequent contraction of the membrane pulls peripheral iris into the angle leading to the development of secondary angle-closure glaucoma [18]. At this point IOP reaches high levels and it is difficult to control it with conventional antiglaucoma therapies [17].

The successful management of NVG requires adequate control of IOP as well as a targeted therapy directed at the ischemic condition causing the neovascularization. Panretinal photocoagulation (PRP) is still the gold standard therapy for those cases in whom NVG arises from an ischemic retina [19]. PRP destroys the ischemic tissue responsible for the vasoproliferative stimulus, reducing the global oxygen demand of the retina as well as eliminating the synthesis of vasoproliferative factors. However, PRP cannot selectively target pathological tissues and damages healthy tissues that are not involved in the process of hypoxia-induced neovascularization [19]. For that reason, although VEGF levels decrease and neovascularization generally regresses after PRP [46], this treatment causes permanent visual field damage [19]. In addition, the regression of neovascularization after PRP is not immediate and patients usually need close monitoring and combined local and systemic therapy to control elevated IOP for several weeks. Furthermore, this therapeutic approach is limited to eyes with clear media. In contrast, the presence of media opacities (e.g., corneal edema or lens opacities) significantly limits or completely eliminates this therapeutic approach. Therefore, there is a need to develop specific targeted therapies that will reduce angiogenic factors and subsequent neovascularization while at the same time preserving healthy retinal cells. Early evidence

shows that anti-VEGF molecules are promising in that respect [20–25].

### **Key Role of VEGF in Neovascular Glaucoma**

As stated before VEGF is involved in the physiological stimulation of angiogenesis, the process that restores oxygen supply to tissues when blood flow is inadequate [47]. In addition, this factor plays an important role in blood vessel formation when the pre-existing ones are blocked, for instance during embryonic development [48, 49] or following injury [50]. VEGF behaves as an endothelial cell mitogen [26, 51], a chemotactic agent for bone-marrow-derived endothelial cell precursors [52], an inducer of vascular permeability [53, 54], and a survival factor for endothelial cells through inhibition of apoptosis [55]. On the other hand, VEGF overexpression leads to the formation of pathologic blood vessels. Recent studies have demonstrated the significant association between increased VEGF levels in the eye and pathological conditions in which neovascularization or inflammation are involved, such as proliferative diabetic retinopathy [56], NVG [57], uveitis [58], or age-related macular degeneration [15].

### **Anti-VEGF Therapy in Neovascular Glaucoma**

In the setting of NVG, a number of studies have investigated the use of anti-VEGF antibodies, such as BVZ, RBZ, and AFB by topical,

intracameral, or intravitreal administration (Table 1). In a pilot study published by Waisbourd et al. [59] the efficacy of topically applied BVZ for the treatment of NVG was evaluated. Eight patients were treated with topical BVZ (25 mg/mL) four times daily for 2 weeks. The authors observed a mean IOP reduction of 6.1 mmHg and noted that three patients had clinical regression of iris neovascularization [59]. The intracameral administration of BVZ reduced the number of patients requiring surgical treatment of NVG, whereas some other patients became candidates for filtration surgery [60]. In a separate study, a decreased leakage from new iris vessels was observed 1 day after an intracameral injection of BVZ [61].

In a 12-month prospective clinical series published by Lüke et al. [62], 10 cases with NVG received intraocular injections of RBV (0.5 mg/0.05 mL). According to the authors, RBV appeared to be beneficial owing to its anti-angiogenic properties and its ability to prevent or halt anterior chamber angle occlusion [62]. In the same context, Grover et al. [63] reported a considerable reduction in aqueous humor VEGF concentrations following an intracameral injection of BVZ. Furthermore, in a randomized trial of 26 patients treated with intravitreal BVZ, a significant IOP reduction was noted as well as a significant regression of neovascularization compared to sham injections [64]. However, the use of

**Table 1** Summary of studies employing anti-VEGF drugs in glaucoma filtration surgery and neovascular glaucoma

Route of administration	Glaucoma filtration surgery	Neovascular glaucoma
Topical	[80, 83, 101, 105]	[59]
Subconjunctival	[77–80, 82–86, 88]	–
Intracameral	[77]	[59–61, 63]
Intravitreal	[78, 79, 87, 90]	[25, 59, 62, 64–66]



intravitreal BVZ in a later study did not significantly reduce the frequency of hyphema and fibrin formation in the anterior chamber 1 day after surgery and a single injection of the anti-VEGF was insufficient to completely eliminate iris neovascularization [65]. Similarly, in a retrospective review recurrent anterior segment neovascularization was seen after a single intravitreal injection of BVZ [66]. It is worth noting that these authors reported that trabeculectomy provided a protective effect against the recurrence of anterior segment neovascularization [66].

In a more recent study, four patients with newly diagnosed stage 1 or 2 NVG received an intravitreal injection of AFB (2 mg) at the time of diagnosis and then additional injections at 4 weeks, 8 weeks, and at 8-week intervals for 52 weeks [25]. Results showed that iris and angle neovascularization regressed and IOP was either stable or significantly reduced in all patients at the end of the study [25].

### **Wound Modulation in Glaucoma Filtration Surgery**

The wound-healing process consists of four continuous, overlapping, and well-orchestrated phases: hemostasis, inflammation, proliferation, and tissue remodeling. During the healing process, several events take place in a synchronized manner: (a) rapid hemostasis, (b) inflammation, (c) mesenchymal cell differentiation, proliferation, and migration to the wound site, (d) controlled angiogenesis, (e) regrowth of epithelial tissue over the wound surface, and (f) synthesis, cross-linking, and alignment of collagen to provide strength to the healing tissue [67]. Contrary to many other surgical procedures, the success of GFS relies on inhibition of the wound-healing process.

Aggressive healing at the conjunctival and episcleral plane are the major causes of surgical failure, eventually leading to suboptimal or poor IOP control. Collagen accumulation, angiogenesis, and the activation and proliferation of fibroblasts in these areas block the surgically created fistula and prevent controlled aqueous outflow [4].

Bleb vascularity is a central parameter associated with the success of GFS. The formation of an avascular filtering bleb in the postoperative period is generally associated with a favorable outcome, whereas increased vascularity of the filtering bleb is usually seen as a predictor of failure [68]. Accordingly, it has been established that the prognosis of GFS could be significantly improved by decreasing the vascularity of a filtering bleb by inhibiting angiogenesis [11]. It is well documented that the concomitant use of antimetabolites such as 5-fluorouracil (5-FU) and mitomycin C (MMC) has improved the success of GFS. However, the use of these molecules has also been associated with an increased complication rate in the postoperative period as a result of their nonspecific mechanism of action [7–9]. By inducing excessive cell death, antimetabolites can cause extensive ocular tissue alterations that cause postoperative hypotony, corneal toxicity, and a thin-walled avascular bleb susceptible to leakage and postoperative infections. Consequently, alternative safer forms of wound-healing modulation with more specific agents are under investigation. Since VEGF plays a key role in both physiological and pathological angiogenesis, the use of VEGF inhibitors as selective wound modulators with a more favorable safety profile has been intensively studied over the past few years.

### ***Role of VEGF in Wound Modulation***

VEGF is produced by different cell types including endothelial cells [69], macrophages [70], fibroblasts [71], platelets [72], neutrophils [73], and smooth muscle cells [74]. All cell types participate in the wound-healing process so VEGF stimulates multiple components of the wound-healing cascade, such as angiogenesis, epithelization, and collagen deposition [75]. Among the five existing isoforms of VEGF, the predominant VEGF<sub>165</sub> together with VEGF<sub>121</sub> are related to blood vessel growth, while VEGF<sub>189</sub> is associated with fibrosis [11]. Interestingly, some authors have reported a significant correlation between the outcome of glaucoma surgery and VEGF levels in aqueous humor and Tenon's tissue. Specifically, VEGF levels have been reported to be higher in glaucoma patients who experienced failed GFS in comparison to patients without glaucoma or patients with successful GFS [76]. Moreover, the ultimate success of the operation and the 1-year level of IOP in patients with primary open-angle glaucoma have been associated with the aqueous humor and Tenon's tissue levels of VEGF [76], indicating the potential utility of anti-VEGF therapy in promoting the success of GFS.

### ***Anti-VEGF Therapy in GFS***

A number of studies have investigated the topical, intracameral, subconjunctival, and intravitreal administration of anti-VEGF antibodies such as BVZ and RBZ in the context of GFS (Tables 1, 2). In an experimental model of GFS in rabbits, the bleb area could be increased if BVZ was applied into the anterior chamber (5 mg) and the subconjunctival space (2.5 mg) during trabeculectomy. However, the authors did not detect significant differences in the IOP of these animals between treated and control eyes 29 days after surgery [77]. Similar

**Table 2** Summary of studies included in the review on the intraoperative and postoperative application of anti-VEGF drugs in glaucoma filtration surgery, by intracameral (IC), subconjunctival (SC), intravitreal (IV) administration, or applied via soaked sponges (SS)

Intraoperative	[77] (IC, SC), [79] (SC, IV), [80] (SC, SS), [83] (SC), [84] (SC)
Postoperative	[78] (SC), [82] (SC), [85] (SC), [86] (SC), [87] (IV), [88] (SC)

results were obtained in a study in which subconjunctival injection of 1.25 mg BVZ, 5-FU, or balanced salt solution (BSS; control) was performed in rabbits ( $n = 42$ ) that underwent trabeculectomy [78]. These authors did report longer bleb survival in the BVZ group in comparison to the 5-FU and control groups, but the mean IOP across all groups was similar [78]. In a different study, subconjunctival injections of BVZ (1.25 mg) generated bigger and higher blebs and lower mean IOP in a rabbit model of filtration surgery, in comparison with intravitreal injections of BVZ, 5-FU, or BSS [79].

The use of anti-VEGF therapy for preventing bleb failure in patients undergoing single-site phacotrabeculectomy for primary open-angle glaucoma or chronic angle-closure glaucoma has been studied in a randomized controlled clinical trial [80]. In this pilot study, 38 patients were divided into three groups treated with conventional MMC application (0.03%), subconjunctival BVZ (1.25 mg/0.05 mL), or soaked sponges of BVZ (1.25 mg/mL). In both BVZ groups, bleb vascularity increased progressively over the 6-month follow-up. The authors concluded that in their small sample of patients, subconjunctival injections of BVZ (but not soaked sponges of BVZ) were equally effective in reducing IOP in comparison to MMC. The authors suggested that larger clinical trials with a similar study design are needed to corroborate these findings [81]. Tai



et al. reported a 6-month comparative results for patients with failed trabeculectomy and ExPRESS shunts treated with needling with BVZ and MMC versus needling with MMC alone. All patients received a subconjunctival injection of MMC (0.04 mg) at the beginning of the procedure. Then, they were randomized to receive either subconjunctival BVZ (1 mg) or BSS (control group) after the bleb needling. The difference in success rates between the groups was not statistically significant, despite the fact that the BVZ plus MMC group had blebs with less pronounced vascularity and greater extent [82].

A recent study by Pro et al. analyzed the efficacy and safety of intraoperative adjunctive RBZ versus MMC in primary glaucoma trabeculectomy surgery [83]. This prospective, open-label randomized pilot study included 24 patients who received a subconjunctival injection of RBZ (0.5 mg) or an MMC (0.4 mg/mL) soaked pledget inserted in the sub-Tenon space for 1.5 min during surgery, prior to creating the scleral flap. Reduction in IOP was only statistically significant in the MMC group. At 6 months, the RBZ group had more diffuse and less vascular blebs than the group with MMC alone. The authors reported that although large-scale studies are needed to recommend RBZ over MMC as the only surgical adjunctive, it is possible that the duration of action of a one-time subconjunctival injection was too short to influence long-term episcleral and subconjunctival wound healing.

Nilforushan et al. [84] compared the outcome of trabeculectomy with subconjunctival BVZ or MMC in a prospective, randomized, comparative study performed in 34 patients with uncontrolled glaucoma. An IOP reduction of 34% and 56% was reported at

6 months in the BVZ and MMC groups, respectively. These authors observed that the MMC group displayed significantly better IOP control whereas the BVZ group required more antiglaucoma medications for IOP control. In the study reported by Grewal et al. [85], 12 patients underwent trabeculectomy with subconjunctival BVZ (1.25 mg), and the mean IOP decreased from 24.4 mmHg to 11.6 mmHg (52%), with no medications at 6 months after surgery. Their results included one case of choroidal detachment. Akkan and Cilsim [86] reported the effectiveness of trabeculectomy with subconjunctival BVZ or MMC. These authors observed a significant reduction of IOP in both cases. There was a decrease in IOP of 41% after 1 year in the BVZ group and 46% in the MMC group. However the MMC group showed more effective control of IOP at levels below 12 mmHg and a higher number of patients required antiglaucoma medications in the BVZ group.

Recently, Kahook [87] investigated the outcomes of trabeculectomy using intraoperative intravitreal RBZ with topical MMC versus topical MMC alone. Both groups exhibited similar IOP control, but patients treated with combined intravitreal RBZ and topical MMC had more diffuse blebs with reduced vascularity. Some authors have compared the outcome of bleb revision with needling using BVZ versus MMC as an adjuvant [82, 88]. Both modalities were effective when employed concomitantly with needling, offering approximately 30% reduction compared to baseline IOP with the MMC exerting a longer-term effect consistent with the fact that it exerts a more permanent and irreversible cellular effect compared to BVZ. MMC inhibits conjunctival and scleral fibroblast proliferation at the surgical site but

may also cause a certain degree of ciliary body toxicity, thus decreasing aqueous humor production [89].

The route of administration may become an important consideration in the use of anti-VEGF agents. Intravitreal administration was demonstrated to be the most effective in rabbits [90]. However, subconjunctival administrations result in a longer half-life in both the iris/ciliary body and the retina/choroid, in comparison with intravitreal application. This effect can be explained by the storage effect afforded by the scleral tissue matrix. On the other hand, subconjunctival administrations offer direct modulation of the conjunctival wound-healing process. Although more research is needed to determine the optimal dose of BVZ in these settings, subconjunctival injections containing 1.25 or 2.5 mg of drug were most commonly employed [84, 86].

## SAFETY AND TOLERABILITY

As mentioned previously, in order to delay the wound-healing process, antimetabolites such as MMC and 5-FU have been used in trabeculectomy because of their inhibition of fibroblast migration and proliferation that would otherwise lead to scarring over the filtration site [91]. MMC is used intraoperatively more than twice as often as 5-FU [92] and has been shown to significantly reduce IOP and the risk of surgical failure in eyes that have undergone no previous surgery and in eyes at high risk of failure [93]. On the other hand, antimetabolites are associated with complications such as hypotony, cystic avascular bleb, bleb leak, bleb infection, and endophthalmitis [7–9]. Because of these, there is a need for more targeted and effective anti-scarring interventions. It has been proven

that at the filtration site, VEGF could modify fibroblast activity and stimulate collagen cross-linking and contraction, resulting in scar formation [77]. Moreover, higher VEGF levels in Tenon's tissue preoperatively are associated with a worse outcome following trabeculectomy surgery [9].

When using BVZ in filtration surgery, one should consider that in several of these studies bleb encapsulation is more frequent with BVZ compared to MMC. In addition, it has been suggested that MMC and 5-FU are more effective than BVZ at reducing IOP and achieving a diffuse filtering bleb in primary trabeculectomy [78, 84, 86, 94]. An explanation for this phenomenon involves the direct toxicity that MMC or 5-FU produces over the ciliary epithelium, which might decrease aqueous humor secretion and, subsequently, IOP.

Vandewalle et al. reported the interesting observation that bleb vascularity begins to increase 3 months after the administration of BVZ [95]. While this effect may decrease the incidence of cystic avascular blebs often developed following MMC-augmented surgery, it also raises concerns about possible bleb failure in the future. Similar observations were made by Sengupta et al. [80] after subconjunctival administration of BVZ: higher and more avascular blebs were present 1 month after treatment but the effect did not persist over a 6-month period. BVZ may have a limited activity to different subtypes of fibroblasts in encapsulating tissue or might not have a long enough duration of effect on inflammatory mediators.

A toxic effect of 5-FU and MMC on corneal endothelial cells has been described when these agents are administered as subconjunctival injections following filtration procedures. Consequently, the use of an anti-VEGF drug

and specifically BVZ may be a safer option with regard to corneal toxicity [96–98]. Additionally, subconjunctival injections of MMC may cause limbal stem cell deficiency [99]. In the study carried out by Sengupta et al. [80], no toxic effects of 1.25 mg of BVZ were seen in the corneal epithelium or endothelium. Moreover, after 6 months of follow-up, subconjunctival injections of BVZ had a slightly better safety profile compared to the application of sponges soaked with MMC or BVZ. In vitro studies have concluded that BVZ is not toxic to human corneal cells, including corneal endothelial cells, at doses often used for the treatment of corneal neovascularization [100]. A pilot study showed that BVZ eyedrops can sufficiently penetrate the corneal stroma and reach the anterior chamber when administered soon after alkali burns. The same study showed that BVZ eyedrops can significantly reduce corneal damage caused by alkalis [101].

In conclusion, several comparison studies have shown that the safety and efficacy of anti-VEGF therapy are not significantly different from those of current anti-scarring medications. Considering BVZ, it is an effective and safe agent commonly used in patients with retinal diseases and neovascularization of the anterior segment [102–104]. However, as an adjuvant for trabeculectomy, one should also consider the contraindications for its use, including pregnancy, breast feeding, uncontrolled systemic hypertension, and cerebrovascular accidents or transient ischemic attacks 1 month prior to injection. Moreover, complications such as conjunctival necrosis have been reported following subconjunctival BVZ [80] and intravitreal RBZ [105] injection. More specific anti-VEGF agents, possibly targeting VEGF<sub>189</sub>, could prove more potent and safer. In addition, agents with longer

duration of effect would be necessary for the long-term success of GFS.

A clinical study with a larger cohort and longer follow-up, such as the one described by Bochmann et al. [106], would confirm and more accurately highlight the role of anti-VEGF agents in glaucoma surgery. Moreover, targeting the wound-healing process with combination therapy using both anti-angiogenic and anti-fibrotic agents should be further investigated, as the processes of vessel formation and fibrosis occur at different times in the wound-healing cascade.

## ADVANTAGES AND POTENTIAL DRAWBACKS

A number of studies investigating the use of anti-VEGF agents or antimetabolites in GFS or the management of NVG have demonstrated that these medications can improve surgical outcomes. However, anti-VEGF agents have yet to demonstrate advantages over the more established anti-scarring agents commonly used.

On the other hand, the short-acting effect of anti-VEGF agents is an important inconvenience to consider. Histological studies have shown that maximum proliferation of subconjunctival fibroblasts, an important factor in bleb failure, occurs on the third to fifth postoperative day [107, 108]. Since it is known that the half-life of BVZ is 3–4 days, multiple injections of anti-angiogenic agents are needed to overcome this limitation. At the same time, the pharmacokinetics of BVZ after subconjunctival injections requires further study. The use of BVZ in glaucoma is currently off-label, and several issues need to be addressed in this regard, such as the duration of action and the profile of toxicity to the corneal endothelium, lens, and trabecular meshwork.

Liu and coworkers recently published a systematic review and meta-analysis of randomized controlled trials to compare the efficacy and safety of BVZ with MMC employed at different levels [109]. Results showed that while BVZ seemed to be an effective agent with regard to complete success rate, IOP, and antiglaucoma medication reduction when compared with placebo, it significantly increased the risk of bleb leakage and the rate of encysted blebs in the studies analyzed, in comparison with MMC as well. However, the authors recognized limitations in this study which have to be pointed out, such as the small sample size of the studies analyzed, the varying definitions of surgical success, the absence of patient stratification into different types of glaucoma or the risk of surgical failure, among others.

As mentioned above, the conventional treatment for NVG is PRP. However, a poor view of the retina may prevent adequate PRP. In these cases, intravitreal administration of anti-VEGF medications may prevent the growth of abnormal blood vessels. However, the possibility of adverse events related to the intravitreal route of administration has to be taken into account: conjunctival hemorrhage, eye pain, vitreous floaters, increased intraocular pressure, and intraocular inflammation [110]. Other less frequent but sight-threatening adverse events that may occur as a result of the intravitreal injection route include endophthalmitis and retinal detachment.

In summary, GFS augmented with antimetabolites may provide lower IOP but is more likely to cause hypotony or bleb-related complications. Therefore, anti-VEGF agents may have a dual role as postoperative wound-healing modulators as well as “antimetabolite-sparing” medications that may ensure smaller, and thus safer, doses of MMC or

5-FU can be used effectively. Further research on the surgical treatment of glaucoma with adjunctive use of anti-VEGF is needed. Additionally, side effects of repetitive anti-VEGF injections, including trabecular meshwork toxicity, should be investigated. Prospective randomized multicenter clinical trials are still lacking, and there is clearly a need for studies that will refine treatment protocols by examining safety and efficacy of different dosages, routes of delivery, or frequency of administration.

Considering NVG, unfortunately the existing literature showing excellent response to intravitreal anti-VEGF agents consists of retrospective studies or case series [57]. Well-designed, controlled, prospective studies are needed to confirm these results. Until evidence from high-quality studies becomes available, decisions in clinical practice will need to be based on the existing evidence, the physician's experience, and the patient's preferences.

## CURRENT AND FUTURE DEVELOPMENTS

The use of anti-VEGF agents in glaucoma filtration surgery and neovascular glaucoma needs to be supported by more evidence. Several issues have to be addressed such as the duration of action and the toxicity profile on corneal endothelium, lens, and trabecular meshwork. It is also important to precisely characterize the pharmacokinetics of the different antibodies and determine whether these molecules are capable of blocking all VEGF isomorphs at once. Considering BVZ, poor surgical results using a single dose may justify future trials using multiple doses. Notwithstanding cost, additional injections of BVZ in the postoperative period may improve

the survival of trabeculectomy to a degree comparable to that observed with MMC. In order to improve the efficacy of BVZ in this context, parameters such as dose, route of administration, and type of formulations will need to be considered in future studies.

The effects of anti-VEGF agents for treating NVG are temporary, generally lasting 4–6 weeks [111]. It is also known that anti-VEGF agents alone may not be sufficient to treat NVG caused by conditions with a prolonged natural history. Nonetheless, the combination of anti-VEGF and conventional treatments has the potential to be more effective than conventional treatments alone by virtue of a dual mechanism of action. A further advantage might also be that combined treatments with anti-VEGF and conventional treatments may offer a longer duration of action, allowing a longer interval between injections.

There is an increasingly apparent need for the development of novel systems that allow the delivery of anti-VEGF agents alone or in combination with conventional therapies. In this context, it is crucial that these therapeutic tools provide new alternatives with enhanced therapeutic effects and longer dosing intervals, thus allowing the attainment of therapeutic concentrations over an extended period of time. On the positive side, a wide range of formulations, biodegradable materials, and pharmaceutical technologies have currently reached different stages of development. It is only a matter of time before a viable alternative becomes clinically available.

## ACKNOWLEDGEMENTS

All named authors meet the International Committee of Medical Journal Editors (ICMJE) criteria for authorship for this manuscript, take

responsibility for the integrity of the work as a whole, and have given final approval for the version to be published. The authors would like to acknowledge the financial support from the Sanitary Research Institute of the San Carlos Clinical Hospital, the Ocular Pathology National Net OFTARED of the Institute of Health Carlos III (RD12/0034), the Research Group UCM 920415 (GR3/14), and the Spanish Ministry of Economy and Competitiveness MICINN (MAT 2013-43127R). No funding or sponsorship was received for the publication charges of this article.

**Disclosures.** V. Andrés-Guerrero, L. Perucho-González, J. García-Feijóo, L. Morales-Fernández, F. Saenz-Francés, R. Herrero-Vanrell, L. Pablo Júlvez, V. Polo Llorens, J. M. Martínez-de-la-Casa, and A. G. P. Konstas declare that they have no conflict of interest.

**Compliance with Ethics Guidelines.** This article is based on previously conducted studies, and does not involve any new studies of human or animal subjects performed by any of the authors.

**Data Availability.** Data sharing is not applicable to this article as no datasets were generated or analyzed during the current study.

**Open Access.** This article is distributed under the terms of the Creative Commons Attribution-NonCommercial 4.0 International License (<http://creativecommons.org/licenses/by-nc/4.0/>), which permits any non-commercial use, distribution, and reproduction in any medium, provided you give appropriate credit to the original author(s) and the source, provide a link to the Creative Commons license, and indicate if changes were made.

## REFERENCES

1. Quigley HA, Broman AT. The number of people with glaucoma worldwide in 2010 and 2020. *Br J Ophthalmol*. 2006;90(3):262–7.
2. European Glaucoma Society. Terminology and guidelines for glaucoma. 4th ed. Italy: PubliComm; 2014.
3. Salim S. Current variations of glaucoma filtration surgery. *Curr Opin Ophthalmol*. 2012;23(2):89–95.
4. Yu DY, Morgan WH, Sun X, et al. The critical role of the conjunctiva in glaucoma filtration surgery. *Prog Retin Eye Res*. 2009;28(5):303–28.
5. Lama PJ, Fechtner RD. Antifibrotics and wound healing in glaucoma surgery. *Surv Ophthalmol*. 2003;48(3):314–46.
6. Seibold LK, Sherwood MB, Kahook MY. Wound modulation after filtration surgery. *Surv Ophthalmol*. 2012;57(6):530–50.
7. Georgoulas S, Dahlmann-Noor A, Brocchini S, Khaw PT. Modulation of wound healing during and after glaucoma surgery. *Prog Brain Res*. 2008;173:237–54.
8. Jampel HD, Solus JF, Tracey PA, et al. Outcomes and bleb-related complications of trabeculectomy. *Ophthalmology*. 2012;119(4):712–22.
9. Saeedi OJ, Jefferys JL, Solus JF, Jampel HD, Quigley HA. Risk factors for adverse consequences of low intraocular pressure after trabeculectomy. *J Glaucoma*. 2014;23(1):e60–8.
10. Daneshvar R. Anti-VEGF agents and glaucoma filtering surgery. *J Ophthalmic Vis Res*. 2013;8(2):182–6.
11. Van Bergen T, Vandewalle E, Van de Veire S, et al. The role of different VEGF isoforms in scar formation after glaucoma filtration surgery. *Exp Eye Res*. 2011;93(5):689–99.
12. Horsley MB, Kahook MY. Anti-VEGF therapy for glaucoma. *Curr Opin Ophthalmol*. 2010;21(2):112–7.
13. Park SC, Su D, Tello C. Anti-VEGF therapy for the treatment of glaucoma: a focus on ranibizumab and bevacizumab. *Expert Opin Biol Ther*. 2012;12(12):1641–7.
14. Mathew R, Barton K. Anti-vascular endothelial growth factor therapy in glaucoma filtration surgery. *Am J Ophthalmol*. 2011;152(1):10–5.e2.
15. Ciulla TA, Rosenfeld PJ. Anti-vascular endothelial growth factor therapy for neovascular ocular diseases other than age-related macular degeneration. *Curr Opin Ophthalmol*. 2009;20(3):166–74.
16. Andreoli CM, Miller JW. Anti-vascular endothelial growth factor therapy for ocular neovascular disease. *Curr Opin Ophthalmol*. 2007;18(6):502–8.
17. SooHoo JR, Seibold LK, Kahook MY. Recent advances in the management of neovascular glaucoma. *Semin Ophthalmol*. 2013;28(3):165–72.
18. Kim M, Lee C, Payne R, Yue BY, Chang JH, Ying H. Angiogenesis in glaucoma filtration surgery and neovascular glaucoma: a review. *Surv Ophthalmol*. 2015;60(6):524–35.
19. Fong DS, Girach A, Boney A. Visual side effects of successful scatter laser photocoagulation surgery for proliferative diabetic retinopathy: a literature review. *Retina*. 2007;27(7):816–24.
20. Hasanreisoglu M, Weinberger D, Mimouni K, et al. Intravitreal bevacizumab as an adjunct treatment for neovascular glaucoma. *Eur J Ophthalmol*. 2009;19(4):607–12.
21. Marey HM, Ellakwa AF. Intravitreal bevacizumab with or without mitomycin C trabeculectomy in the treatment of neovascular glaucoma. *Clin Ophthalmol*. 2011;5:841–5.
22. Yuzbasioglu E, Artunay O, Rasier R, Sengul A, Bahcecioglu H. Simultaneous intravitreal and intracameral injection of bevacizumab (Avastin) in neovascular glaucoma. *J Ocul Pharmacol Ther*. 2009;25(3):259–64.
23. Kitnarong N, Sriyakul C, Chinwattanakul S. A prospective study to evaluate intravitreal ranibizumab as adjunctive treatment for trabeculectomy in neovascular glaucoma. *Ophthalmol Ther*. 2015;4(1):33–41.
24. Tolentino M. Systemic and ocular safety of intravitreal anti-VEGF therapies for ocular neovascular disease. *Surv Ophthalmol*. 2011;56(2):95–113.
25. SooHoo JR, Seibold LK, Pantcheva MB, Kahook MY. Aflibercept for the treatment of neovascular glaucoma. *Clin Experiment Ophthalmol*. 2015;43(9):803–7.
26. Keck PJ, Hauser SD, Krivi G, et al. Vascular permeability factor, an endothelial cell mitogen related to PDGF. *Science*. 1989;246(4935):1309–12.



27. Bao P, Kodra A, Tomic-Canic M, Golinko MS, Ehrlich HP, Brem H. The role of vascular endothelial growth factor in wound healing. *J Surg Res.* 2009;153(2):347–58.
28. Carmeliet P, Jain RK. Angiogenesis in cancer and other diseases. *Nature.* 2000;407(6801):249–57.
29. Pralhad T, Madhusudan S, Rajendrakumar K. Concept, mechanisms and therapeutics of angiogenesis in cancer and other diseases. *J Pharm Pharmacol.* 2003;55(8):1045–53.
30. Gluzman-Poltorak Z, Cohen T, Herzog Y, Neufeld G. Neuropilin-2 is a receptor for the vascular endothelial growth factor (VEGF) forms VEGF-145 and VEGF-165 [corrected]. *J Biol Chem.* 2000;275(24):18040–5.
31. Soker S, Miao HQ, Nomi M, Takashima S, Klagsbrun M. VEGF165 mediates formation of complexes containing VEGFR-2 and neuropilin-1 that enhance VEGF165-receptor binding. *J Cell Biochem.* 2002;85(2):357–68.
32. Presta LG, Chen H, O'Connor SJ, et al. Humanization of an anti-vascular endothelial growth factor monoclonal antibody for the therapy of solid tumors and other disorders. *Cancer Res.* 1997;57(20):4593–9.
33. Ferrara N, Gerber HP, LeCouter J. The biology of VEGF and its receptors. *Nat Med.* 2003;9(6):669–76.
34. Grisanti S, Ziemssen F. Bevacizumab: off-label use in ophthalmology. *Indian J Ophthalmol.* 2007;55(6):4.
35. Rodrigues EB, Farah ME, Maia M, et al. Therapeutic monoclonal antibodies in ophthalmology. *Prog Retin Eye Res.* 2009;28(2):117–44.
36. Gaudreault J, Fei D, Rusit J, Suboc P, Shiu V. Preclinical pharmacokinetics of ranibizumab (rhuFabV2) after a single intravitreal administration. *Invest Ophthalmol Vis Sci.* 2005;46(2):726–33.
37. Kaiser PK. Antivascular endothelial growth factor agents and their development: therapeutic implications in ocular diseases. *Am J Ophthalmol.* 2006;142(4):660–8.
38. Magdelaine-Beuzelin C, Pinault C, Paintaud G, Watier H. Therapeutic antibodies in ophthalmology: old is new again. *MAbs.* 2010;2(2):176–80.
39. Gaudreault J, Fei D, Beyer JC, et al. Pharmacokinetics and retinal distribution of ranibizumab, a humanized antibody fragment directed against VEGF-A, following intravitreal administration in rabbits. *Retina.* 2007;27(9):1260–6.
40. Bakri SJ, Snyder MR, Reid JM, Pulido JS, Ezzat MK, Singh RJ. Pharmacokinetics of intravitreal ranibizumab (Lucentis). *Ophthalmology.* 2007;114(12):2179–82.
41. Holash J, Davis S, Papadopoulos N, Croll SD, Ho L, Russell M, et al. VEGF-Trap: a VEGF blocker with potent antitumor effects. *Proc Natl Acad Sci USA.* 2002;99(17):11393–8.
42. Rudge JS, Holash J, Hylton D, et al. VEGF trap complex formation measures production rates of VEGF, providing a biomarker for predicting efficacious angiogenic blockade. *Proc Natl Acad Sci USA.* 2007;104(47):18363–70.
43. Meyer T, Robles-Carrillo L, Robson T, et al. Bevacizumab immune complexes activate platelets and induce thrombosis in FCGR2A transgenic mice. *J Thromb Haemost.* 2009;7(1):171–81.
44. Hayreh SS. Neovascular glaucoma. *Prog Retin Eye Res.* 2007;26(5):470–85.
45. Sivak-Callcott JA, O'Day DM, Gass JD, Tsai JC. Evidence-based recommendations for the diagnosis and treatment of neovascular glaucoma. *Ophthalmology.* 2001;108(10):1767–76 (**quiz 77, 800**).
46. Chalam KV, Brar VS, Murthy RK. Human ciliary epithelium as a source of synthesis and secretion of vascular endothelial growth factor in neovascular glaucoma. *JAMA Ophthalmol.* 2014;132(11):1350–4.
47. Shweiki D, Itin A, Soffer D, Keshet E. Vascular endothelial growth factor induced by hypoxia may mediate hypoxia-initiated angiogenesis. *Nature.* 1992;359(6398):843–5.
48. Carmeliet P, Ferreira V, Breier G, et al. Abnormal blood vessel development and lethality in embryos lacking a single VEGF allele. *Nature.* 1996;380(6573):435–9.
49. Goishi K, Klagsbrun M. Vascular endothelial growth factor and its receptors in embryonic zebrafish blood vessel development. *Curr Top Dev Biol.* 2004;62:127–52.
50. Alvarez Arroyo MV, Caramelo C, Angeles Castilla M, González Pacheco FR, Martín O, Arias J. Role of vascular endothelial growth factor in the response to vessel injury. *Kidney Int Suppl.* 1998;68:S7–9.
51. Leung DW, Cachianes G, Kuang WJ, Goeddel DV, Ferrara N. Vascular endothelial growth factor is a

- secreted angiogenic mitogen. *Science*. 1989;246(4935):1306–9.
52. Yoshida A, Anand-Apte B, Zetter BR. Differential endothelial migration and proliferation to basic fibroblast growth factor and vascular endothelial growth factor. *Growth Factors*. 1996;13(1–2):57–64.
53. Brkovic A, Sirois MG. Vascular permeability induced by VEGF family members in vivo: role of endogenous PAF and NO synthesis. *J Cell Biochem*. 2007;100(3):727–37.
54. Griffioen AW, Molema G. Angiogenesis: potentials for pharmacologic intervention in the treatment of cancer, cardiovascular diseases, and chronic inflammation. *Pharmacol Rev*. 2000;52(2):237–68.
55. Alon T, Hemo I, Itin A, Pe'er J, Stone J, Keshet E. Vascular endothelial growth factor acts as a survival factor for newly formed retinal vessels and has implications for retinopathy of prematurity. *Nat Med*. 1995;1(10):1024–8.
56. Gupta N, Mansoor S, Sharma A, et al. Diabetic retinopathy and VEGF. *Open Ophthalmol J*. 2013;7:4–10.
57. Simha A, Braganza A, Abraham L, Samuel P, Lindsley K. Anti-vascular endothelial growth factor for neovascular glaucoma. *Cochrane Database Syst Rev*. 2013;10:CD007920.
58. Gulati N, Forooghian F, Lieberman R, Jabs DA. Vascular endothelial growth factor inhibition in uveitis: a systematic review. *Br J Ophthalmol*. 2011;95(2):162–5.
59. Waisbourd M, Shemesh G, Kurtz S, et al. Topical bevacizumab for neovascular glaucoma: a pilot study. *Pharmacology*. 2014;93(3–4):108–12.
60. Duch S, Buchacra O, Milla E, Andreu D, Tellez J. Intracameral bevacizumab (Avastin) for neovascular glaucoma: a pilot study in 6 patients. *J Glaucoma*. 2009;18(2):140–3.
61. Grisanti S, Biester S, Peters S, et al. Intracameral bevacizumab for iris rubeosis. *Am J Ophthalmol*. 2006;142(1):158–60.
62. Lüke J, Nassar K, Lüke M, Grisanti S. Ranibizumab as adjuvant in the treatment of rubeosis iridis and neovascular glaucoma—results from a prospective interventional case series. *Graefes Arch Clin Exp Ophthalmol*. 2013;251(10):2403–13.
63. Grover S, Gupta S, Sharma R, Brar VS, Chalam KV. Intracameral bevacizumab effectively reduces aqueous vascular endothelial growth factor concentrations in neovascular glaucoma. *Br J Ophthalmol*. 2009;93(2):273–4.
64. Yazdani S, Hendi K, Pakravan M, Mahdavi M, Yaseri M. Intravitreal bevacizumab for neovascular glaucoma: a randomized controlled trial. *J Glaucoma*. 2009;18(8):632–7.
65. Sugimoto Y, Mochizuki H, Okumichi H, et al. Effect of intravitreal bevacizumab on iris vessels in neovascular glaucoma patients. *Graefes Arch Clin Exp Ophthalmol*. 2010;248(11):1601–9.
66. Saito Y, Higashide T, Takeda H, Murotani E, Ohkubo S, Sugiyama K. Clinical factors related to recurrence of anterior segment neovascularization after treatment including intravitreal bevacizumab. *Am J Ophthalmol*. 2010;149(6):964–72.e1.
67. Guo S, Dipietro LA. Factors affecting wound healing. *J Dent Res*. 2010;89(3):219–29.
68. Cantor LB, Mantravadi A, WuDunn D, Swamynathan K, Cortes A. Morphologic classification of filtering blebs after glaucoma filtration surgery: the Indiana Bleb Appearance Grading Scale. *J Glaucoma*. 2003;12(3):266–71.
69. Uchida K, Uchida S, Nitta K, Yumura W, Marumo F, Nihei H. Glomerular endothelial cells in culture express and secrete vascular endothelial growth factor. *Am J Physiol*. 1994;266(1 Pt 2):F81–8.
70. Berse B, Brown LF, Van de Water L, Dvorak HF, Senger DR. Vascular permeability factor (vascular endothelial growth factor) gene is expressed differentially in normal tissues, macrophages, and tumors. *Mol Biol Cell*. 1992;3(2):211–20.
71. Nissen NN, Polverini PJ, Koch AE, Volin MV, Gamelli RL, DiPietro LA. Vascular endothelial growth factor mediates angiogenic activity during the proliferative phase of wound healing. *Am J Pathol*. 1998;152(6):1445–52.
72. Banks RE, Forbes MA, Kinsey SE, et al. Release of the angiogenic cytokine vascular endothelial growth factor (VEGF) from platelets: significance for VEGF measurements and cancer biology. *Br J Cancer*. 1998;77(6):956–64.
73. Gaudry M, Brégerie O, Andrieu V, El Benna J, Pocard MA, Hakim J. Intracellular pool of vascular endothelial growth factor in human neutrophils. *Blood*. 1997;90(10):4153–61.
74. Stavri GT, Zachary IC, Baskerville PA, Martin JF, Erusalimsky JD. Basic fibroblast growth factor upregulates the expression of vascular endothelial growth factor in vascular smooth muscle cells. Synergistic interaction with hypoxia. *Circulation*. 1995;92(1):11–4.

75. Costa VP, Spaeth GL, Eiferman RA, Orengo-Nania S. Wound healing modulation in glaucoma filtration surgery. *Ophthalmic Surg.* 1993;24(3):152–70.
76. Lopilly Park HY, Kim JH, Ahn MD, Park CK. Level of vascular endothelial growth factor in Tenon tissue and results of glaucoma surgery. *Arch Ophthalmol.* 2012;130(6):685–9.
77. Li Z, Van Bergen T, Van de Veire S, et al. Inhibition of vascular endothelial growth factor reduces scar formation after glaucoma filtration surgery. *Invest Ophthalmol Vis Sci.* 2009;50(11):5217–25.
78. Memarzadeh F, Varma R, Lin LT, et al. Postoperative use of bevacizumab as an antifibrotic agent in glaucoma filtration surgery in the rabbit. *Invest Ophthalmol Vis Sci.* 2009;50(7):3233–7.
79. Ozgonul C, Mumcuoglu T, Gunal A. The effect of bevacizumab on wound healing modulation in an experimental trabeculectomy model. *Curr Eye Res.* 2014;39(5):451–9.
80. Sengupta S, Venkatesh R, Ravindran RD. Safety and efficacy of using off-label bevacizumab versus mitomycin C to prevent bleb failure in a single-site phacotrabeculectomy by a randomized controlled clinical trial. *J Glaucoma.* 2012;21(7):450–9.
81. Sengupta S. Reply to “safety and efficacy of using off-label bevacizumab versus mitomycin C to prevent bleb failure in a single site phacotrabeculectomy by a randomized controlled clinical trial”. *J Glaucoma.* 2013;22(3):266–7.
82. Tai TY, Moster MR, Pro MJ, Myers JS, Katz LJ. Needle bleb revision with bevacizumab and mitomycin C compared with mitomycin C alone for failing filtration blebs. *J Glaucoma.* 2015;24(4):311–5.
83. Pro MJ, Freidl KB, Neylan CJ, Sawchyn AK, Wizov SS, Moster MR. Ranibizumab versus mitomycin C in primary trabeculectomy—a pilot study. *Curr Eye Res.* 2015;40(5):510–5.
84. Nilforushan N, Yadgari M, Kish SK, Nassiri N. Subconjunctival bevacizumab versus mitomycin C adjunctive to trabeculectomy. *Am J Ophthalmol.* 2012;153(2):352–7.e1.
85. Grewal DS, Jain R, Kumar H, Grewal SP. Evaluation of subconjunctival bevacizumab as an adjunct to trabeculectomy a pilot study. *Ophthalmology.* 2008;115(12):2141–5.e2.
86. Akkan JU, Cilsim S. Role of subconjunctival bevacizumab as an adjuvant to primary trabeculectomy: a prospective randomized comparative 1-year follow-up study. *J Glaucoma.* 2015;24(1):1–8.
87. Kahook MY. Bleb morphology and vascularity after trabeculectomy with intravitreal ranibizumab: a pilot study. *Am J Ophthalmol.* 2010;150(3):399–403.e1.
88. Franco L, Rassi B, Avila MP, Magacho L. Prospective study comparing mitomycin C or bevacizumab as adjuvant in trabeculectomy revision by needling. *Eur J Ophthalmol.* 2015;26(3):221–5.
89. Mietz H. The toxicology of mitomycin C on the ciliary body. *Curr Opin Ophthalmol.* 1996;7(2):72–9.
90. Nomoto H, Shiraga F, Kuno N, et al. Pharmacokinetics of bevacizumab after topical, subconjunctival, and intravitreal administration in rabbits. *Invest Ophthalmol Vis Sci.* 2009;50(10):4807–13.
91. Khaw PT, Sherwood MB, MacKay SL, Rossi MJ, Schultz G. Five-minute treatments with fluorouracil, floxuridine, and mitomycin have long-term effects on human Tenon’s capsule fibroblasts. *Arch Ophthalmol.* 1992;110(8):1150–4.
92. Kirwan JF, Lockwood AJ, Shah P, et al. Trabeculectomy in the 21st century: a multicenter analysis. *Ophthalmology.* 2013;120(12):2532–9.
93. Wilkins M, Indar A, Wormald R. Intra-operative mitomycin C for glaucoma surgery. *Cochrane Database Syst Rev.* 2005;4:CD002897.
94. Jurkowska-Dudzińska J, Kosior-Jarecka E, Zarnowski T. Comparison of the use of 5-fluorouracil and bevacizumab in primary trabeculectomy: results at 1 year. *Clin Exp Ophthalmol.* 2012;40(4):e135–42.
95. Vandewalle E, Abegão Pinto L, Van Bergen T, et al. Intracameral bevacizumab as an adjunct to trabeculectomy: a 1-year prospective, randomised study. *Br J Ophthalmol.* 2014;98(1):73–8.
96. Lattanzio FA, Sheppard JD, Allen RC, Baynham S, Samuel P, Samudre S. Do injections of 5-fluorouracil after trabeculectomy have toxic effects on the anterior segment? *J Ocul Pharmacol Ther.* 2005;21(3):223–35.
97. Cui LJ, Sun NX, Li XH, Huang J, Yang JG. Subconjunctival sustained release 5-fluorouracil for glaucoma filtration surgery. *Acta Pharmacol Sin.* 2008;29(9):1021–8.
98. Mietz H, Roters S, Krieglstein GK. Bullous keratopathy as a complication of trabeculectomy with mitomycin C. *Graefes Arch Clin Exp Ophthalmol.* 2005;243(12):1284–7.

- 
99. Hau S, Barton K. Corneal complications of glaucoma surgery. *Curr Opin Ophthalmol.* 2009;20(2):131–6.
  100. Yoeruek E, Spitzer MS, Tatar O, Aisenbrey S, Bartz-Schmidt KU, Szurman P. Safety profile of bevacizumab on cultured human corneal cells. *Cornea.* 2007;26(8):977–82.
  101. Yoeruek E, Ziemssen F, Henke-Fahle S, et al. Safety, penetration and efficacy of topically applied bevacizumab: evaluation of eyedrops in corneal neovascularization after chemical burn. *Acta Ophthalmol.* 2008;86(3):322–8.
  102. Avery RL, Pearlman J, Pieramici DJ, et al. Intravitreal bevacizumab (Avastin) in the treatment of proliferative diabetic retinopathy. *Ophthalmology.* 2006;113(10):1695.e1–15.
  103. Rich RM, Rosenfeld PJ, Puliafito CA, et al. Short-term safety and efficacy of intravitreal bevacizumab (Avastin) for neovascular age-related macular degeneration. *Retina.* 2006;26(5):495–511.
  104. Kahook MY, Schuman JS, Noecker RJ. Intravitreal bevacizumab in a patient with neovascular glaucoma. *Ophthalmic Surg Lasers Imaging.* 2006;37(2):144–6.
  105. Georgalas I, Papaconstantinou D, Tservakis I, Koutsandrea C, Ladas I. Severe hypotony and filtering bleb leak after intravitreal injection of ranibizumab. *Ther Clin Risk Manag.* 2009;5(1):17–9.
  106. Bochmann F, Kaufmann C, Becht CN, et al. ISRCTN12125882—influence of topical anti-VEGF (Ranibizumab) on the outcome of filtration surgery for glaucoma—study protocol. *BMC Ophthalmol.* 2011;11:1.
  107. Wong J, Wang N, Miller JW, Schuman JS. Modulation of human fibroblast activity by selected angiogenesis inhibitors. *Exp Eye Res.* 1994;58(4):439–51.
  108. Kano MR, Morishita Y, Iwata C, et al. VEGF-A and FGF-2 synergistically promote neoangiogenesis through enhancement of endogenous PDGF-B-PDGFRbeta signaling. *J Cell Sci.* 2005;118(Pt 16):3759–68.
  109. Liu X, Du L, Li N. The effects of bevacizumab in augmenting trabeculectomy for glaucoma: a systematic review and meta-analysis of randomized controlled trials. *Medicine (Baltimore).* 2016;95(15):e3223.
  110. Schmucker C, Loke YK, Ehlken C, et al. Intravitreal bevacizumab (Avastin) versus ranibizumab (Lucentis) for the treatment of age-related macular degeneration: a safety review. *Br J Ophthalmol.* 2011;95(3):308–17.
  111. Wakabayashi T, Oshima Y, Sakaguchi H, et al. Intravitreal bevacizumab to treat iris neovascularization and neovascular glaucoma secondary to ischemic retinal diseases in 41 consecutive cases. *Ophthalmology.* 2008;115(9):1571–80, 80.e1-3.