

# ANEXOS

Grado en odontología



**Universidad**  
Zaragoza

**Facultad de**  
**Ciencias de la Salud**  
**y del Deporte - Huesca**  
**Universidad Zaragoza**

# **ANEXO**

## **(Caso 1)** **(NHC:4111)**

En este anexo se encuentran las radiografías y pruebas diagnósticas descritas en la memoria de fin de grado.

Figura 1 :Frontal reposo

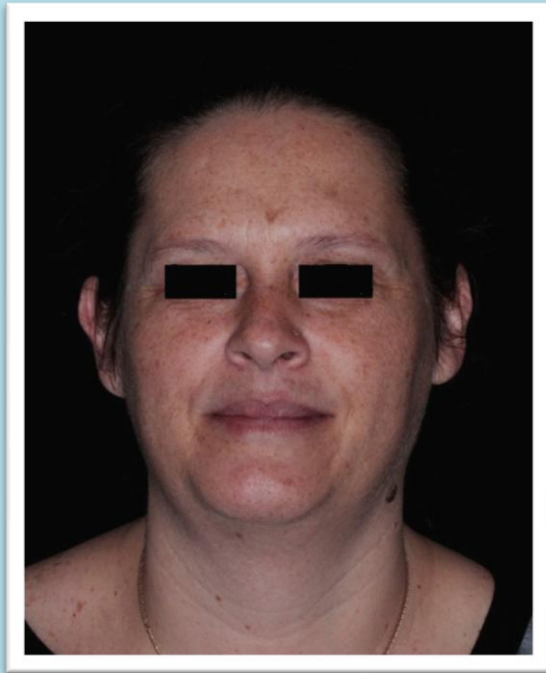


Figura 2: Frontal sonriendo

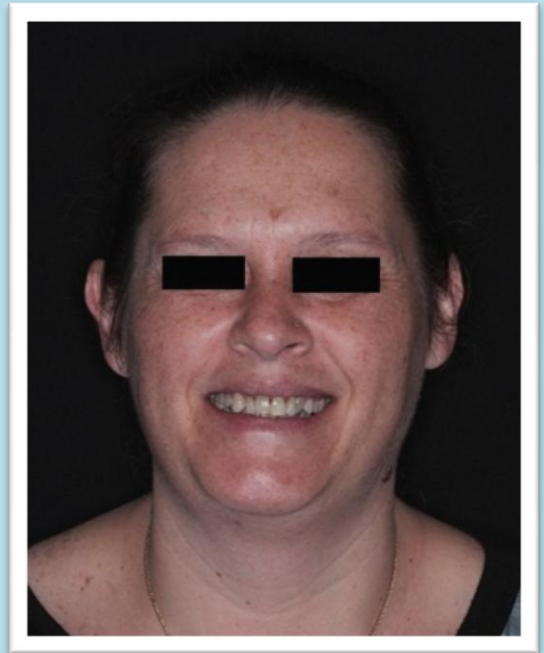

Figura 3: Análisis tercios

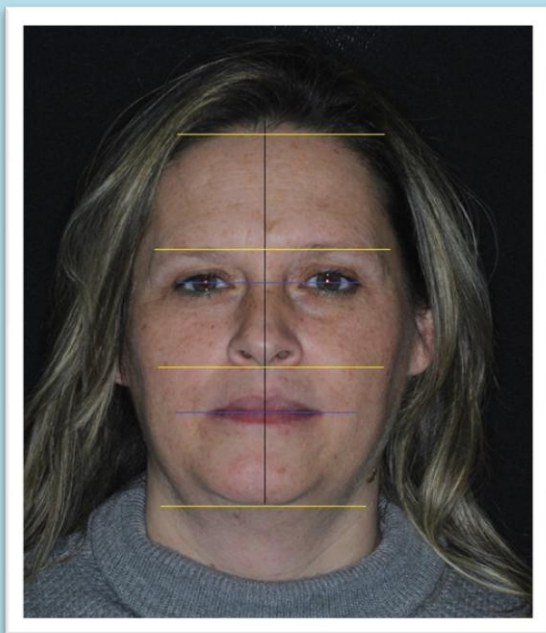


Figura 4: simetrías verticales

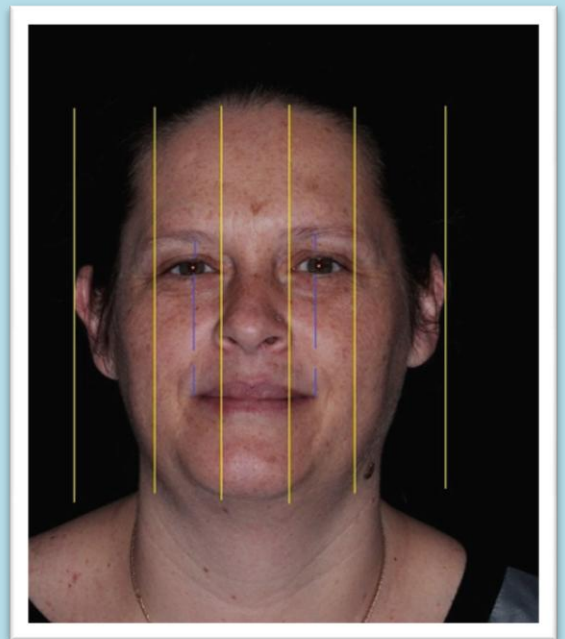


Figura 5: lateral en reposo

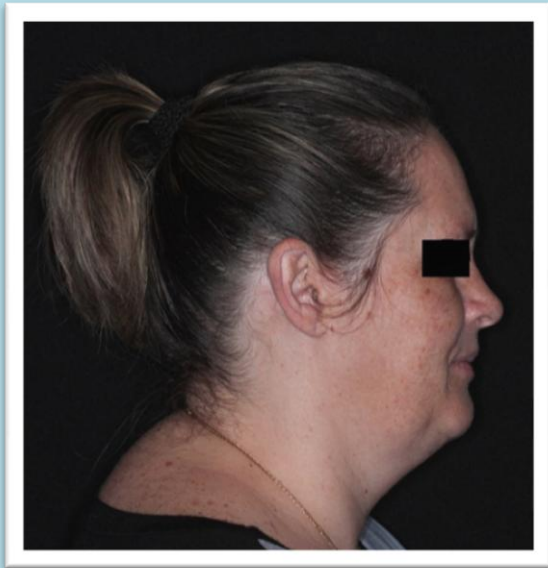

Figura 6: lateral sonriendo

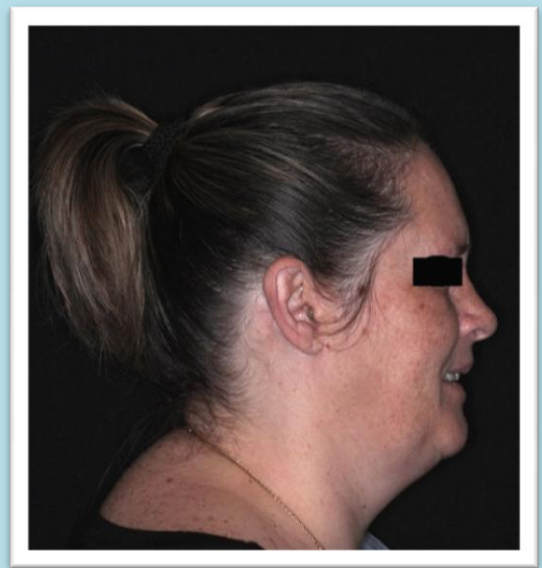

Figura 7: Análisis lateral

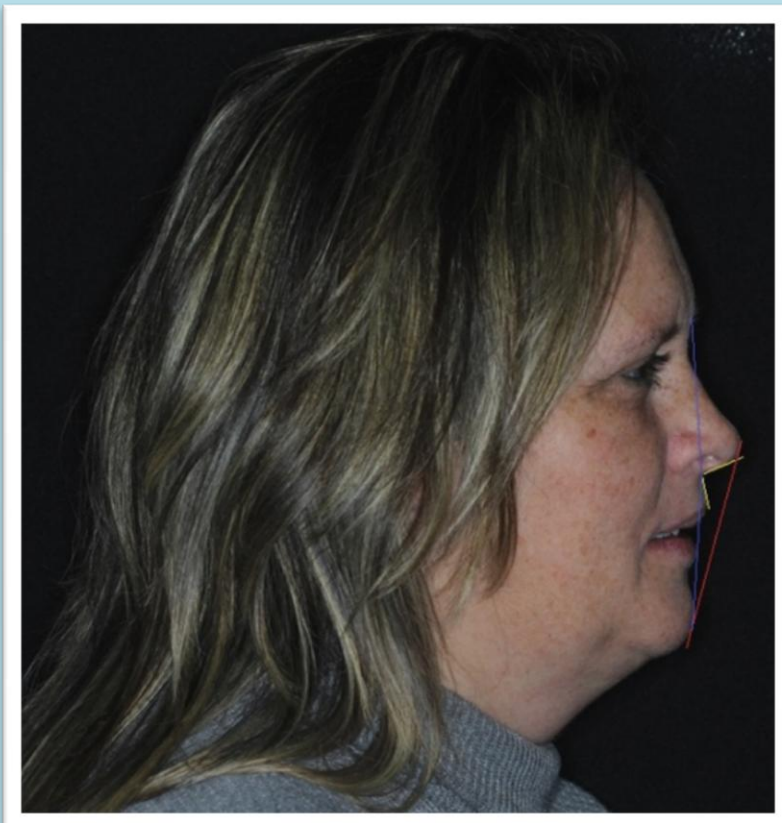

Figura 8: 3/4 en reposo

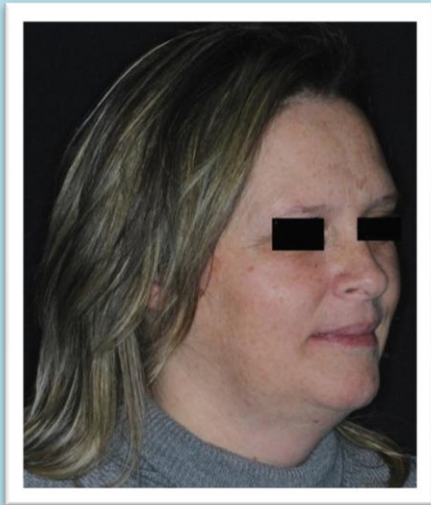

Figura 9: 3/4 en sonrisa

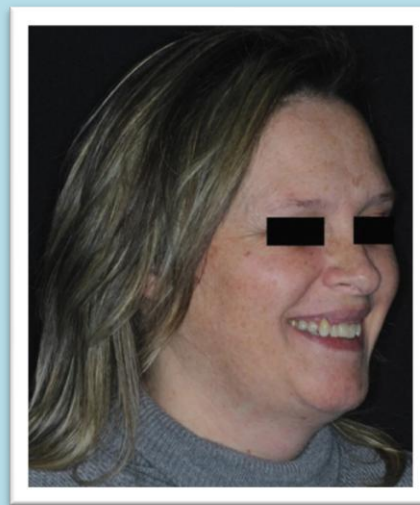


Figura 10: oclusal superior

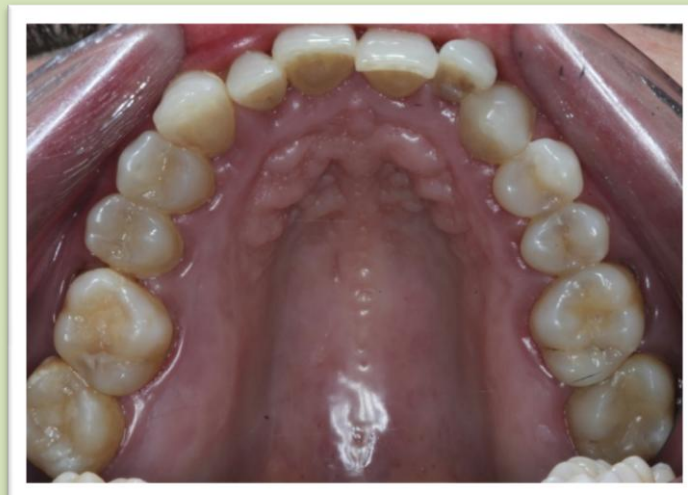

Figura 11: oclusal inferior

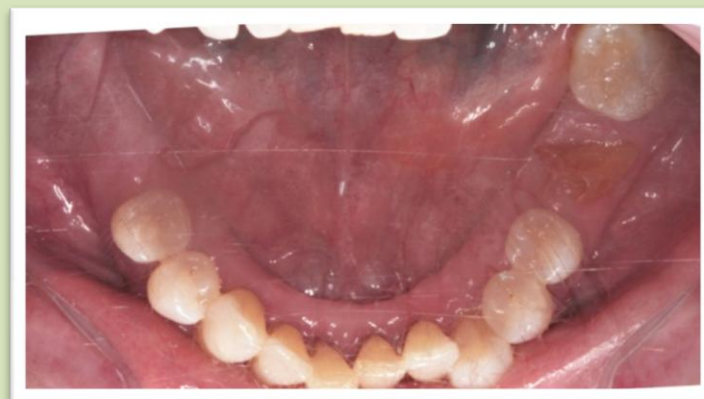

Figura 12: Intraoral frontal

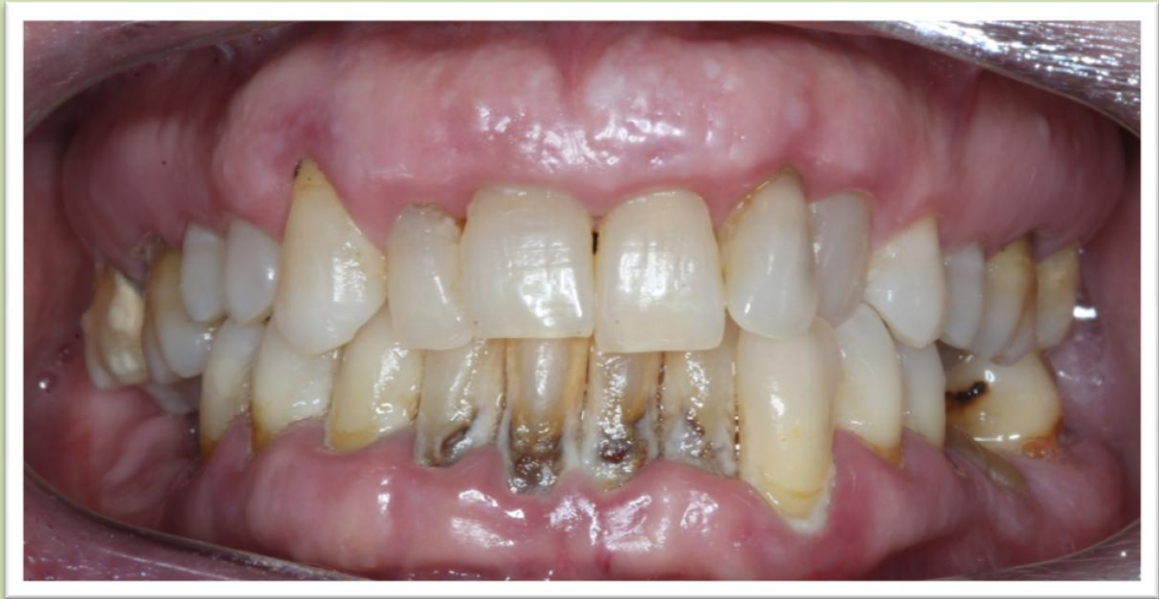

Figura 13: lateral izquierda

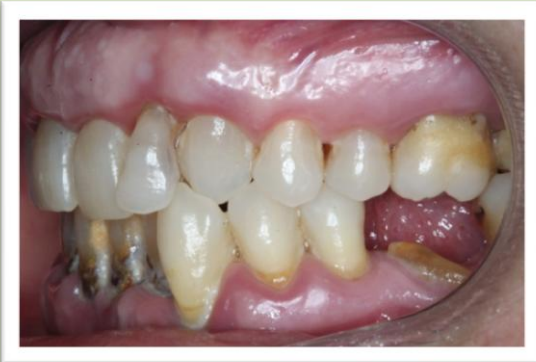

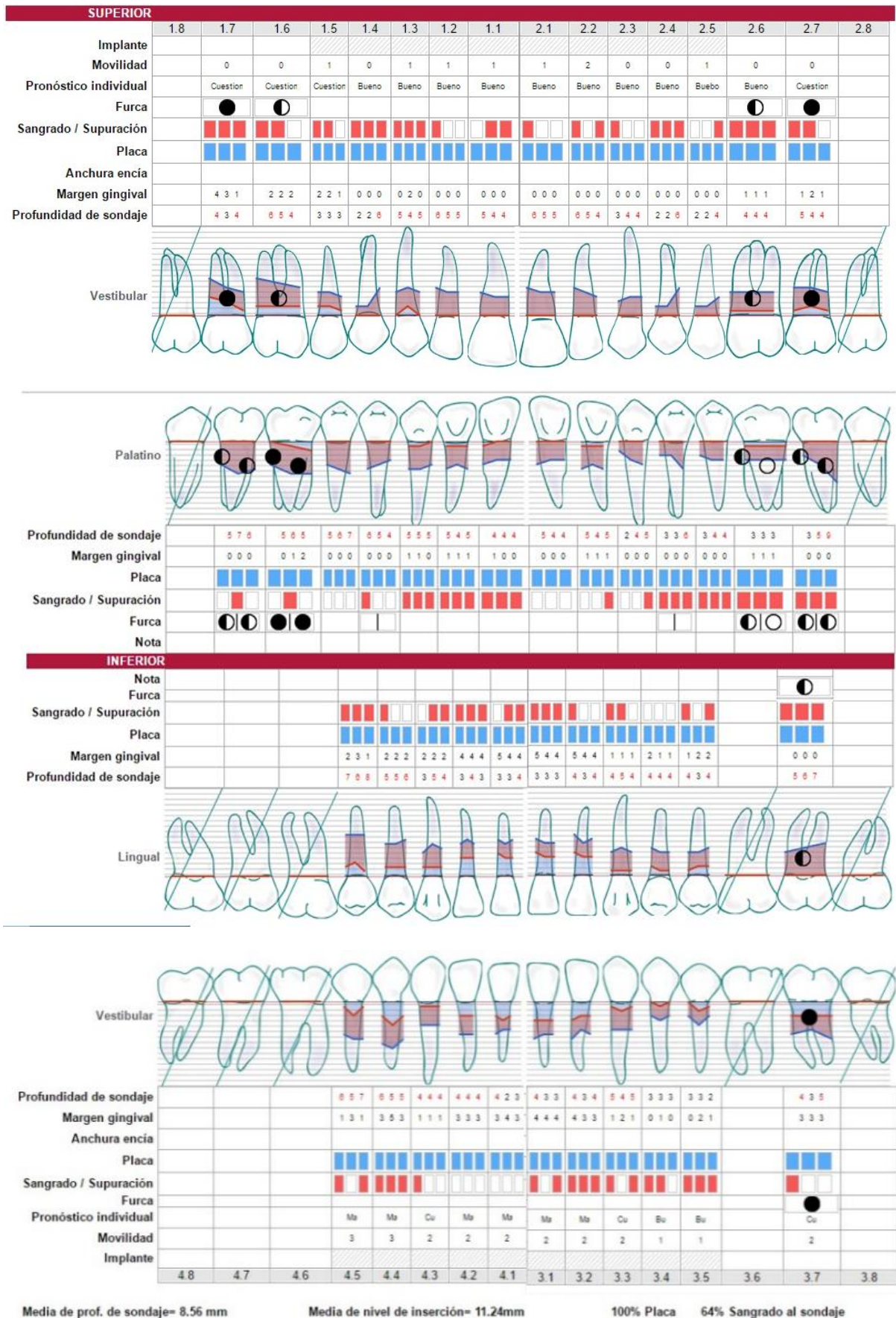
Figura 14: lateral derecha

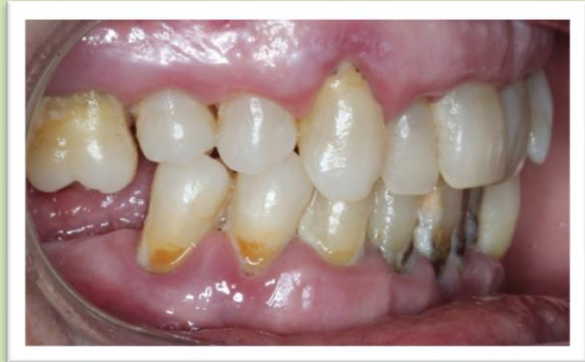
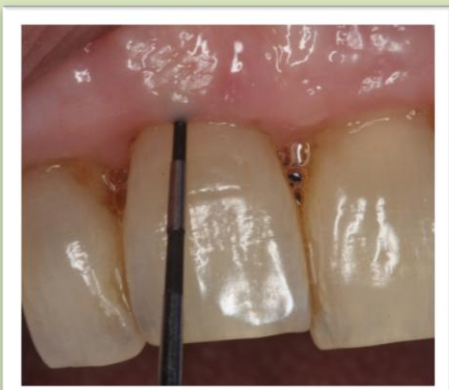
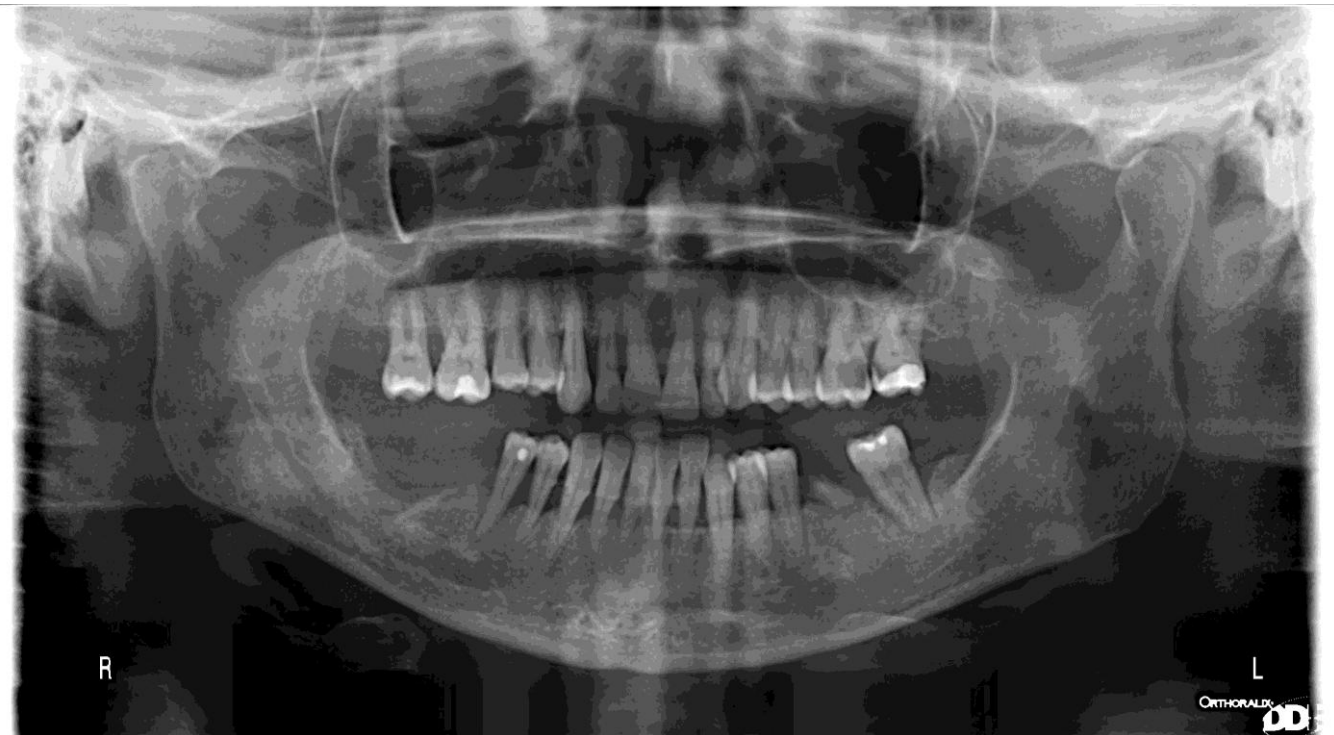Figura 15: biotipo gingival



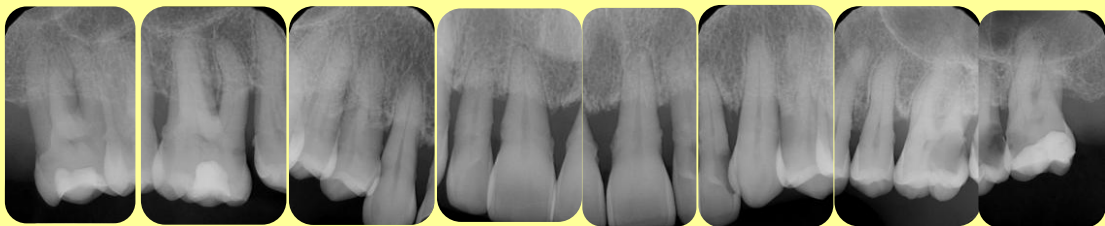
**Figura 16: periodontograma inicial**



**Figura 17: (Ortopantomografía)**



**Figura 18: fotos periapicales arcada superior**



**Figura 19: fotos periapicales arcada inferior**

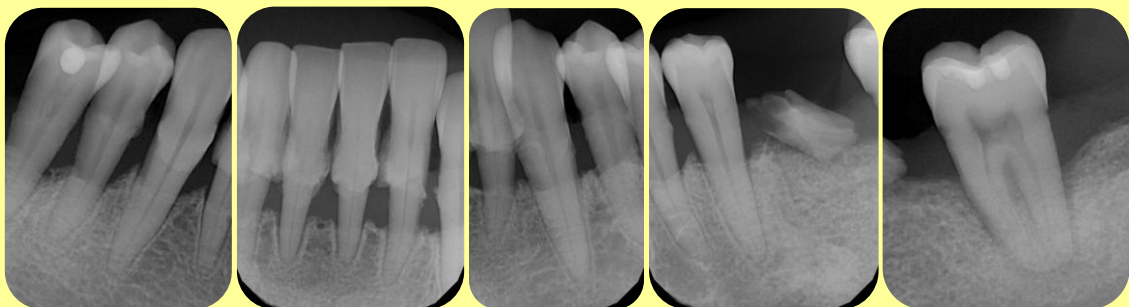
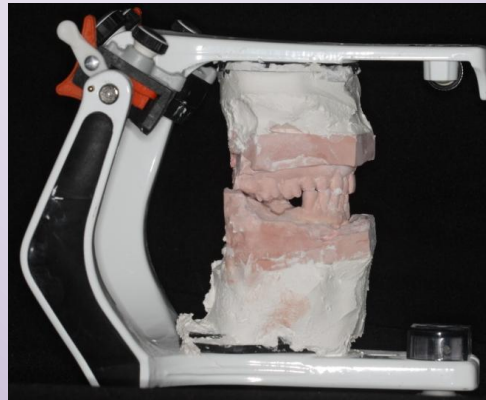




Figura 20: Modelos de yeso

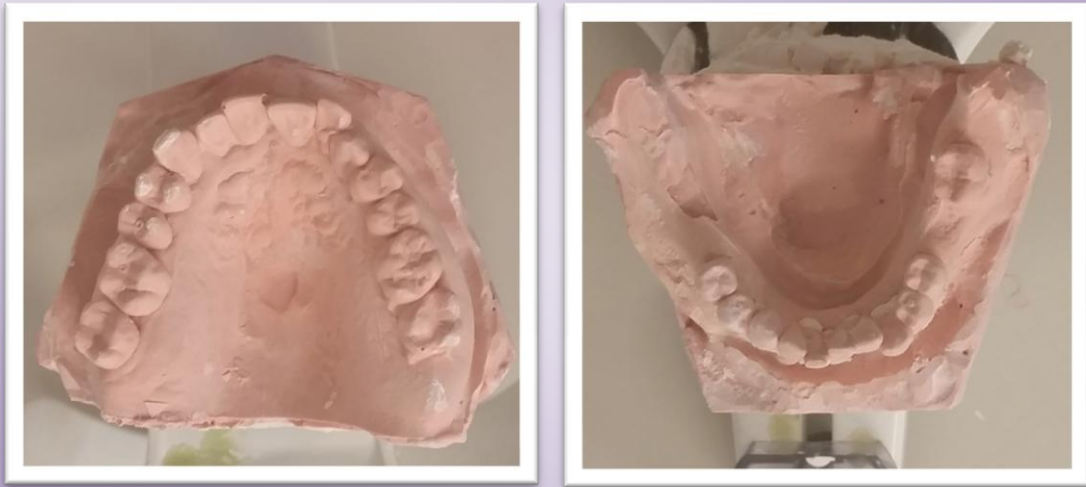

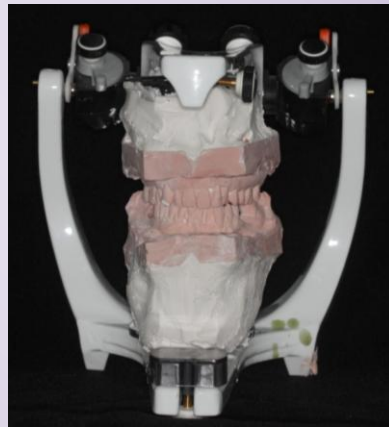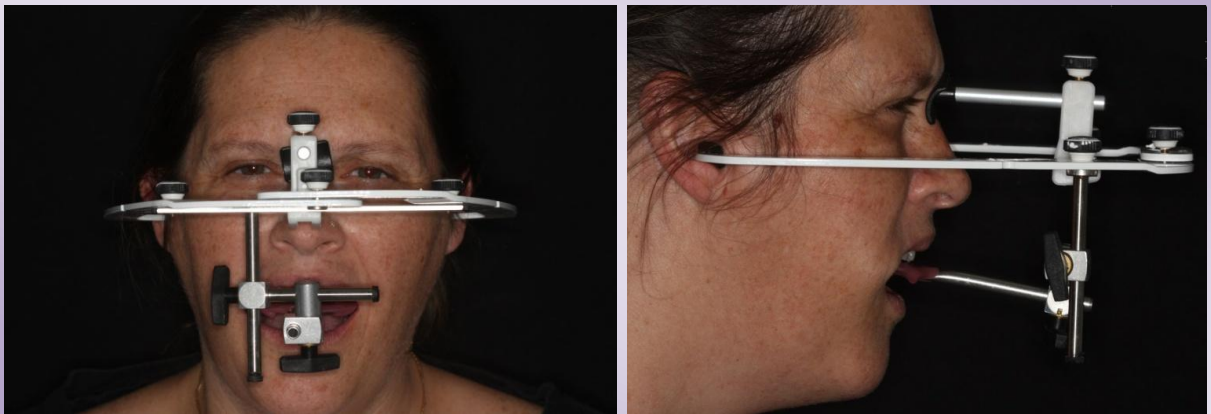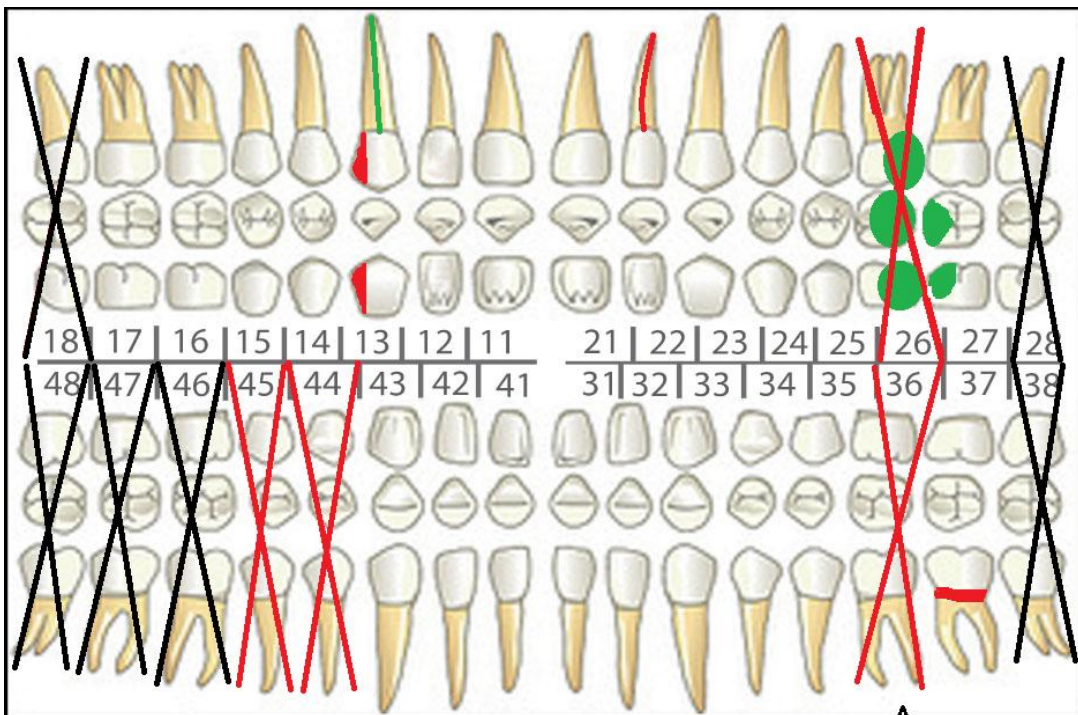
Figura 21: Articulador



**Figura 21b: Arco facial**



**Figura 22: Odontograma**



↑  
Restos radiculares

Figura 23: Profilaxis

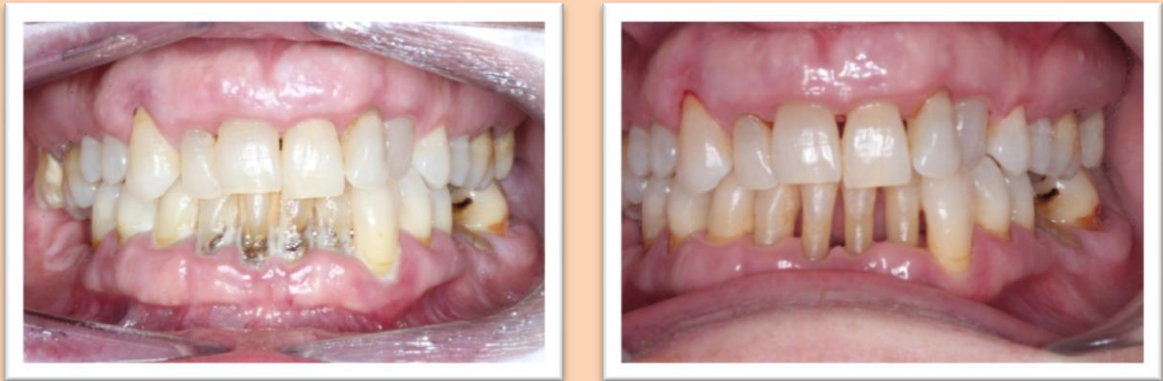

Figura 24: Periodontograma

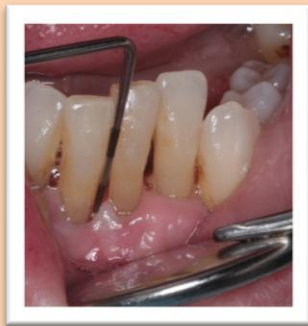

Figura 25: extracción del 4.4 y 4.5

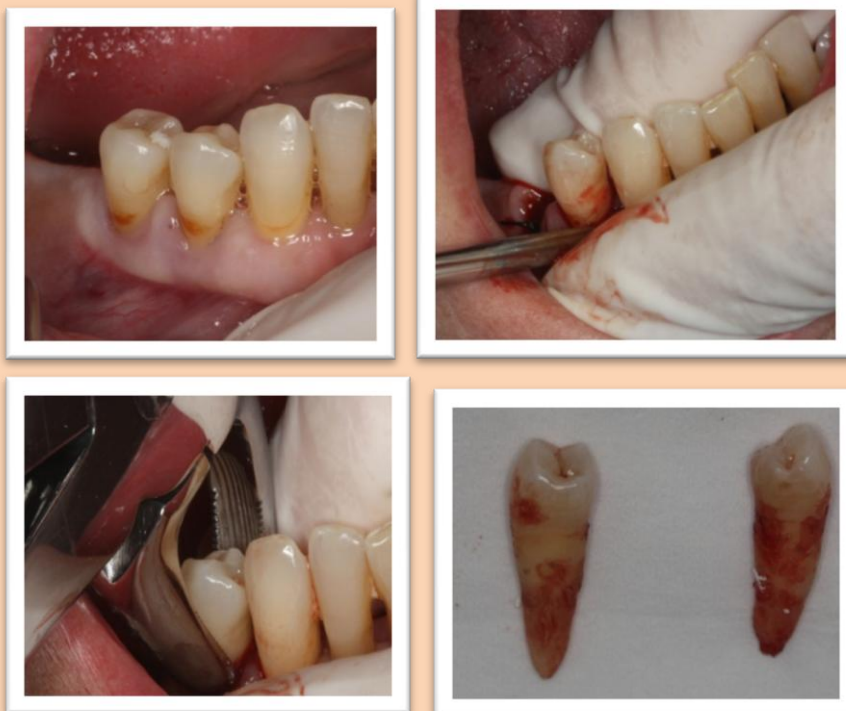

Figura 26: Extracción del 26

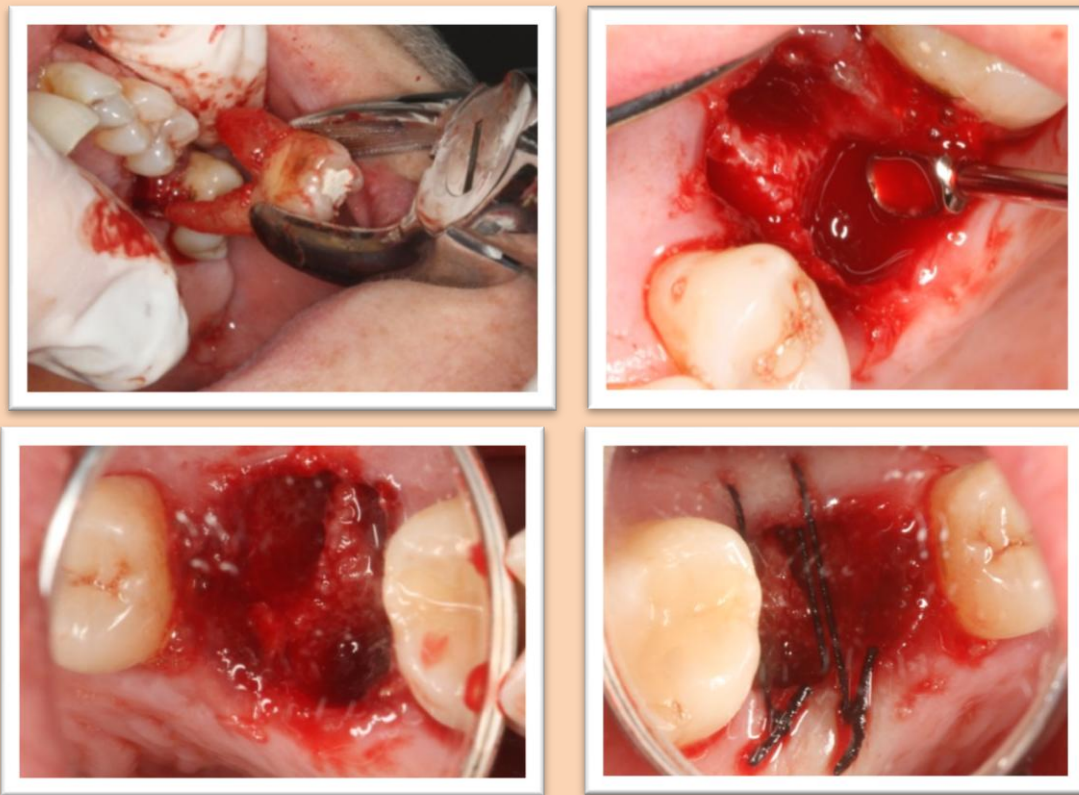
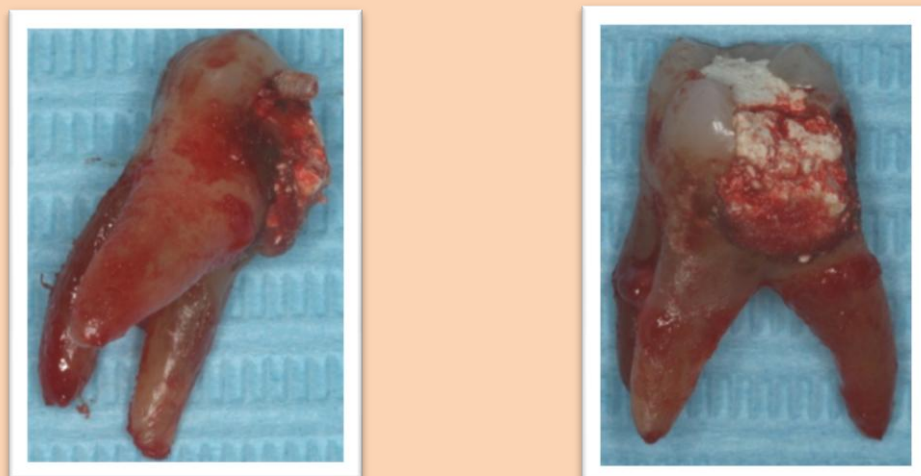
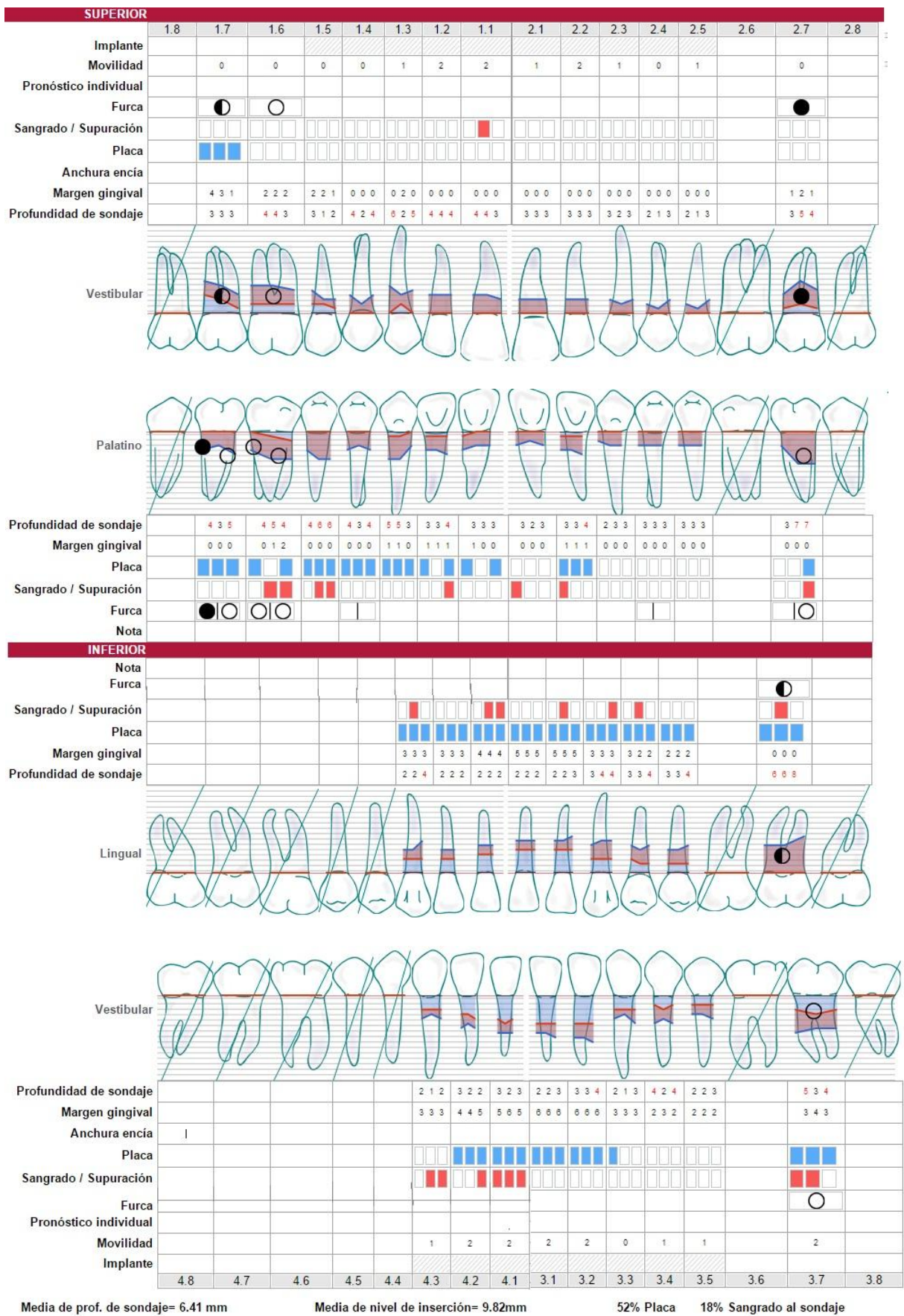


Figura 26a: diente extraído (con el cavit de la apertura cameral)



**Figura 27 : periodontograma de reevaluación**



# **Anexo I**

**(CASO 2)**

**(NHC: 4116)**

Figura 1: Frontal reposo

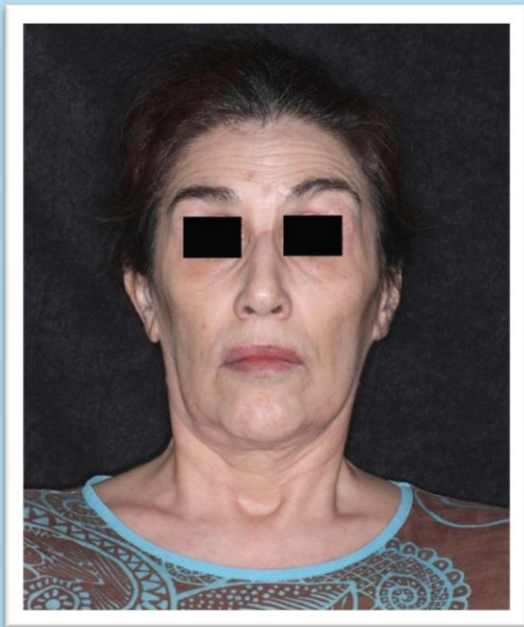


Figura 2 :Frontal sonrisa

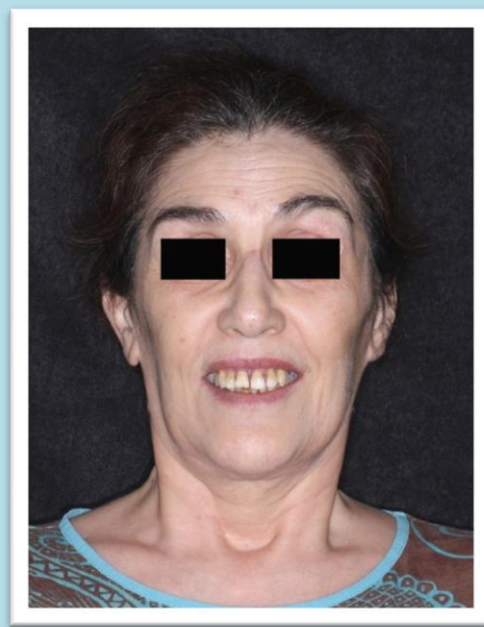


Figura 3: análisis proporciones

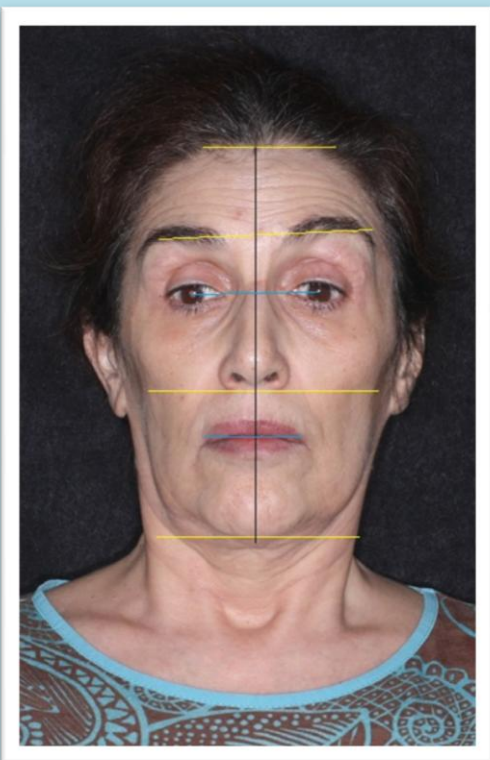


Figura 4: análisis simetría facial

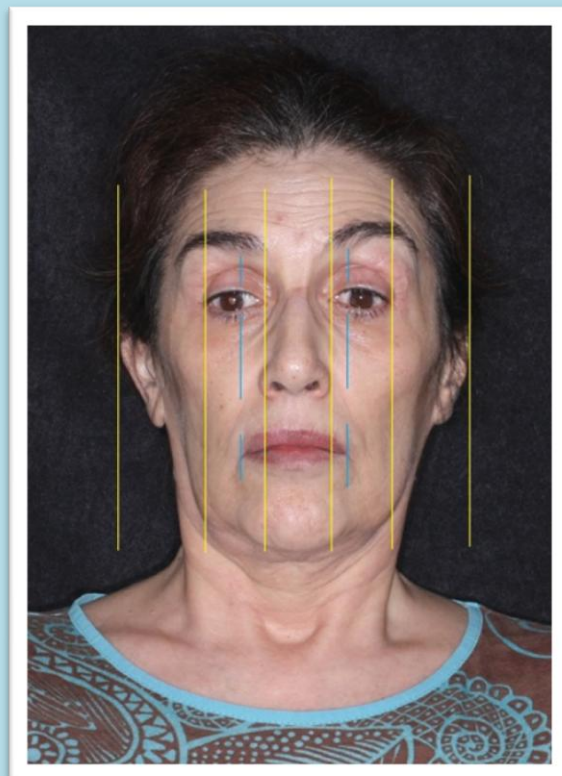


Figura 5: lateral en reposo

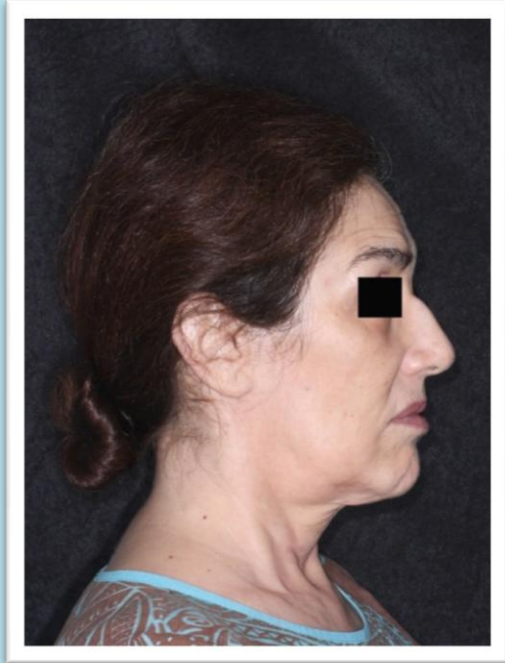

Figura 6: lateral en sonrisa

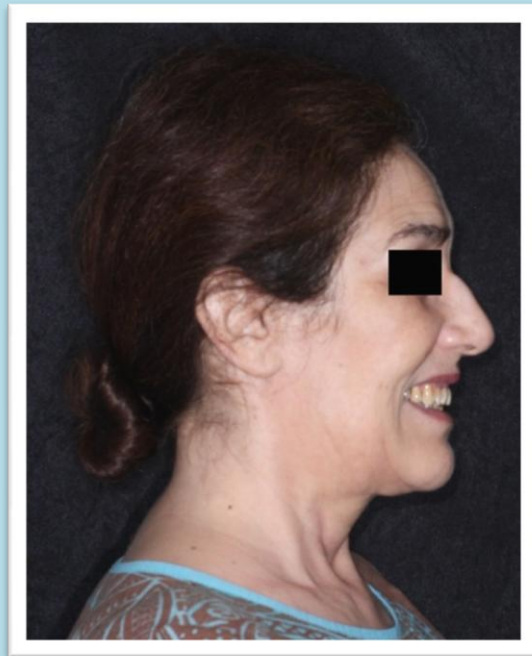


Figura 7: análisis del perfil

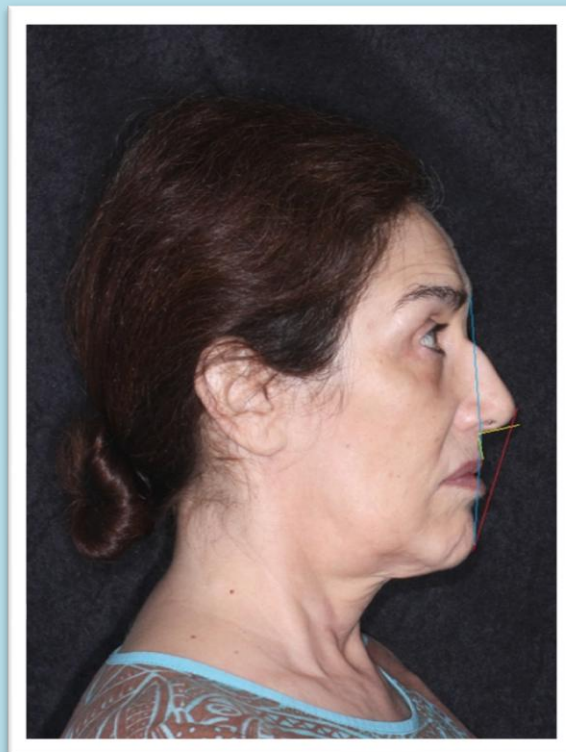



Figura 8: 3/4 en reposo

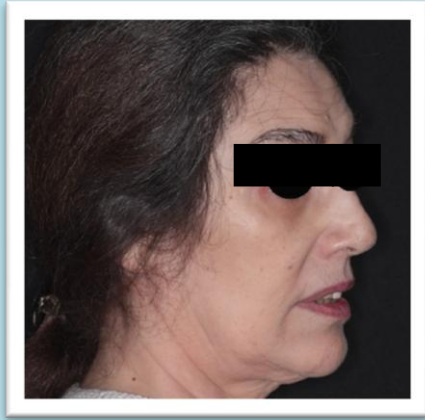

Figura 9: 3/4 en sonrisa

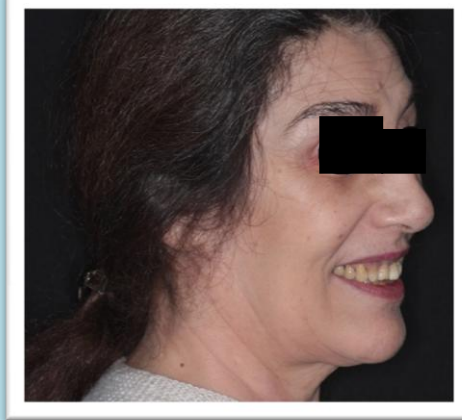

Figura 10: oclusal superior

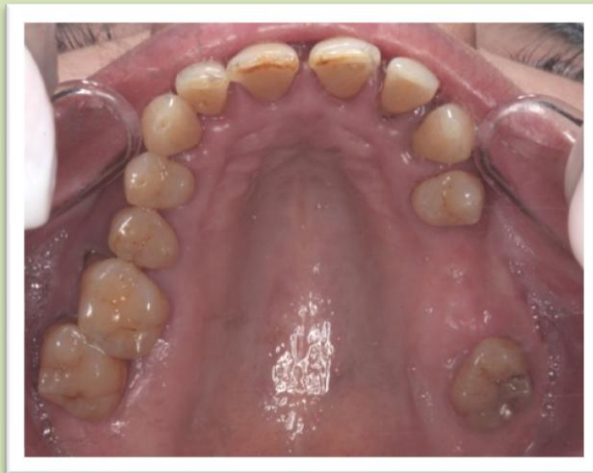

Figura 11: oclusal inferior

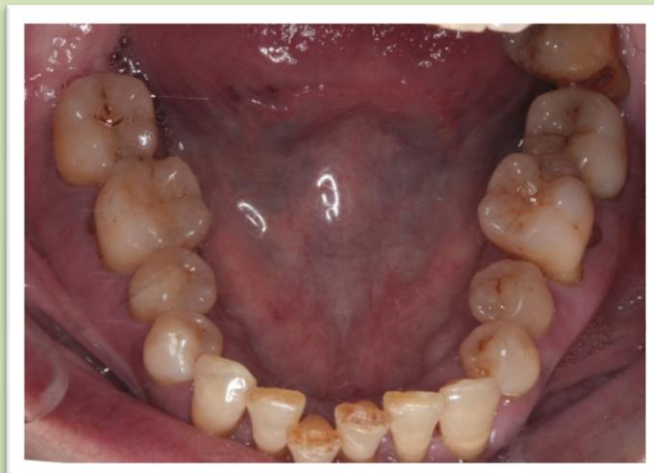

Figura 12: intraoral frontal

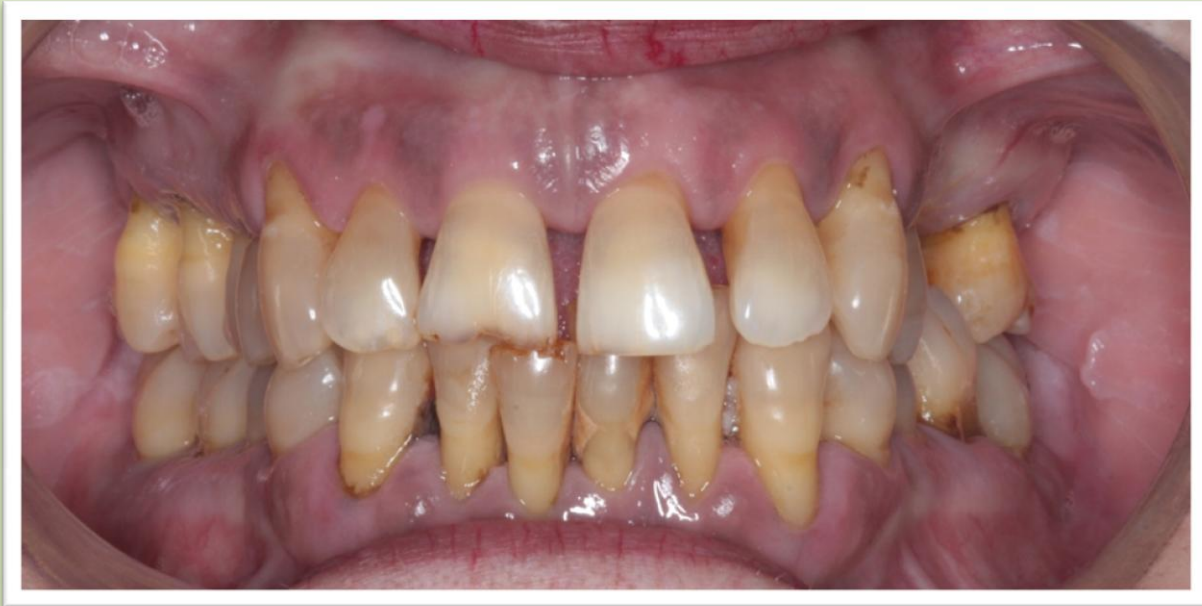

Figura 13: lateral izquierda

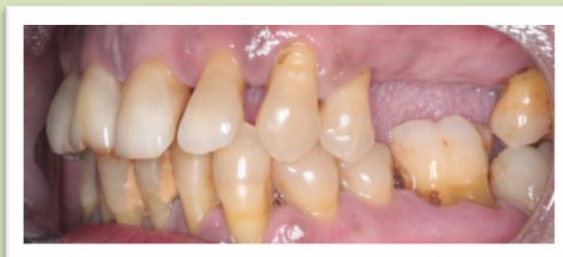
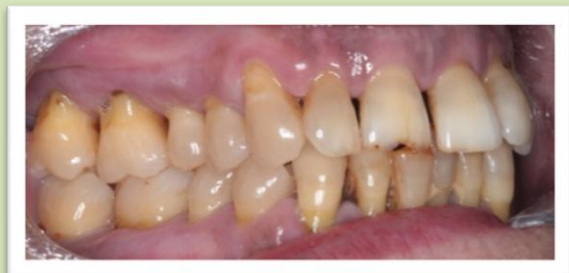
Figura 14: lateral derecha



# Figura 15: periodontograma inicial

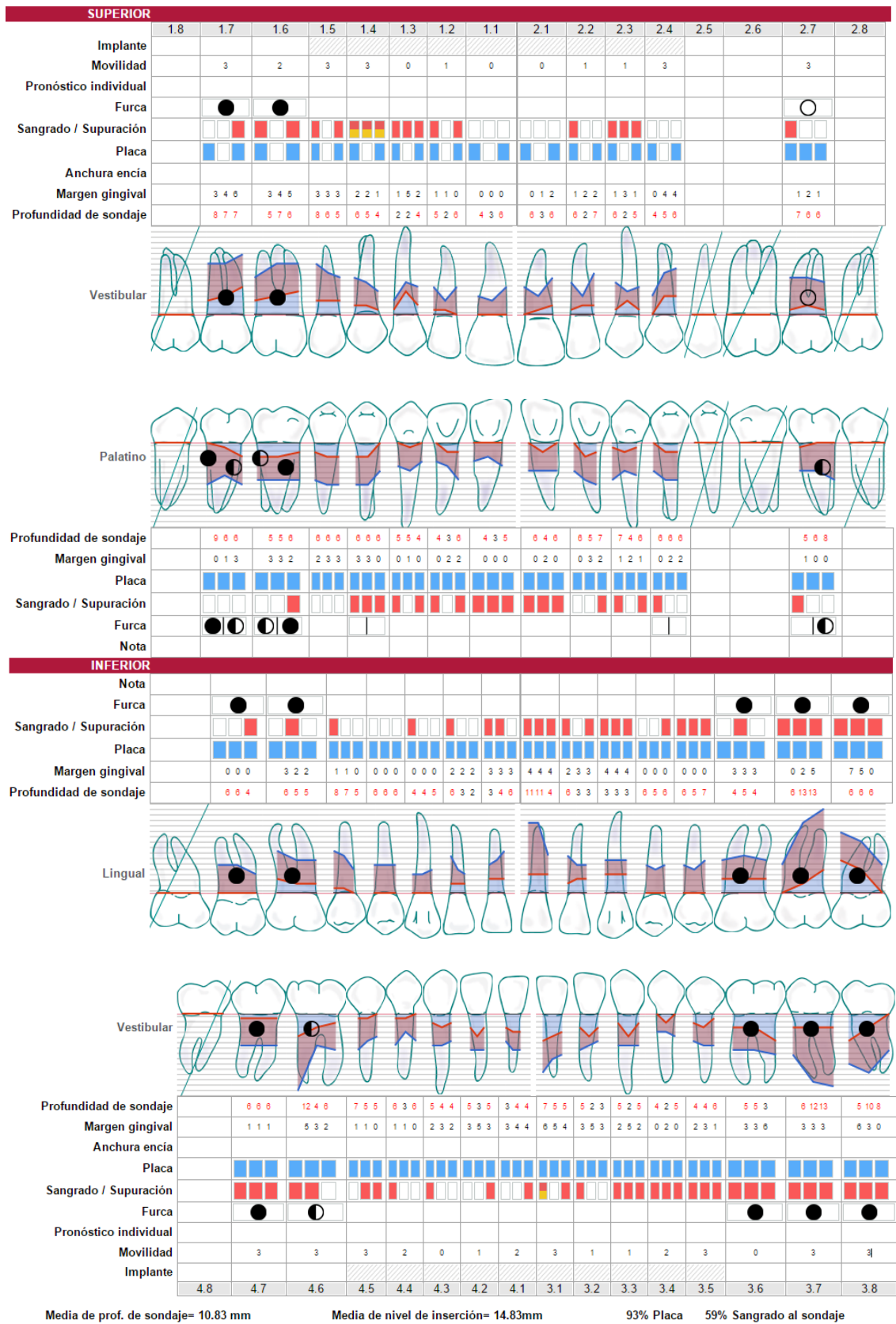


Figura 17: periodontograma

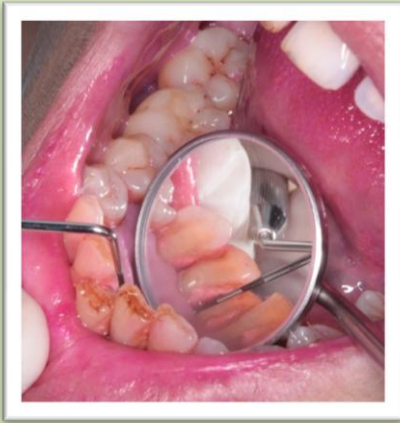
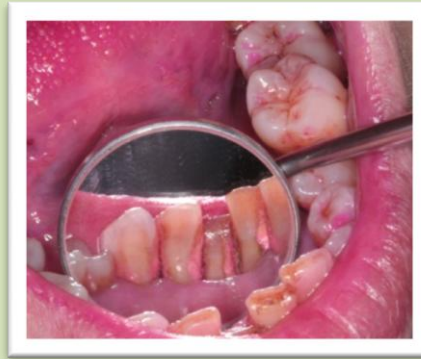
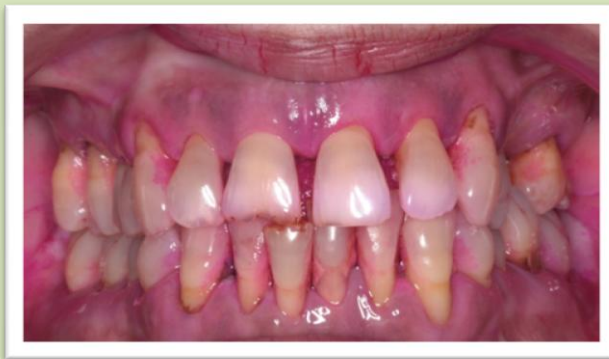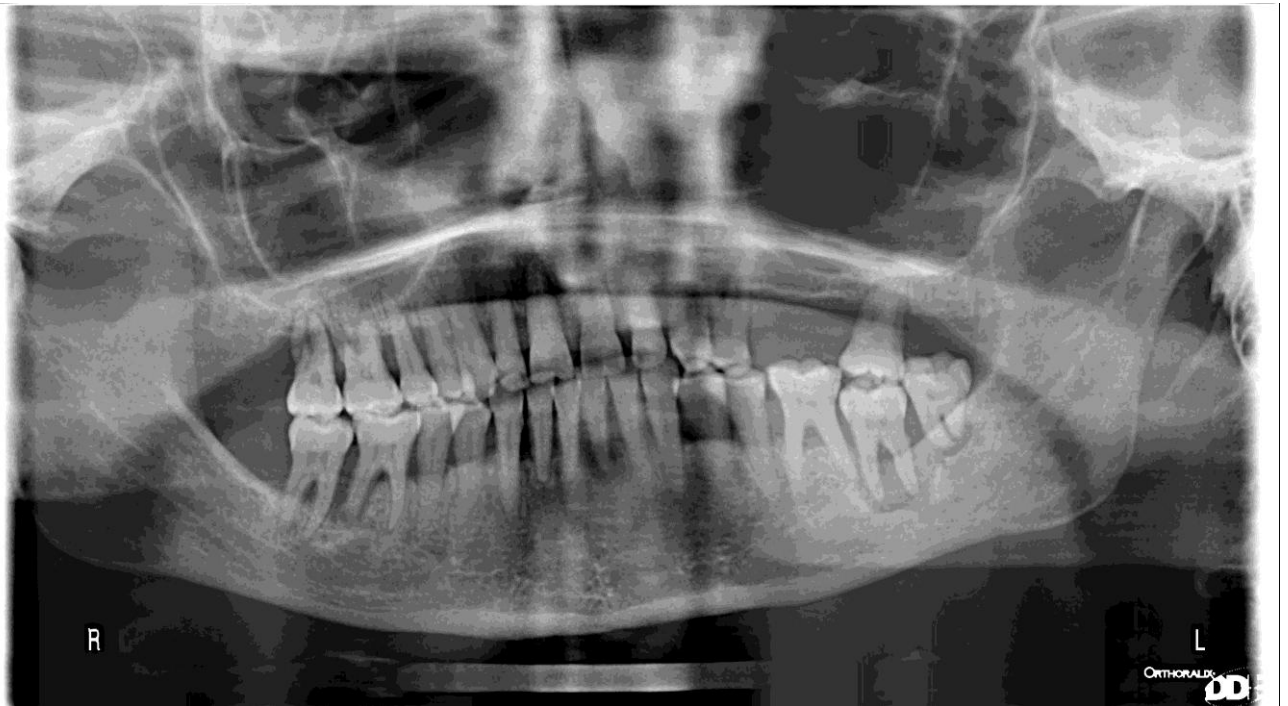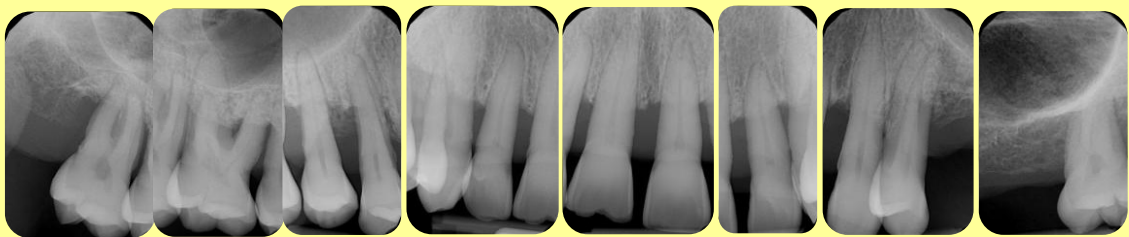
Figura 18: Índice de placa



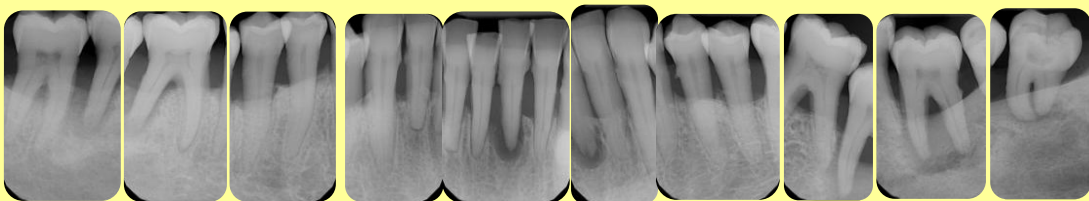
**Figura 19:(ortopantomografía)**



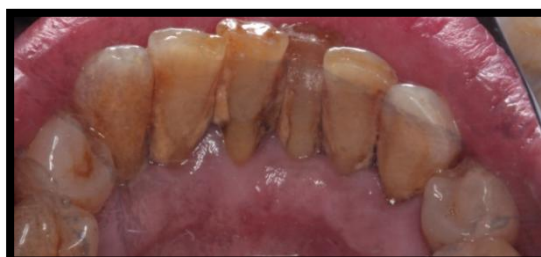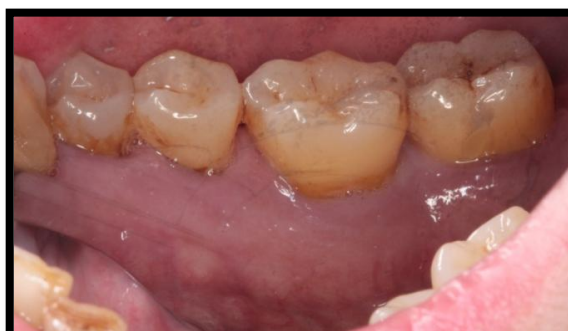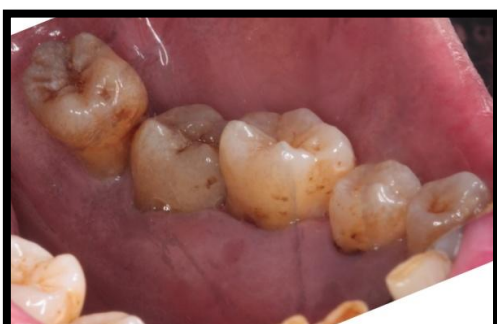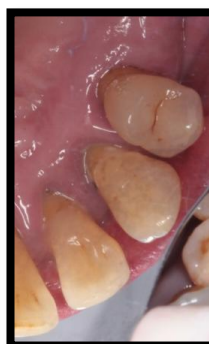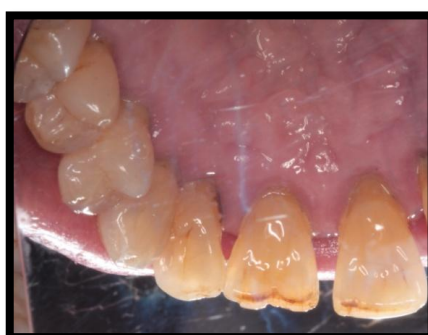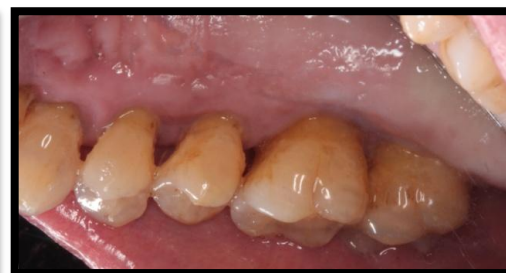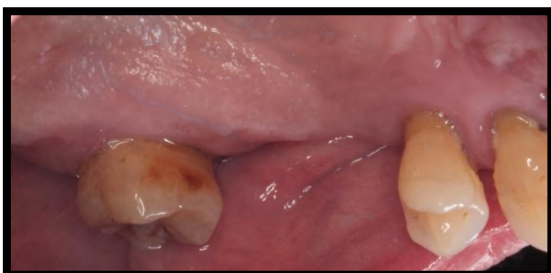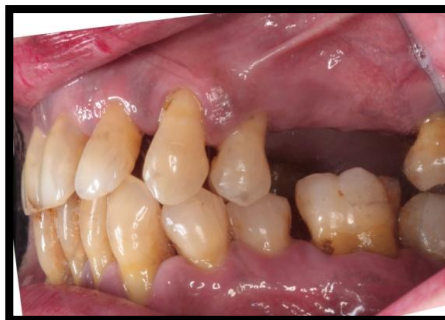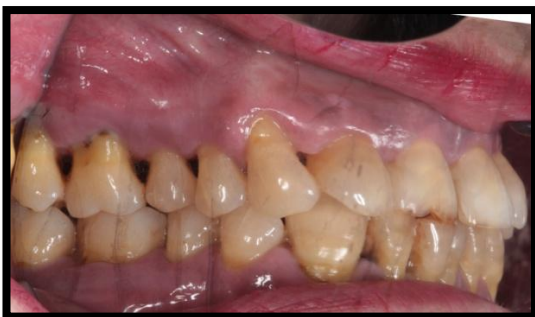**Figura 20: periapicales superiores**



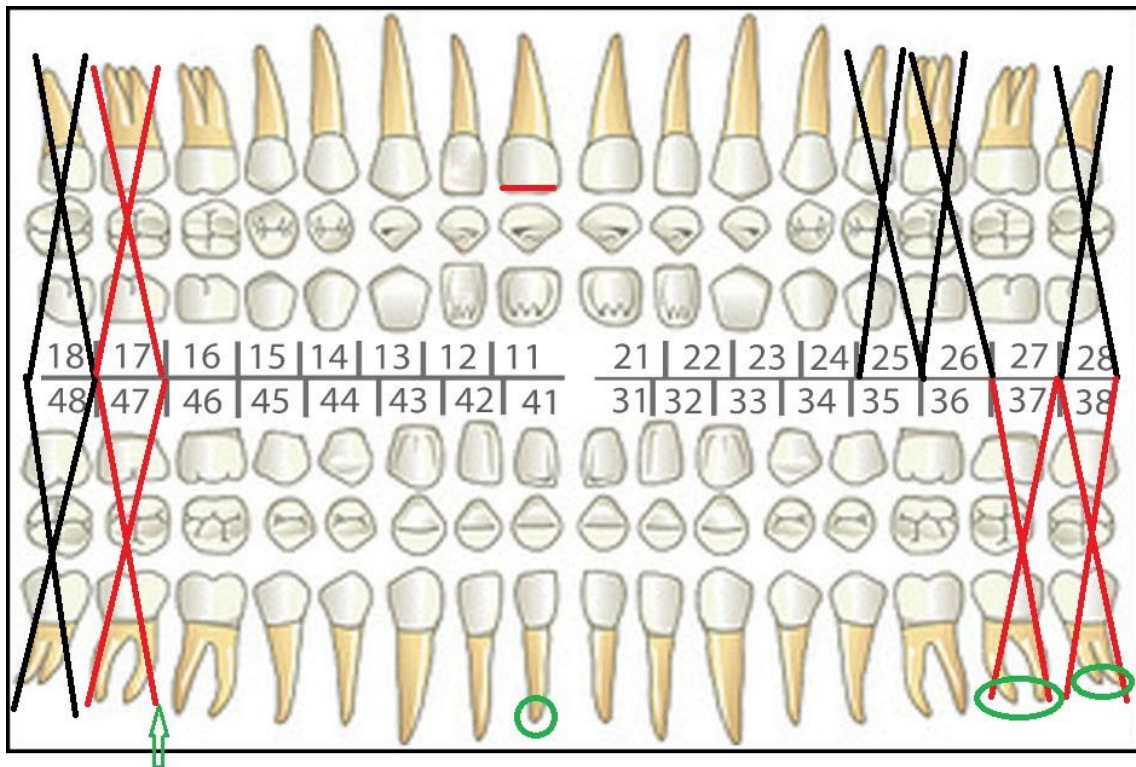
**Figura 21: periapicales inferiores**



**Figura 22: fotografías periodontales**



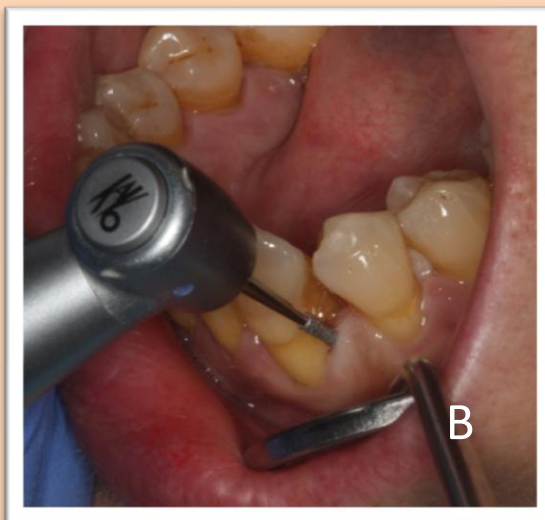
**Figura 23: odontograma**



**Figura 24: profilaxis**

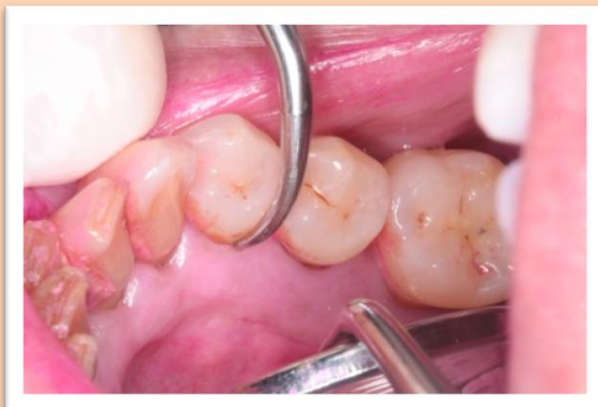

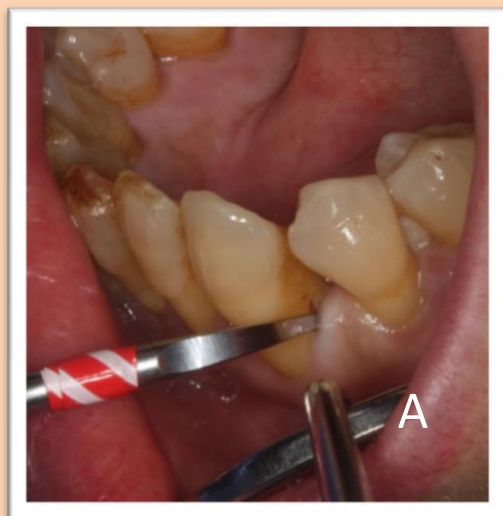Figura 25: RAR





**Figura 26: periodontograma de reevaluación**

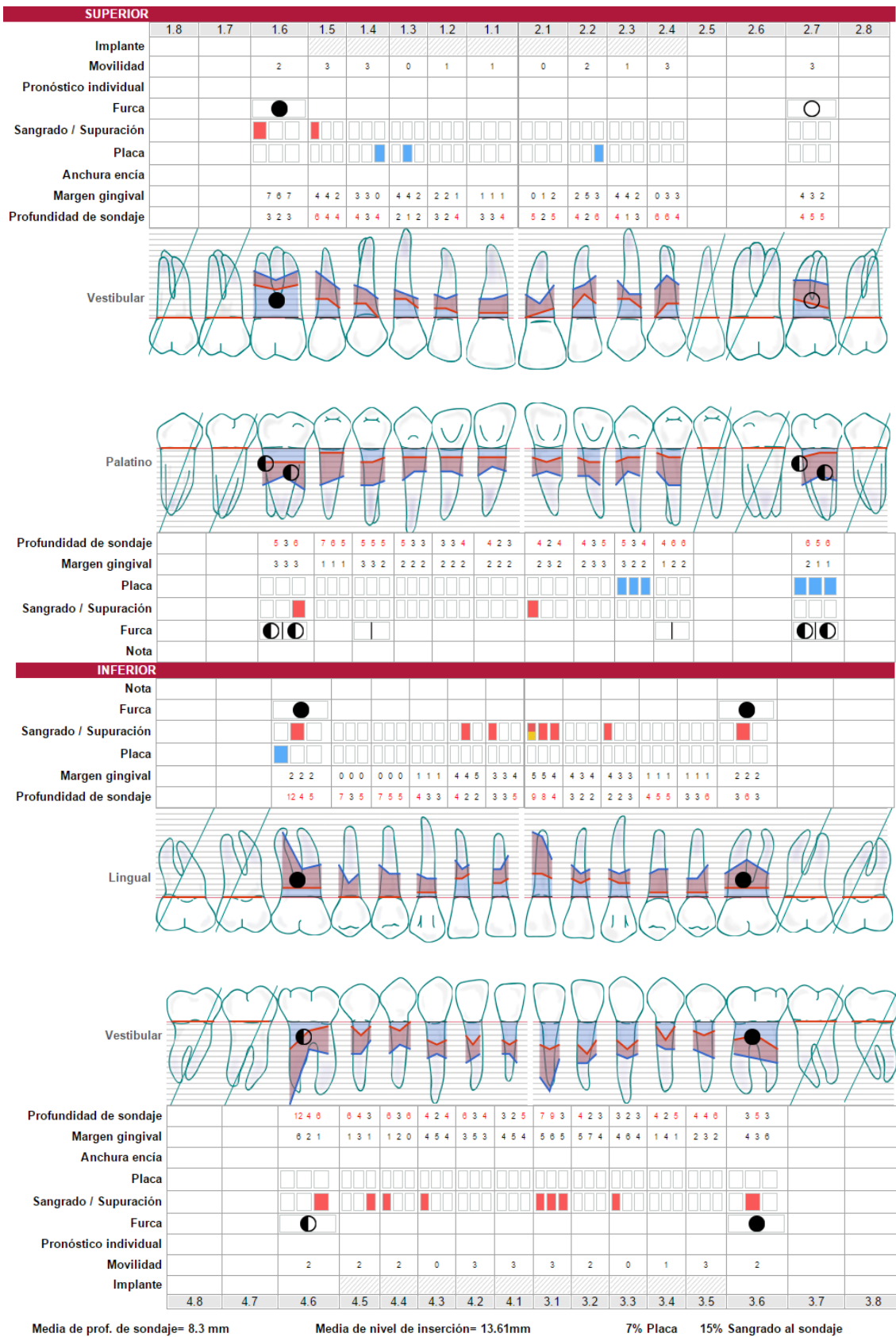


Figura 27: CRA

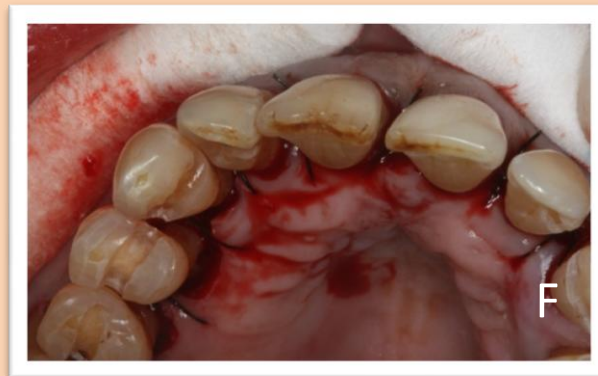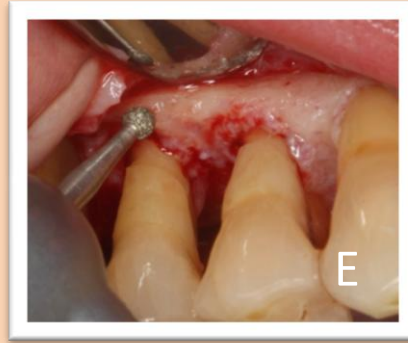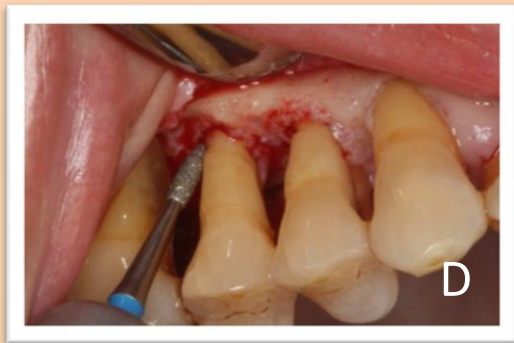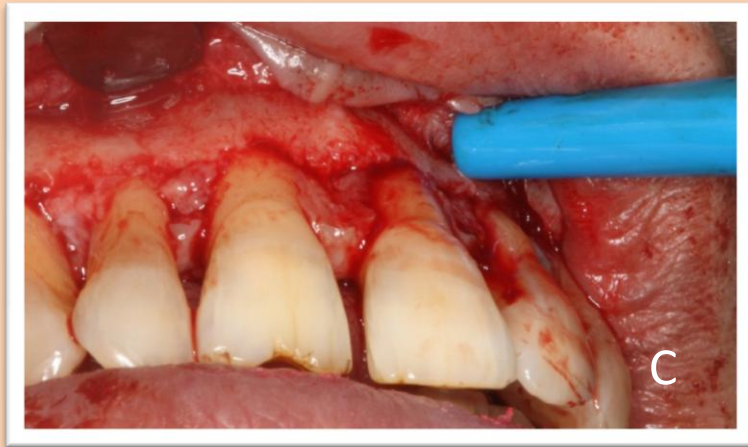
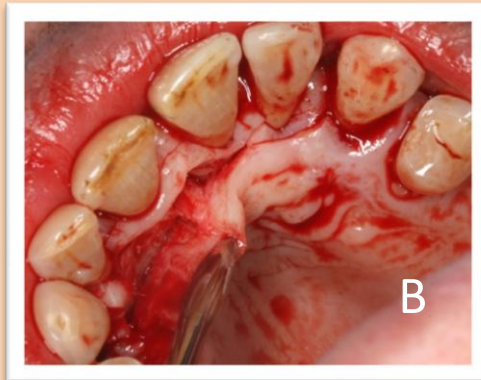


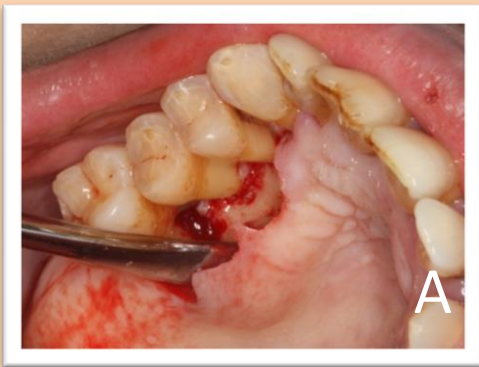Figura 27a: CRA cicatrización



