

# Is there consensus in defining childhood cerebral visual impairment? A systematic review of terminology and definitions

Hanna E A Sakki,<sup>1</sup> Naomi J Dale,<sup>1,2</sup> Jenefer Sargent,<sup>2</sup> Teresa Perez-Roche,<sup>3</sup> Richard Bowman<sup>1,4</sup>

► Additional material is published online only. To view please visit the journal online (<http://dx.doi.org/10.1136/bjophthalmol-2017-310694>).

<sup>1</sup>Developmental Neurosciences Programme, UCL GOS Institute of Child Health University College London, London, UK  
<sup>2</sup>Wolfson Neurodisability Service, Department of Neurosciences, Great Ormond Street Hospital For Children NHS Trust, London, UK  
<sup>3</sup>Department of Ophthalmology, Hospital Universitario Miguel Servet, Zaragoza, Spain  
<sup>4</sup>Department of Ophthalmology, Great Ormond Street Hospital For Children NHS Trust, London, UK

## Correspondence to

Dr Naomi J Dale, Wolfson Neurodisability Service, Department of Neurosciences, Great Ormond Street Hospital NHS Foundation Trust, London WC1N 3JH, UK; [naomi.dale@gosh.nhs.uk](mailto:naomi.dale@gosh.nhs.uk)

Received 3 May 2017  
 Revised 28 September 2017  
 Accepted 6 October 2017  
 Published Online First  
 16 November 2017

## ABSTRACT

The childhood condition of visual difficulties caused by brain damage, commonly termed cortical or cerebral visual impairment (CVI), is well established but has no internationally accepted definition. Clarification of its core features is required to advance research and clinical practice. This systematic review aimed to identify the definitions of childhood CVI in the original scientific literature to describe and critically appraise a consensual definition of the condition. MEDLINE, EMBASE, PsychINFO, CINAHL and AMED databases were searched in January 2017. Studies were included if they (1) were published original research, (2) contained a childhood CVI sample, (3) contained a definition of CVI and (4) described their CVI identification/diagnostic method. Thematic analysis identified concepts within definitions and narrative synthesis was conducted. Of 1150 articles, 51 met inclusion criteria. Definitions were subdivided according to detail (descriptive definition, description not reaching definition status and diagnostic/operationalising criteria). Three themes concerning visual deficits, eye health and brain integrity were identified (each containing subthemes) and analysed individually across definitions. The most common themes were 'visual impairment' (n=20), 'retrochiasmatic pathway damage' (n=13) and 'normal/near normal eye health' (n=15). The most consensual definition identified here may not be the best quality for advancing our understanding of CVI. We argue for the alternative definition: *CVI is a verifiable visual dysfunction which cannot be attributed to disorders of the anterior visual pathways or any potentially co-occurring ocular impairment. We propose reporting guidelines to permit comparison across studies and increase the evidence base for more reliable clinical assessment and diagnosis.*

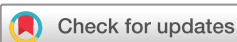## INTRODUCTION

Brain injury is the most common cause of severe visual impairment in the UK,<sup>1</sup> yet 'cerebral visual impairment' as an entity remains vague. Affected children often have other impairments such as intellectual disability, movement disorders and epilepsy and are likely to be assessed and managed by a wide range of professionals (including ophthalmologists, paediatricians, neurologists, psychologists and other allied healthcare professionals).<sup>2–10</sup> Therefore, clarity and agreement over what cerebral visual impairment means will improve communication and management.

The term cerebral or cortical visual impairment (CVI) refers to visual impairment or dysfunction

originating in neural insult.<sup>11 12</sup> The pathology of childhood CVI is established; however, subtly different terminologies and definitions are applied to this disorder, which influence the selection of clinical assessment methodologies.<sup>13 14</sup> In children with the classic presentation of visual acuity reduction in the absence of anterior pathway damage and a clinical history or direct indication of neural damage, clinical diagnosis may be relatively straightforward. However, in addition to visual impairment (significantly reduced visual acuity and/or visual fields<sup>15</sup>), the inclusion of a broad range of other indicators such as wider visual and ocular dysfunctions in CVI is commonly debated.<sup>2 3 13 14 16–21</sup> For example, a child with severe intellectual and mobility impairments may show poor visual responses, but it can be difficult to ascertain whether this is due to global impairment or a specific visual deficit. This may be further complicated by co-occurring ocular pathology such as optic atrophy. Alternatively, a child with known brain injury confirmed by MRI may show relatively good visual acuity but severe difficulties in functional use of vision in everyday life (such as interpreting crowded visual scenes, visuomotor control or route-finding), with visual perceptual impairment confirmed by neuropsychological assessment. Equally, a child with the above symptoms may not have a medical history or MRI evidence of brain injury. Cases such as the examples above may warrant and benefit from a diagnosis of CVI and implementation of management strategies. In children with more complex presentations, it is difficult to know where to set the boundaries of the condition and whether to ascribe difficulties to CVI or other developmental conditions.<sup>16</sup> This has led to the debated proposal that there must be sufficient discrepancy between cognitive and visual perceptual quotients to establish a visual processing deficit.<sup>22–26</sup> The suspicion of neural damage is also often difficult to confirm clinically,<sup>13 27</sup> leading a recent systematic review exploring the visual perceptual dysfunctions of childhood CVI to conclude that the definition should be based on functional vision rather than neuroanatomical landmarks.<sup>13</sup>

To advance the understanding of childhood CVI for diagnostic and nosological purposes, clarification of its core features is recommended.<sup>14 28</sup> This is important for guiding clinicians in selecting age-appropriate and developmentally appropriate assessments for more accurate diagnosis.<sup>13 28 29</sup> However, as there is currently no international consensus on



**To cite:** Sakki HEA, Dale NJ, Sargent J, et al. *Br J Ophthalmol* 2018;**102**:424–432.

the definition of childhood CVI which covers the range of childhood developmental abilities and age, there is consequently no universally accepted diagnostic assessment framework.<sup>30</sup> The diagnostic process may be based on ophthalmological examination, basic vision examination, standardised neuropsychological assessment, neuroimaging or any combination of these. No guidelines exist on which professionals can or should be qualified to make a clinical diagnosis of the condition. Moreover, there are only a few evidence-based interventions, of limited scope, for childhood CVI, as it is difficult to evaluate potential treatments in the absence of a stable reference standard.<sup>31</sup>

Previous efforts to reach an international consensus on the definition of childhood CVI have been undertaken by round table discussion by expert clinicians and researchers.<sup>12 32 33</sup> An alternative approach is to systematically scrutinise those definitions used in empirical studies of CVI. This will permit a critical examination of definitions already in use. To the authors' knowledge, such a systematic investigation has not yet been conducted. There are known to be multiple assessment approaches for testing CVI,<sup>3 34 35</sup> but consideration of their usefulness and how they correspond with the definitions identified is beyond the scope of this review.

The aim of this systematic review is to identify and critically evaluate the terminologies and definitions of childhood CVI in the published peer-reviewed scientific and medical literature, thereby identifying if there is a consensual definition of childhood CVI in current practical use and the nature of such a definition.

## METHOD

### Search strategy

The literature search was run in the Ovid MEDLINE, Embase Classic+Embase, PsycINFO, CINAHL and AMED databases in January 2017 by one author (HEAS) after development of the search strategy by three authors (HEAS, NJD and TP-R). All free-text terms and subject headings relating to CVI and childhood were used. Searches were restricted to original peer-reviewed research articles and the grey literature was excluded. No publication time limits were applied as this is a relatively new field of research with no previous consensus or systematic evaluation, and any possible effects of time on definitions and terminologies used were not known. A manual search was performed on four textbooks of childhood CVI.<sup>32 36-38</sup> The results were stored in EndNote X7, and duplicates were removed. The reference lists of included articles were inspected manually for previously unidentified references. Only English language articles were included as there was no capacity for translation. See supplementary materials for full search details (online supplementary table 1).

### Inclusion/exclusion criteria and process

Titles and abstracts were independently reviewed by two researchers (HEAS and TP-R). When there was insufficient detail to determine eligibility, the full text was obtained. Full texts were reviewed independently by the researchers. Articles were included if they (1) were original research papers published in peer-reviewed scientific journals, (2) contained a childhood CVI sample (aged 0–19 years), (3) contained a definition of CVI and (4) contained descriptions of the methods used to identify children with CVI/allocate children into the CVI group. Disagreements at both stages were resolved by discussion between reviewers.

### Data extraction

A data extraction tool was designed for this review concerning (1) demographics and identification of the articles, (2) terminology and definitions of CVI and (3) methodological information and sample characteristics (see supplementary materials: online supplementary table 2 for full definitions, online supplementary tables 3 and 4 for methodological details).

### Data analysis

Qualitative analysis was conducted to identify the characteristics that were included in the descriptive definitions and diagnostic/operationalising criteria of CVI. Quantitative analysis of these characteristics was run to find the prevalence of components and summarise findings in a narrative synthesis.

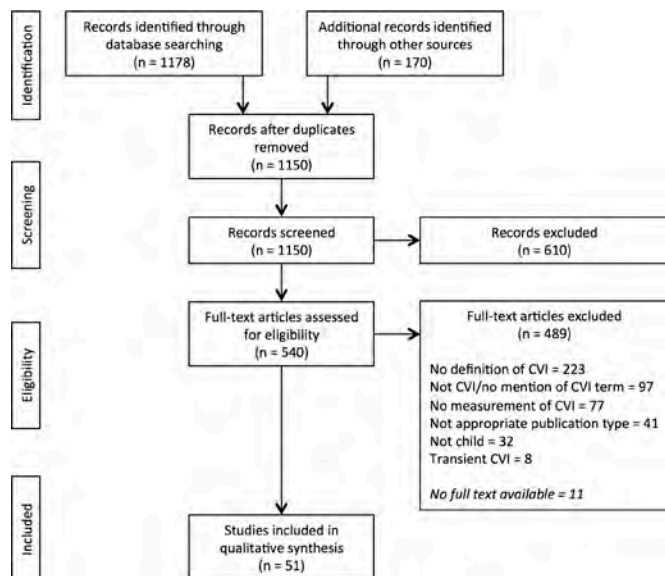
### Thematic analysis

Thematic analysis was conducted to analyse the content of definitions. This is a six-step qualitative method used to identify, analyse and report patterns within data.<sup>39</sup> Similar approaches have previously been used to analyse definitions in healthcare research.<sup>40 41</sup> Definitions and diagnostic/operationalising criteria were analysed separately. All definitions and diagnostic/operationalising criteria were extracted as data codes for inductive identification of themes. Data codes were split and organised according to themes within definitions and diagnostic/operationalising criteria. They were reviewed to identify possible subthemes and then rereviewed. Themes and subthemes were named and described. Themes and subthemes were rereviewed at the final stage to check that codes were correctly categorised. A second researcher independently coded 20% of data for inter-rater reliability. Cohen's Kappa was 0.85, indicating an excellent level of agreement.<sup>42</sup>

### Quality assessment

Quality of the included studies was assessed by the level of detail in each definition. Definitions of CVI were subdivided into three groups on the basis of detail provided. The 'descriptive definition' was classified as a statement which explicitly or implicitly described the core characteristics of CVI. In most papers, the definition of CVI was clearly identified with phrases such as '(CVI) is defined as...'<sup>17 20 43-46</sup> or '(CVI) is a clinical syndrome manifested by...'.<sup>47</sup> These were taken to be explicit definitions. However, in some cases, there was no explicit definition of CVI in a single phrase.<sup>30 48</sup> These were considered 'descriptions not reaching definition status' as it was unclear whether they were a more general description or a narrower definition of CVI to suit a specific study or sample. 'Diagnostic/operationalising criteria' were often similar to the descriptive definition but were classified as explicit statements of how the participants were diagnosed or allocated into the CVI group. Examples of how such criteria were identified are 'CVI was diagnosed clinically...'<sup>49-53</sup> '...clinical characteristics consistent with CVI...'<sup>30</sup> and '...diagnosis of CVI was based on...'.<sup>43</sup> Most articles contained both a descriptive definition of CVI (either explicit definition or implicit description not reaching definition status) and diagnostic/operationalising criteria for CVI. Both data sets were extracted in these cases, as these often differed.

A quality assessment tool was designed for this review. Studies were assessed for whether the definition of CVI provided was explicit and whether the definition and diagnostic or operationalising criteria matched if both were reported. Studies which had an explicit descriptive definition, diagnostic/operationalising criteria and where the elements of the definition and diagnostic/



**Figure 1** PRISMA diagram of literature review process. CVI, cortical or cerebral visual impairment.

operationalising criteria matched were rated as good quality. Studies which only had an explicit descriptive definition but no diagnostic criteria were rated as medium quality. Studies in which the elements of the definition and diagnostic criteria did not match or which only had operationalising/diagnostic criteria or a description not reaching definition status were rated as poor quality.

## RESULTS

### Article characteristics

Figure 1 shows the PRISMA diagram of the review process. Fifty-one articles included a descriptive definition or diagnostic/operationalising criteria of CVI and were included (table 1). Although several papers were published by the same research groups, definitions of CVI varied between the papers. Seven papers published data from children at the VI programme at the Children's Hospital Vancouver, Canada,<sup>4 30 45 54-57</sup> six from the Wilhelmina Children's Hospital Utrecht, the Netherlands,<sup>58-60</sup> three from the University of Pisa, Italy,<sup>18 61 62</sup> two from a Paediatric Ophthalmology Unit in San Francisco, USA<sup>5 9</sup> and two from the Bartimeus Institute, the Netherlands.<sup>49 53</sup> Other articles may have also published on overlapping samples but all studies did not report their recruitment sources in enough detail to recognise this. It was not possible to identify exactly articles that reported data on the same or overlapping samples where several publications by single research groups fulfilled the inclusion criteria. Thus, all eligible articles were included in the analysis.

Thirty-three articles (65%) included both a descriptive definition and diagnostic/operationalising criteria, eight (16%) included only a descriptive definition and ten (20%) included only diagnostic/operationalising criteria. Of the 41 papers containing descriptive definitions, 35 (85%) had explicit definitions and 6 (15%) had 'descriptions not reaching definition status'. According to quality assessment, 4 papers had good quality, 8 had medium quality and 39 had poor quality definitions (table 1).

The studies covered a range of populations, including children at risk of CVI, specific subgroups with diagnosed CVI and general CVI samples (see supplementary materials, online supplementary table 3). In 34 articles, CVI had been diagnosed before the

study and in 17 there was an explicit diagnosis or allocation of children to the CVI group. In 47 articles, CVI was diagnosed on the basis of reduced visual acuity and in 4 articles on the basis of wider visual dysfunction (online supplementary table 3). Forty-seven articles (92%) reported sample size, with CVI-only samples ranging between 2 and 423 participants (*mdn*=34). Median gender distribution, reported in 23 studies (45%), was 55% boys (range 38-78% boys). Twenty-nine studies (60%) reported participant age, ranging between 0 and 45 years. Four studies (9%) that included single participants over 19 years (aged 45, 35, 25 and 20 years) were included as they were part of large childhood samples. Participants in the included studies were reported to have a number of comorbidities, including intellectual disability, movement disorder, seizure disorder, hydrocephalus, hearing impairment and other conditions (supplementary materials, online supplementary table 4). However, no articles explicitly considered how to diagnose CVI in the context of other conditions.

Studies used a variety of methods to assess for and diagnose CVI (supplementary materials, online supplementary table 4). In 25 studies, the assessor was not reported. Sixteen studies partially reported the assessors or had only one professional assessing the participants. Ten studies reported assessment by a multidisciplinary team, three of which did not detail the team members. There were different professionals involved in the assessments of different studies, including ophthalmologists, paediatricians, neurologists, psychologists and other allied health professionals (online supplementary table 4). In their methods, 19 studies explicitly reported fundus examination, 19 explicitly reported refraction and 20 explicitly reported an ocular motility assessment. A variety of vision assessments were reported, including visual acuity (n=34), very low vision (n=16), visual fields (n=15), neuropsychological (n=4 assessed, n=7 attempted), contrast sensitivity (n=3) and stereopsis (n=2). Twenty-eight studies conducted visual electrophysiology assessment. Thirty-one studies reported conducting a neuroimaging assessment, including MRI, CT, cranial ultrasound and PET. Due to incomplete reporting of exact tests used, it was not possible to identify specific clinical assessments that may be used more widely in the identification of childhood CVI and systematic evaluation of assessments is beyond the scope of this review. In 25 articles, the assessor conducting the examination was not reported.

### Terminology

Table 2 describes the geographical distribution of research groups and CVI terminologies used. Articles were published between 1979 and 2016 (table 1). The most prevalent terminology was *cortical visual impairment* (43% of all papers), used most commonly in North America (67% of North American papers). The terminology most used by European research groups was *cerebral visual impairment* (41% total, 83% of European papers). Other terminologies identified were *cortical blindness*, *cerebral blindness*, *central visual impairment*, *cerebral visual disturbance* and *retrogeniculate visual loss*. These were used by eight papers (16%), the majority published before 2000.

### Definitions of CVI

Thematic analysis revealed three consistently occurring themes within the definitions of CVI (table 3). Eleven papers (27% of all definitions) had definitions containing all three themes and were all rated as having explicit definitions. Theme combinations within definitions were very heterogeneous, thus themes

**Table 1** Definitions, diagnostic criteria and sample characteristics of included studies

Article ID	Terminology	Diagnostic criteria				Quality assessment				Quality grading
		Vision*	Braint	Eye†	Vision*	Braint	Eye†	Explicit definitions‡	Did the elements of the definition and diagnostic criteria match?	
Frank & Torres (1979) <sup>44</sup>	Cortical and cerebral blindness	1	1	0	1	0	1	Yes	No	Poor
Mohn <i>et al</i> (1983) <sup>83</sup>	Cortical blindness	1	0	1	1	0	1	Yes	Yes	Good
Robertson <i>et al</i> (1986) <sup>57</sup>	Cortical visual impairment	2	0	2	2	5	2	Yes	No	Poor
Roland <i>et al</i> (1986) <sup>54</sup>	Cortical visual impairment	2	0	1	2	0	2	Yes	No	Poor
Jan <i>et al</i> (1987) <sup>62</sup>	Cortical visual impairment	NR	NR	NR	2	6	2	NR	NA	Poor
Bencivenga <i>et al</i> (1989) <sup>56</sup>	Cortical visual impairment	0	6	0	2	5	1	DNRDS	No	Poor
Flodmark <i>et al</i> (1990) <sup>4</sup>	Cortical visual impairment	2	2	0	NR	NR	NR	Yes	NA	Medium
Taylor & McCulloch (1991) <sup>84</sup>	Cortical blindness	1	0	1	NR	NR	NR	Yes	NA	Medium
Wong (1991) <sup>63</sup>	Cortical visual impairment	2	0	1	2	0	1	Yes	Yes	Good
Chen <i>et al</i> (1992) <sup>85</sup>	Cortical visual impairment	2	4	1	2	0	1	Yes	No	Poor
Frank <i>et al</i> (1992) <sup>47</sup>	Cerebral blindness	1	5	1	1	0	1	Yes	No	Poor
Schenk-Rootlieb <i>et al</i> (1992) <sup>86</sup>	Cerebral visual disturbance	3w	4	0	2	0	2	Yes	No	Poor
Granet <i>et al</i> (1993) <sup>87</sup>	Central visual impairment	3	0	1	2	2	1	DNRDS	No	Poor
Jan <i>et al</i> (1993) <sup>45</sup>	Cortical visual impairment	2	2	0	NR	NR	NR	Yes	NA	Medium
Schenk-Rootlieb <i>et al</i> (1993) <sup>88</sup>	Cerebral visual impairment	3	4	0	2	0	2	Yes	No	Poor
Schenk-Rootlieb <i>et al</i> (1994) <sup>89</sup>	Cerebral visual impairment	3	4	0	2	0	2	Yes	No	Poor
Eken <i>et al</i> (1995) <sup>59</sup>	Cerebral visual impairment	NR	NR	NR	2	0	2	NR	NA	Poor
Cioni <i>et al</i> (1996) <sup>62</sup>	Cerebral visual impairment	3	2	0	2	0	0	Yes	No	Poor
Eken <i>et al</i> (1996) <sup>60</sup>	Cerebral visual impairment	NR	NR	NR	2	0	2	NR	NA	Poor
Kwok <i>et al</i> (1996) <sup>90</sup>	Cortical visual impairment	NR	NR	NR	2	0	1	NR	NA	Poor
Uggetti <i>et al</i> (1996) <sup>91</sup>	Cerebral visual impairment	2	0	2	NR	NR	NR	Yes	NA	Medium
Cioni <i>et al</i> (1997) <sup>61</sup>	Cerebral visual impairment	2	2	0	NR	NR	NR	Yes	NA	Medium
Lanzi <i>et al</i> (1998) <sup>65</sup>	Cerebral visual impairment	2	0	2	NR	NR	NR	Yes	NA	Medium
Stiers <i>et al</i> (1998) <sup>92</sup>	Cerebral visual impairment	3	4	0	3	0	2	Yes	No	Poor
Huo <i>et al</i> (1999) <sup>9</sup>	Cortical visual impairment	NR	NR	NR	2	0	2	NR	NA	Poor
Oud <i>et al</i> (1999) <sup>58</sup>	Cerebral visual impairment	3	4	0	0	4	1	Yes	No	Poor
Choi <i>et al</i> (2001) <sup>93</sup>	Cortical visual impairment	1	5	0	2	0	1	Yes	No	Poor
Good (2001) <sup>50</sup>	Cortical visual impairment	2	1	2	3	0	1	Yes	No	Poor
Weiss <i>et al</i> (2001) <sup>94</sup>	Cortical visual impairment	3	2	1	1	0	1	Yes	No	Poor
Brodsky <i>et al</i> (2002) <sup>91</sup>	Retrogeniculate visual loss	0	3	0	2	2	2	DNRDS	No	Poor
Sakai <i>et al</i> (2002) <sup>46</sup>	Cerebral visual impairment	3	4	0	2	2	1	Yes	No	Poor
Hoyt (2003) <sup>5</sup>	Cortical visual impairment	NR	NR	NR	2	0	2	NR	NA	Poor
Skozenski & Good (2004) <sup>82</sup>	Cortical visual impairment	2	2	0	2	0	1	Yes	No	Poor
Sie <i>et al</i> (2005) <sup>48</sup>	Cerebral visual impairment	0	4	0	2	0	1	DNRDS	No	Poor
Good & Hou (2006) <sup>51</sup>	Cortical and cerebral visual impairment	2	3	1	2	0	1	Yes	No	Poor
Matsuba & Jan (2006) <sup>30</sup>	Cortical visual impairment	0	2	0	3	0	0	DNRDS	No	Poor
Fazzi <i>et al</i> (2007) <sup>18</sup>	Cerebral visual impairment	3	5	1	NR	NR	NR	Yes	NA	Medium
Khethpal & Donahue (2007) <sup>43</sup>	Cortical visual impairment	2	0	1	3	0	2	Yes	No	Poor
Ghasia <i>et al</i> (2008) <sup>20</sup>	Cerebral visual impairment	2	0	2	NR	NR	NR	Yes	NA	Medium
Ferziger <i>et al</i> (2011) <sup>73</sup>	Cerebral visual impairment	2	2	0	3	0	2	Yes	No	Poor
Good <i>et al</i> (2012) <sup>52</sup>	Cortical visual impairment	NR	NR	NR	2	0	1	NR	NA	Poor

Continued

Table 1 Continued

Article ID	Terminology	Descriptive definition				Diagnostic criteria				Quality assessment	
		Vision*	Brain†	Eye‡	Eye‡	Vision*	Brain†	Eye‡	Eye‡	Did the elements of the definition and diagnostic criteria match?	Quality grading
Weinstein et al (2012) <sup>95</sup>	Cerebral visual impairment	2	6	0	2	2	6	2	DNRDS	No	Poor
Bosch et al (2014a) <sup>53</sup>	Cerebral visual impairment	2	5	1	3	0	0	2	Yes	No	Poor
Bosch et al (2014b) <sup>49</sup>	Cerebral visual impairment	3	4	1	3	0	0	2	Yes	No	Poor
Cavassan et al (2014) <sup>34</sup>	Cerebral visual impairment	2	4	1	2	4	4	1	Yes	Yes	Good
Chong & Dai (2014) <sup>96</sup>	Cerebral visual impairment	2	4	1	2	0	0	1	Yes	No	Poor
Geldof et al (2015) <sup>68</sup>	Cerebral visual impairment	3	2	0	3	2	2	1	Yes	No	Poor
Mezer et al (2015) <sup>97</sup>	Cortical visual impairment	NR	NR	NR	2	2	2	0	NR	NA	Poor
Binder et al (2016) <sup>67</sup>	Cortical visual impairment	2	0	2	2	2	0	2	Yes	Yes	Good
Kenmanu et al (2016) <sup>98</sup>	Cortical visual impairment	NR	NR	NR	2	0	0	1	NR	NA	Poor
Ozturk et al (2016) <sup>99</sup>	Cortical visual impairment	NR	NR	NR	2	2	5	1	NR	NA	Poor

\*Vision subthemes: 0, not present; 1, complete blindness; 2, visual impairment; 3, visual dysfunction

†Brain subthemes: 0, not present; 1, brain damage; 2, posterior visual pathway damage; 3, optic radiation damage; 4, retrochiasmatic pathway damage; 5, retrogeniculate pathway damage; 6, visual pathway damage, including higher visual association areas

‡Eye subthemes: 0, not present; 1, normal/near normal eye health; 2, extent of vision problems not explained by any eye problems; NR, not reported

\$Explicit definition: Yes, explicit definition; DNRDS, description not reaching definition status

were considered separately. The most common theme was *Vision Deficits* (in 90% of definitions) and contained three subthemes, of which *visual impairment* (according to WHO classification<sup>15</sup>) was the most prevalent (54% of subthemes). The theme of *Eye Health* (in 51% of definitions) contained three subthemes, of which *eye health normal/near normal* (eg, 'normal or minimal ocular findings'<sup>57</sup>) was the most prevalent (71% subthemes). The theme of *Brain Integrity* theme (present in 76% of definitions) contained six subthemes, of which *retrochiasmatic pathway damage* was the most prevalent (42% subthemes).

### Diagnostic criteria of CVI

In the 43 studies detailing diagnostic/operationalising criteria (84% of all papers), 10 (23% criteria) mentioned all three content themes of CVI in different combinations (table 3). The most commonly occurring theme was *Vision Deficits* (95% criteria), with its most common subtheme being *visual impairment* (70% subthemes). The most common subtheme of *Eye Health* (93% criteria) was *eye health normal/near normal* (51% subthemes). *Brain Integrity* was only present in 28% of diagnostic/operationalising criteria, with the most common subtheme being *posterior visual pathway damage* (42% criteria).

### DISCUSSION

This systematic review found commonality and diversity in the terminologies and definitions of childhood CVI, indicating some but not total consensus. Terminologies varied according to geographical location similarly to previous reports.<sup>11 12 20</sup> *Cerebral* and *cortical visual impairment* were most commonly used, the former in Europe and the latter in North America. Other terms showed no particular geographical patterns. Older terms such as *Cortical Blindness* are no longer used widely. They are not considered to represent CVI accurately as they imply total loss of vision, whereas most children with CVI show some preserved visual function.<sup>2 55 63</sup> The overall consensus points towards use of the term *Cerebral visual impairment* or *Cortical visual impairment*. We argue that the term *cerebral* is more suitable than *cortical* to describe CVI as subcortical damage to the posterior visual pathways is a common and accepted cause of the condition.<sup>27 64 65</sup> The older term *cortical* continues to be used in North America; however, researchers may be moving towards using *cerebral* for a more precise description.<sup>11 12 29 52 66 67</sup> Even researchers using the alternative term acknowledge that the term *cerebral* may most accurately describe the breadth of neural insults causing this condition.<sup>6 11</sup>

Diversity was found in the content of CVI descriptive definitions, in accordance with previous literature.<sup>13 66 68</sup> Although three core characteristics of CVI were identified, relating to visual deficits, eye health and brain integrity, the majority of definitions did not include all three characteristics. Based on this analysis, the most consensual definition of all three characteristics was a *visual impairment caused by damage to the retrochiasmatic pathways with normal/near normal eye health*. Diagnostic/operationalising criteria showed similar characteristics with one significant omission. The two most prevalent diagnostic/operationalising criteria were *visual impairment* in the *context of normal/near normal eye health*; few papers mentioned *Brain Integrity*.

This analysis has highlighted issues which may need to be addressed for a clinically useful definition of childhood CVI. First, although the term *visual impairment* is well accepted, there has been a question of whether it is sufficiently wide to describe the range of visual difficulties described in the population. Many

**Table 2** Geographical locations of research groups and cerebral or cortical visual impairment (CVI) terminologies used

Geographical location of research group			Terminology						
Continent (n)	Country (n)	City/state (n)	Cerebral visual impairment (n=21)	Cortical visual impairment (n=22)	Other (n=8)				
North America (24)	Canada (8)	Vancouver (7)	2	16	6				
		Toronto (1)							
	USA (16)	New York (2, 1*)							
		San Francisco (5, 1*)							
		Los Angeles (1)							
		Philadelphia (2)							
		Missouri (1)							
		Minnesota (1)							
		Arkansas (1)							
		Nashville (1)							
Europe (18)	Belgium (1)	Leuven (1)	15	1	2				
	Italy (5)	Pavia (3)							
		Pisa (2†)							
		The Netherlands (11)				Amsterdam (2)			
		Nijmegen (2)							
		Utrecht (5, 1*)							
		Rotterdam (1)							
	Turkey (1)	Izmir (1)							
	Asia (5)	Hong Kong (2)				Hong Kong (2)	1	4	-
		India (1)				Bangalore (1)			
Japan (1)		Sendai (1*)							
South Korea (1)		Seoul (1)							
Middle East (2)	Israel (2)	Ramat Gan (1‡)	1	1	-				
		Haifa (1‡)							
Oceania (1)	New Zealand (1)	Auckland (1)	1	-	-				
South America (1)	Brazil (1)	Sao Paulo (1)	1	-	-				

\*Children recruited from this area and corresponding author based in this area, collaborating authors based in other regions nationally.

†Children recruited from this area and corresponding author based in this area, collaborating authors based in other regions internationally.

‡Children recruited from other regions nationally and corresponding author based in this area, collaborating authors based in other regions nationally.

children with CVI appear to have greater difficulty in everyday visual behaviours than is explained by visual acuity.<sup>16 19 55 69</sup> Some have argued that the descriptor of a 'broad spectrum of visual dysfunctions' may better align with the recommendations of the WHO, the International Council of Ophthalmology and recent research suggesting that assessing vision difficulties should be based on wider visual function rather than visual acuity/field assessment alone and impairment alone.<sup>13 70 71</sup> A related debate is the issue of what is included in the term 'visual impairment'. The International Classification of Diseases-10<sup>15</sup> refers to significant visual acuity and/or visual field reduction but there have been calls to expand the term to include wider visual deficits.<sup>3 13 16 19</sup> Many children at risk of CVI with normal visual acuities show significant visual perceptual difficulties which affect daily living.<sup>17 19 69</sup> The question remains: should they be diagnosed with CVI? If childhood CVI does encompass wider visual dysfunctions, further subclassification of the condition may be very important to ensure a meaningful diagnosis and appropriate support for the individual child. Of relevance, ICD-11 beta versions (<http://apps.who.int/classifications/icd11/browse/f/en>) do now include more functional descriptors such as 'Visual spatial neglect', 'Prosopagnosia' and 'Dysfunction of reading ability' under the headings of 'Specific visual dysfunctions' and 'Complex vision-related dysfunctions'.

Second, the description of *no/minimal eye involvement* may not be accurate as some ocular pathology is commonly reported in CVI.<sup>18 64 67 72 73</sup> For example, an ophthalmologist (author

RB of this review) recently declined to operate on a child with dense cataracts because there was evidence of blindness from brain damage predating this, the cause of which was deemed CVI although eye health was not normal. A more appropriate description may be that 'any degree of ocular/anterior pathway damage present cannot explain the degree of visual dysfunction'. This ensures that CVI is not overlooked in children with ocular/anterior pathway damage and conversely that the ocular needs of children with CVI are not neglected.

Finally, this review showed that the descriptions of *Brain Integrity* were the most limited in definitions and diagnostic criteria. The more accepted description of *retrochiasmatic pathway damage* gives minimal detail of the possible areas of brain damage. Current clinical neuroimaging methods may or may not show abnormalities in the presence of definite behavioural symptoms and clinical information supporting diagnosis.<sup>13 27</sup> New experimental methods may reveal subtle morphological brain differences but these require powerful imaging and intensive data analysis, which are not feasible in current clinical practice.<sup>74-77</sup> This raises the question of how brain damage is clinically defined. For example, children born preterm may have elevated levels of visual perceptual difficulties even with MRI scans reported as normal<sup>27</sup>; is a known risk factor sufficient? Currently, the component of *Brain Integrity* is only inferential and assumes that clinical visual symptoms originate at brain level. The appropriate diagnosis of children with significant visual perceptual deficits but no apparent neurological insult remains a challenge.

**Table 3** Process and results of thematic analysis

Process of thematic analysis				Results of thematic analysis			
Initial identification of themes	Review of themes	Rereview and naming/ defining themes	Identification of subthemes	Descriptive definitions, n=41 Explicit definition, n=35 (DNRDS*, n=6)		Diagnostic/ operationalising criteria, n=43	
				Themes	Subthemes	Themes	Subthemes
1. Vision	1. Vision	1. Vision Deficits Any references to difficulties with the conscious perception of vision	1. Complete blindness 2. Visual acuity reduction/visual impairment 3. Visual dysfunction	35 (2*)	5 19 (1*) 11 (1*)	42	4 30 8
2. Eye health normal 3. Inconsistent vision eye health	2. Eye health (including inconsistent vision eye health)	2. Eye Health Any reference to the health of the ocular structures or the anterior visual pathways	1. Eye health normal/near normal 2. Eye problems do not account for the extent of vision problems	20 (1*)	14 (1*) 6	40	22 18
4. Brain	3. Brain	3. Brain Integrity Any mention of brain or neural involvement	1. Brain damage 2. Posterior visual pathway damage 3. Optic radiation damage 4. Retrochiasmatic pathway damage 5. Retrogeniculate pathway damage 6. Posterior pathway damage, including higher processing/ association areas	25 (5*)	2 8 (1*) 1 (1*) 11 (1*) 3 0 (2*)	12	0 5 0 2 4 1
5. Paediatric							
6. Miscellaneous (including aetiologies, assessment methods)							

\*DNRDS, description not reaching definition status.

In light of this review, we propose the following definition of childhood CVI, argued above: *childhood cerebral visual impairment is a verifiable visual dysfunction which cannot be attributed to disorders of the anterior visual pathways or any potentially co-occurring ocular impairment.* We suggest that the components of this definition are measurable and may be quantified using currently available clinical tools. A multidisciplinary approach to clinical assessment of childhood CVI may be valuable in cases where the ophthalmologist working on their own is unable to reach a diagnosis. Multidisciplinary input might involve full vision assessment, structured paediatric history, including vision and general development, full ophthalmological examination and clinical neuroimaging (although it might be appropriate to defer this for a baby who would require a general anaesthetic for MRI and for whom the MRI findings are unlikely to change medical management). Neuropsychological assessment of cognition and higher visual processes could also be informative if visual perceptual impairment is suspected. However, multidisciplinary assessment may not be feasible in all clinical services. Assessment should always be conducted with the principal aim of improving the understanding of the child's visual needs and limitations and helping to establish appropriate management strategies in a timely manner.

The limitations of this review must be considered when interpreting results. The inclusion of potentially overlapping samples across studies and several publications by the same research groups may have biased findings towards the views of more prolific researchers. However, definitions and diagnostic criteria of groups were not constant across studies, thus selection bias from these groups is unlikely. Although many articles were medical case note reviews, this analysis was based only on empirical research and may not reflect the full range of clinical practice or expert opinion. It will be important to ensure that a future consensual definition is clinically useful and applicable. Other developmental considerations of CVI not identified here

may be important to address, such as the impact of age of onset (childhood or adulthood), which may lead to differing symptom presentations and outcomes.<sup>2 5 54 78–80</sup> Another possibly relevant feature is aetiology, such as the difference between congenital and later acquired CVI from infection, trauma or brain tumour, which may affect the brain damage, visual difficulties and comorbidities seen.<sup>5 53 80 81</sup> A related consideration is how to best describe the heterogeneous symptomatology of CVI. In future, consensus may move towards a classification system with subgroups within the umbrella term of CVI,<sup>3</sup> depending on further empirical research. However, divisions into subgroupings may not yet be feasible due to our limited understanding of the condition.<sup>13</sup>

As our empirical understanding of childhood CVI increases, the content of the definition will be guided by new findings<sup>66</sup> which may lead to more reliable clinical assessment and diagnostic procedures. There is an emerging tendency towards multidisciplinary assessment, including clinical history-taking,<sup>3 69</sup> neuropsychology<sup>17 18 27</sup> and visual electrophysiology,<sup>34 51 82</sup> in the clinical identification of visual, neuropsychological and neurological symptoms which may be part of the CVI presentation. However, within the context of limited consensual definition and diagnostic procedures shown in this systematic review, clinicians and researchers will continue to draw on individual means of assessing and diagnosing the condition. As 77% of articles included in this analysis contained poor quality definitions, detailed reporting of methodologies is a necessity for future research. At minimum, research publications should always report the sample characteristics, descriptive definition and diagnostic or operationalising criteria of CVI as well as their exact assessment methods of CVI, to permit comparison across studies and increase the evidence base of the condition.

In summary, the consensual definition found in this review suggests that childhood CVI is *a visual impairment caused by damage to the retrochiasmatic pathways with normal/near*

normal eye health. However, we argue for an alternative definition based on research findings, expert opinion and clinical applicability that childhood CVI is a verifiable visual dysfunction which cannot be attributed to disorders of the anterior visual pathways or any potentially co-occurring ocular impairment. Diagnostic/operationalising criteria have been stronger in relation to characterising visual deficits and eye health than in relation to brain integrity. It has been argued that future definitions and diagnostic criteria may need to expand further to encompass the wide spectrum of children presenting in clinical ophthalmology services with suspected CVI, including those with higher visual processing dysfunctions but relatively intact visual acuity. Accurate identification of CVI in children with complex developmental presentations remains a major challenge for clinical diagnosis and treatment. Due to the lack of a unified definition and diagnostic process, children may receive very different clinical care and interventions depending on the clinical service they attend, both internationally and at a national level. This review proposes that further work is required for an internationally accepted consensus in definition for CVI to reflect advances in thinking about childhood CVI and to underpin future clinical and research developments. As previous expert round table discussion<sup>12 32 33</sup> and now systematic scrutinising of terminologies, definitions and diagnostic criteria have been completed, the next stage of furthering such a consensus requires advances in empirical investigations to consider whether a more refined definition and classification system of CVI is required.

**Contributors** HEAS, conception or design of the work, data collection, data analysis and interpretation, drafting the article and final approval of the version to be published. NJD, conception or design of the work, data analysis and interpretation, critical revision of the article and final approval of the version to be published. JS, conception or design of the work, critical revision of the article and final approval of the version to be published. TP-R, data analysis and interpretation and final approval of the version to be published. RB, conception or design of the work, critical revision of the article and final approval of the version to be published.

**Funding** This research was funded by the Ulverschroft Vision Research Society and the National Institute for Health Research Biomedical Research Centre at Great Ormond Street Hospital for Children NHS Foundation Trust and University College London.

**Competing interests** None declared.

**Provenance and peer review** Not commissioned; externally peer reviewed.

**Data sharing statement** The primary data of the research article will be available in Supplementary Data File 1. There is no additional unpublished data.

© Article author(s) (or their employer(s) unless otherwise stated in the text of the article) 2018. All rights reserved. No commercial use is permitted unless otherwise expressly granted.

## REFERENCES

- Rahi JS, Cable N. British Childhood Visual Impairment Study Group. Severe visual impairment and blindness in children in the UK. *Lancet* 2003;362:1359–65.
- Good WV, Jan JE, DeSa L, et al. Cortical visual impairment in children. *Surv Ophthalmol* 1994;38:351–64.
- Philip SS, Dutton GN. Identifying and characterising cerebral visual impairment in children: a review. *Clin Exp Optom* 2014;97:196–208.
- Flodmark O, Jan JE, Wong PK. Computed tomography of the brains of children with cortical visual impairment. *Dev Med Child Neurol* 1990;32:611–20.
- Hoyt CS. Visual function in the brain-damaged child. *Eye* 2003;17:369–84.
- Good WV. Cortical visual impairment: new directions. *Optom Vis Sci* 2009;86:663–5.
- Afshari MA, Afshari NA, Fulton AB. Cortical visual impairment in infants and children. *Int Ophthalmol Clin* 2001;41:159–69.
- Blohmé J, Tornqvist K. Visual impairment in Swedish children. III. Diagnoses. *Acta Ophthalmol Scand* 1997;75:681–7.
- Huo R, Burden SK, Hoyt CS, et al. Chronic cortical visual impairment in children: aetiology, prognosis, and associated neurological deficits. *Br J Ophthalmol* 1999;83:670–5.
- Chokron S, Dutton GN. Impact of cerebral visual impairments on motor skills: implications for developmental coordination disorders. *Front Psychol* 2016;7.
- Colenbrander A. What's in a name? Appropriate terminology for CVI. *J Vis Impair Blind* 2010;104:583.
- Frebel H. CVI?! How to define and what terminology to use: cerebral, cortical or cognitive visual impairment. *Br J Vis Impair* 2006;24:117–20.
- Boot FH, Pel JJ, van der Steen J, et al. Cerebral visual impairment: which perceptive visual dysfunctions can be expected in children with brain damage? A systematic review. *Res Dev Disabil* 2010;31:1149–59.
- Hoyt CS, Fredrick DR. Cortically visually impaired children: a need for more study. *Br J Ophthalmol* 1998;82:1225–7.
- World Health Organization. *International classification of diseases*. 10. Geneva: World Health Organization, 2010.
- Good WV. The spectrum of vision impairment caused by pediatric neurological injury. *J Aapos* 2007;11:424–5.
- Fazzi E, Bova S, Giovenzana A, et al. Cognitive visual dysfunctions in preterm children with periventricular leukomalacia. *Dev Med Child Neurol* 2009;51:974–81.
- Fazzi E, Signorini SG, Bova SM, et al. Spectrum of visual disorders in children with cerebral visual impairment. *J Child Neurol* 2007;22:294–301.
- van Genderen M, Dekker M, Pilon F, et al. Diagnosing cerebral visual impairment in children with good visual acuity. *Strabismus* 2012;20:78–83.
- Ghasia F, Brunstrom J, Gordon M, et al. Frequency and severity of visual sensory and motor deficits in children with cerebral palsy: gross motor function classification scale. *Invest Ophthalmol Vis Sci* 2008;49:572–80.
- Macintyre-Beon C, Young D, Calvert J, et al. Reliability of a question inventory for structured history taking in children with cerebral visual impairment. *Eye* 2012;26:1393.
- Fazzi E, Bova SM, Uggetti C, et al. Visual-perceptual impairment in children with periventricular leukomalacia. *Brain Dev* 2004;26:506–12.
- Ortibus E, Verhoeven J, Sunaert S, et al. Integrity of the inferior longitudinal fasciculus and impaired object recognition in children: a diffusion tensor imaging study. *Dev Med Child Neurol* 2012;54:38–43.
- Stiers P, De Cock P, Vandenbussche E. Separating visual perception and non-verbal intelligence in children with early brain injury. *Brain Dev* 1999;21:397–406.
- Stiers P, Vanderkelen R, Vanneste G, et al. Visual-perceptual impairment in a random sample of children with cerebral palsy. *Dev Med Child Neurol* 2002;44:370–82.
- Sargent J, Salt A, Dale N. Children with severe brain damage: functional assessment for diagnosis and intervention. In: DG N, Bax M, eds. *Visual impairment in children due to damage to the brain*. London: MacKeith Press, 2010:181–93.
- Ortibus E, Lagae L, Casteels I, et al. Assessment of cerebral visual impairment with the L94 visual perceptual battery: clinical value and correlation with MRI findings. *Dev Med Child Neurol* 2009;51:209–17.
- Marcum JA. *Humanizing modern medicine: an introductory philosophy of medicine*. Springer Netherlands: Dordrecht, 2008.
- Lueck AH. Cortical or cerebral visual impairment in children: A brief overview. *J Vis Impair Blind* 2010;104:585–92.
- Matsuba CA, Jan JE. Long-term outcome of children with cortical visual impairment. *Dev Med Child Neurol* 2006;48:508–12.
- Edwards AD, Brocklehurst P, Gunn AJ, et al. Neurological outcomes at 18 months of age after moderate hypothermia for perinatal hypoxic ischaemic encephalopathy: synthesis and meta-analysis of trial data. *BMJ* 2010;340:c363.
- Bax M, Dutton GN, eds. *Visual impairment in children due to damage to the brain*. London: MacKeith Press, 2010.
- Dennison E, Lueck AH. *Proceedings of the summit on cerebral/cortical visual impairment: educational, family, and medical perspectives: April 30, 2005*. America: American Foundation for the Blind, 2006.
- Cavascan NN, Salomão SR, Sacai PY, et al. Contributing factors to VEP grating acuity deficit and inter-ocular acuity difference in children with cerebral visual impairment. *Doc Ophthalmol* 2014;128:91–9.
- Ortibus EL, De Cock PP, Lagae LG. Visual perception in preterm children: what are we currently measuring? *Pediatr Neurol* 2011;45:1–10.
- Lueck AH, Dutton GN, eds. *Vision and the brain: understanding cerebral visual impairment in children*. New York: AFB Press, 2015.
- Zihl J, Dutton GN. *Cerebral visual impairment in children: visuoperceptive and visuocognitive disorders*. Springer, 2014.
- Roman Lantzy C. *Cortical visual impairment: an approach to assessment and intervention*. New York: AFB Press, 2007.
- Braun V, Clarke V. Using thematic analysis in psychology. *Qual Res Psychol* 2006;3:77–101.
- Lebeau JP, Cadwallader JS, Aubin-Auger I, et al. The concept and definition of therapeutic inertia in hypertension in primary care: a qualitative systematic review. *BMC Fam Pract* 2014;15:130.
- Frank JR, Mungroo R, Ahmad Y, et al. Toward a definition of competency-based education in medicine: a systematic review of published definitions. *Med Teach* 2010;32:631–7.
- Fleiss JL. *Statistical methods for rates and proportions*. 2nd ed. New York: John Wiley, 1981.
- Khetpal V, Donahue SP. Cortical visual impairment: etiology, associated findings, and prognosis in a tertiary care setting. *J Aapos* 2007;11:235–9.



- 44 Frank Y, Torres F. Visual evoked potentials in the evaluation of "cortical blindness" in children. *Ann Neurol* 1979;6:126–9.
- 45 Jan JE, Groenvelde M, Anderson DP. Photophobia and cortical visual impairment. *Dev Med Child Neurol* 1993;35:473–7.
- 46 Sakai S, Hirayama K, Iwasaki S, et al. Contrast sensitivity of patients with severe motor and intellectual disabilities and cerebral visual impairment. *J Child Neurol* 2002;17:731–7.
- 47 Frank Y, Kurtzberg D, Kreuzer JA, et al. Flash and pattern-reversal visual evoked potential abnormalities in infants and children with cerebral blindness. *Dev Med Child Neurol* 1992;34:305–15.
- 48 Sie LT, Hart AA, van Hof J, et al. Predictive value of neonatal MRI with respect to late MRI findings and clinical outcome. A study in infants with periventricular densities on neonatal ultrasound. *Neuropediatrics* 2005;36:78–89.
- 49 Bosch DG, Boonstra FN, Reijnders MR, et al. Chromosomal aberrations in cerebral visual impairment. *Eur J Paediatr Neurol* 2014;18:677–84.
- 50 Good WV. Development of a quantitative method to measure vision in children with chronic cortical visual impairment. *Trans Am Ophthalmol Soc* 2001;99:253–69.
- 51 Good WV, Hou C. Sweep visual evoked potential grating acuity thresholds paradoxically improve in low-luminance conditions in children with cortical visual impairment. *Invest Ophthalmol Vis Sci* 2006;47:3220–4.
- 52 Good WV, Hou C, Norcia AM. Spatial contrast sensitivity vision loss in children with cortical visual impairment. *Invest Ophthalmol Vis Sci* 2012;53:7730–4.
- 53 Bosch DG, Boonstra FN, Willemsen MA, et al. Low vision due to cerebral visual impairment: differentiating between acquired and genetic causes. *BMC Ophthalmol* 2014;14:59.
- 54 Roland EH, Jan JE, Hill A, et al. Cortical visual impairment following birth asphyxia. *Pediatr Neurol* 1986;2:133–7.
- 55 Jan JE, Groenvelde M, Sykanda AM, et al. Behavioural characteristics of children with permanent cortical visual impairment. *Dev Med Child Neurol* 1987;29:571–6.
- 56 Bencivenga R, Wong PK, Woo S, et al. Quantitative VEP analysis in children with cortical visual impairment. *Brain Topogr* 1989;1:193–8.
- 57 Robertson R, Jan JE, Wong PK. Electroencephalograms of children with permanent cortical visual impairment. *Can J Neurol Sci* 1986;13:256–61.
- 58 Oud KT, Steggerda SJ, Nanninga Van den Neste VM, et al. Visual acuity in children with hydrocephalus. *Neuroophthalmology* 1999;21:75–82.
- 59 Eken P, de Vries LS, van der Graaf Y, et al. Haemorrhagic-ischaemic lesions of the neonatal brain: correlation between cerebral visual impairment, neurodevelopmental outcome and MRI in infancy. *Dev Med Child Neurol* 1995;37:41–55.
- 60 Eken P, de Vries LS, van Nieuwenhuizen O, et al. Early predictors of cerebral visual impairment in infants with cystic leukomalacia. *Neuropediatrics* 1996;27:16–25.
- 61 Cioni G, Fazzi B, Coluccini M, et al. Cerebral visual impairment in preterm infants with periventricular leukomalacia. *Pediatr Neurol* 1997;17:331–8.
- 62 Cioni G, Fazzi B, Ippata AE, et al. Correlation between cerebral visual impairment and magnetic resonance imaging in children with neonatal encephalopathy. *Dev Med Child Neurol* 1996;38:120–32.
- 63 Wong VC. Cortical blindness in children: a study of etiology and prognosis. *Pediatr Neurol* 1991;7:178–85.
- 64 Jacobson LK, Dutton GN. Periventricular leukomalacia: an important cause of visual and ocular motility dysfunction in children. *Surv Ophthalmol* 2000;45:1–13.
- 65 Lanzi G, Fazzi E, Uggetti C, et al. Cerebral visual impairment in periventricular leukomalacia. *Neuropediatrics* 1998;29:145–50.
- 66 Lehman SS. Cortical visual impairment in children: identification, evaluation and diagnosis. *Curr Opin Ophthalmol* 2012;23:384–7.
- 67 Binder NR, Kruglyakova J, Borchert MS. Strabismus in patients with cortical visual impairment: outcomes of surgery and observations of spontaneous resolution. *J Aapos* 2016;20:121–5.
- 68 Geldof CJ, van Wassenaer-Leemhuis AG, Dik M, et al. A functional approach to cerebral visual impairments in very preterm/very-low-birth-weight children. *Pediatr Res* 2015;78:190–7.
- 69 Macintyre-Béon C, Young D, Dutton GN, et al. Cerebral visual dysfunction in prematurely born children attending mainstream school. *Doc Ophthalmol* 2013;127:89–102.
- 70 International Council of Ophthalmology. *Visual standards: aspects and ranges of vision loss with emphasis on population surveys. 29th international congress of ophthalmology*. Sydney, Australia: International Council of Ophthalmology, 2002.
- 71 World Health Organization. *The management of low vision in children: Report of the 1992 World Health Organization consultation*. Bangkok: JVI, 1993.
- 72 Good WV, Jan JE, Burden SK, et al. Recent advances in cortical visual impairment. *Dev Med Child Neurol* 2001;43:56–60.
- 73 Ferziger NB, Nemet P, Brezner A, et al. Visual assessment in children with cerebral palsy: implementation of a functional questionnaire. *Dev Med Child Neurol* 2011;53:422–8.
- 74 Seghier ML, Lazeyras F, Zimine S, et al. Combination of event-related fMRI and diffusion tensor imaging in an infant with perinatal stroke. *Neuroimage* 2004;21:463–72.
- 75 Martín MB, Santos-Lozano A, Martín-Hernández J, et al. Cerebral versus ocular visual impairment: the impact on developmental neuroplasticity. *Front Psychol* 2016;7:7.
- 76 Merabet LB, Devaney KJ, Bauer CM, et al. Characterizing visual field deficits in cerebral/cortical visual impairment (CVI) using combined diffusion based imaging and functional retinotopic mapping: a case study. *Front Syst Neurosci* 2016;10.
- 77 Bauer CM, Heidary G, Koo BB, et al. Abnormal white matter tractography of visual pathways detected by high-angular-resolution diffusion imaging (HARDI) corresponds to visual dysfunction in cortical/cerebral visual impairment. *J Aapos* 2014;18:398–401.
- 78 Thun-Hohenstein L, Schmitt B, Steinlin H, et al. Cortical visual impairment following bacterial meningitis: magnetic resonance imaging and visual evoked potentials findings in two cases. *Eur J Pediatr* 1992;151:779–82.
- 79 Whiting S, Jan JE, Wong PK, et al. Permanent cortical visual impairment in children. *Dev Med Child Neurol* 1985;27:730–9.
- 80 Aghaji A, Okoye O, Bowman R. Causes and emerging trends of childhood blindness: findings from schools for the blind in Southeast Nigeria. *Br J Ophthalmol* 2015;99:727–31.
- 81 Brodsky MC, Fray KJ, Glasier CM. Perinatal cortical and subcortical visual loss: mechanisms of injury and associated ophthalmologic signs. *Ophthalmology* 2002;109:85–94.
- 82 Skoczinski AM, Good WV. Vernier acuity is selectively affected in infants and children with cortical visual impairment. *Dev Med Child Neurol* 2004;46:526–32.
- 83 Mohn G, Van Hof-van Duin J. Behavioural and electrophysiological measures of visual functions in children with neurological disorders. *Behav Brain Res* 1983;10:177–87.
- 84 Taylor MJ, McCulloch DL. Prognostic value of VEPs in young children with acute onset of cortical blindness. *Pediatr Neurol* 1991;7:111–5.
- 85 Chen TC, Weinberg MH, Catalano RA, et al. Development of object vision in infants with permanent cortical visual impairment. *Am J Ophthalmol* 1992;114:575–8.
- 86 Schenk-Rootlieb AJ, van Nieuwenhuizen O, van der Graaf Y, et al. The prevalence of cerebral visual disturbance in children with cerebral palsy. *Dev Med Child Neurol* 1992;34:473–80.
- 87 Granet DB, Hertle RW, Quinn GE, et al. The visual-evoked response in infants with central visual impairment. *Am J Ophthalmol* 1993;116:437–43.
- 88 Schenk-Rootlieb AJ, van Nieuwenhuizen O, Schiemanck N, et al. Impact of cerebral visual impairment on the everyday life of cerebral palsied children. *Child Care Health Dev* 1993;19:411–23.
- 89 Schenk-Rootlieb AJ, van Nieuwenhuizen O, van Waes PF, et al. Cerebral visual impairment in cerebral palsy: relation to structural abnormalities of the cerebrum. *Neuropediatrics* 1994;25:68–72.
- 90 Kwok SK, Ho PC, Chan AK, et al. Ocular defects in children and adolescents with severe mental deficiency. *J Intellect Disabil Res* 1996;40:330–5.
- 91 Uggetti C, Egitto MG, Fazzi E, et al. Cerebral visual impairment in periventricular leukomalacia: MR correlation. *AJNR Am J Neuroradiol* 1996;17:979–85.
- 92 Stiers P, De Cock P, Vandenbussche E. Impaired visual perceptual performance on an object recognition task in children with cerebral visual impairment. *Neuropediatrics* 1998;29:80–8.
- 93 Young Choi M, Soo Lee D, Hwang J-M, et al. Investigation of visual cortex in children with cortical visual impairment: positron emission tomography. *Neuroophthalmology* 2001;25:103–8.
- 94 Weiss AH, Kelly JP, Phillips JO. The infant who is visually unresponsive on a cortical basis. *Ophthalmology* 2001;108:2076–87.
- 95 Weinstein JM, Gilmore RO, Shaikh SM, et al. Defective motion processing in children with cerebral visual impairment due to periventricular white matter damage. *Dev Med Child Neurol* 2012;54:e1–e8.
- 96 Chong C, Dai S. Cross-sectional study on childhood cerebral visual impairment in New Zealand. *J Aapos* 2014;18:71–4.
- 97 Mezer E, Chetrit A, Kalter-Leibovici O, et al. Trends in the incidence and causes of severe visual impairment and blindness in children from Israel. *J Aapos* 2015;19:260–5.
- 98 Kemmanu V, Hegde K, Giliyar SK, et al. Prevalence of childhood blindness and ocular morbidity in a rural pediatric population in southern India: the pavagada pediatric eye disease study-1. *Ophthalmic Epidemiol* 2016;23:185–92.
- 99 Ozturk T, Er D, Yaman A, et al. Changing trends over the last decade in the aetiology of childhood blindness: a study from a tertiary referral centre. *Br J Ophthalmol* 2016;100:166–71.