

Percutaneous Intravascular Biopsy Using a Bronchoscopy Forceps Diagnosis of a Pulmonary Artery Intimal Sarcoma

J. A. Guirola¹ · A. Laborda¹ · M. A. De Gregorio¹

Received: 26 July 2016 / Accepted: 19 September 2016

© Springer Science+Business Media New York and the Cardiovascular and Interventional Radiological Society of Europe (CIRSE) 2016

To the Editor,

Intravascular pulmonary tumors are a very rare malignant neoplasm often originated from the intimal layer and commonly also known as pulmonary artery sarcomas (PAS). These tumors may resemble and have similar clinical and radiological findings as a pulmonary embolism (PE) as many authors have described this misdiagnosis with an acute PE or a chronic thromboembolic pulmonary hypertension [1]. CT or MRI should be performed in order to diagnose it [2]; nevertheless, the histological examination must be confirmed by an intraoperative surgical biopsy in most cases.

We present a 69-year-old male patient who was referred to our hospital for an endovascular mechanical and pharmacological thrombolysis with a diagnosis of a massive PE. The patient was admitted to the intensive care unit, and presented a grade 4 dyspnea of mMRC breathlessness scale and refers a progressive worsening since the last 5 days. No signs of hemodynamic instability or major ECG abnormalities were found on arrival. The transthoracic echocardiography revealed an hypertrophied right ventricle and a pulmonary arterial hypertension, and a D-Dimer of 207 ng/mL with no other significant findings (Fig. 1 A–B).

With the suspected diagnosis of PE and despite the absence of hemodynamic instability, a pulmonary angiography and a hemodynamic study were performed by recording pulmonary pressure (90/71/65 mmHg systolic, diastolic, and mean pulmonary pressure). Intraarterial

fibrinolytic therapy was initiated at a rate of 100,000 I.U. urokinase/hour for 24 h, demonstrating no morphological or pressure changes at 24 h (Fig. 1C). The existence of an intravascular tumor was suspected, and the tumor was biopsied using a 10-French Teflon guide catheter and a bronchoscopy forceps (Fig. 1D). The final histopathological diagnosis was an intimal sarcoma of the pulmonary artery.

The diagnosis of PAS, despite the findings provided by the CT and MRI, is never a pathognomonic sign. However, CT and MRI can show a mild contrast enhancement that can suggest a tumor over a thrombus [2]. Currently, pulmonary ventilation/perfusion PET-CT or CT with dual energy can provide a better assessment for the diagnosis [3, 4]. The histological diagnosis can be also performed by a percutaneous CT-guided biopsy in the case of PAS having metastasized pulmonary nodules or an infiltrating mediastinal mass [5, 6]. However, an intravascular biopsy with the help of biopsy forceps that are used in the bronchial tree or in the digestive tract is a safe and effective procedure for obtaining samples to establish the histopathological diagnosis. It requires training for the catheterization of the pulmonary arteries, and the biopsy device must be driven into the lesion using a catheter guide of a considerable size (10 Fr).

Compliance with Ethical Standards

Conflict of Interest The authors declare that they have no conflict of interest.

Informed consent Informed consent was obtained from all individual participants included in the study.

Research involving animal and human rights All procedures performed in studies involving human participants were in accordance with the ethical standards of the institutional and/or national research

✉ J. A. Guirola
joseandresguirola@gmail.com

¹ Minimally Invasive Techniques Research Group GITMI,
University of Zaragoza, Saragossa, Spain

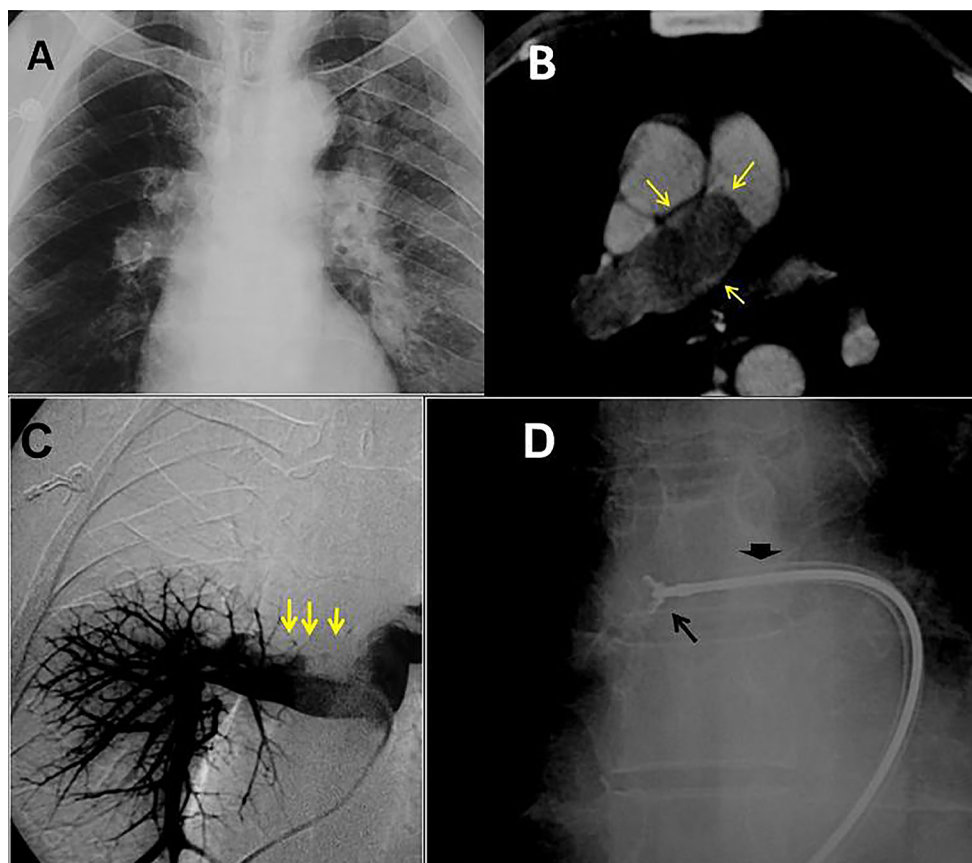


Fig. 1 **A** Plain chest X-ray showing a focal peripheral hyperlucency with the absence of pulmonary vessels in the right hemithorax (Westermark sign). **B** Thoracic CT axial view presenting an intravascular filling defect (*arrows*) that occupies the entire lumen of right pulmonary artery. **C** Right pulmonary angiogram

demonstrating a filling defect in the right pulmonary artery (*arrows*) with the absence of normal vascularization in the superior and middle lobes. **D** An intravascular biopsy with bronchoscopy forceps with the help of a 10-Fr guide catheter located in the right pulmonary artery (*thick arrow*)

committee and with the 1964 Helsinki declaration and its later amendments or comparable ethical standards.

References

1. Kauczor HU, Schwickert HC, Mayer E, et al. Pulmonary artery sarcoma mimicking chronic thromboembolic disease: computed tomography and magnetic resonance imaging findings. *Cardiovasc Interv Radiol.* 1994;17(4):185–9.
2. Bendel EC, Maleszewski JJ, Araoz PA. Imaging sarcomas of the great vessels and heart. *Semin Ultrasound CT MR.* 2011;32(5):377–404. doi:10.1053/j.sult.2011.06.001.
3. Guo Y, Wang T, Yang M. Pulmonary artery sarcoma detected on 18F-FDG PET/CT with unusual findings. *Clin Nucl Med.* 2015;40:530–1.
4. Altenbernd J, Wetter A, Umutlu L, Hahn S, Ringelstein A, Forsting M, et al. Dual-energy computed tomography for evaluation of pulmonary nodules with emphasis on metastatic lesions. *Acta Radiol.* 2016;57:437–43.
5. Tschirch FT, Del Grande F, Marincek B, Huisman TA. Angiosarcoma of the pulmonary trunk mimicking pulmonary thromboembolic disease. A case report *Acta Radiol.* 2003;44:504–7.
6. Coelho LS, Tanni SE, Ribeiro SM, Catâneo DC, Coletta JA, de Godoy I. Pulmonary artery sarcoma: a rare disease. *BMJ Case Rep.* 2010. doi:10.1136/bcr.08.2008.0689.