

Hemoptysis as the first symptom in the diagnosis of metastatic choriocarcinoma in the third trimester of pregnancy: A case report

Leticia Álvarez-Sarrado*, Isabel González-Ballano, Rebeca Herrero-Serrano, Claudia Giménez-Molina, Belén Rodríguez-Solanilla, José-Manuel Campillos-Maza

Department of Obstetrics, Miguel Servet Maternal University Hospital, Paseo Isabel la Católica, 1-3, 50009 Zaragoza, Spain

ARTICLE INFO

Article history:

Received 9 April 2020

Received in revised form 20 April 2020

Accepted 23 April 2020

Keywords:

Choriocarcinoma

Gestational trophoblastic neoplasia

Hemoptysis

Viable pregnancy

Case report

ABSTRACT

Introduction: Choriocarcinoma is a rare neoplasm (1/40000 pregnancies). In the context of a viable pregnancy, the incidence is even lower (1/160000).

Case report: A woman in her second pregnancy was admitted at 31 + 6 weeks of gestation with hemoptysis and abnormal vaginal bleeding. Numerous placental venous lakes, bilateral pulmonary nodules and a pleural effusion were found. Pleural fluid β -HCG levels were elevated and a brain-chest-abdominal-pelvic CT scan led to the diagnosis of a high-risk gestational trophoblastic neoplasm. A caesarean section at 32 + 1 weeks of gestation was performed. Six cycles of an EMA-CO chemotherapy regime were administered. β -HCG levels normalized after 3 cycles. Placental histopathology confirmed the presence of a gestational choriocarcinoma.

Conclusion: Choriocarcinoma is a highly aggressive tumor. In high-risk tumors, combination chemotherapy is the first-line treatment, offering high remission rates. Treatment response is evaluated by monitoring blood β -HCG levels, which should be long-term.

© 2020 The Authors. Published by Elsevier B.V. This is an open access article under the CC BY-NC-ND license (<http://creativecommons.org/licenses/by-nc-nd/4.0/>).

1. Introduction

Gestational choriocarcinoma is a highly aggressive tumor with the ability to produce early distant metastases [1]. Its incidence is estimated to be about 1 in 40,000 pregnancies. In the context of a viable gestation, the incidence is even lower (1 in 160,000 pregnancies) [2].

Several theories have been proposed to explain choriocarcinoma in an ongoing viable pregnancy. Conversion of normal trophoblast cells in the current gestation, transformation of residual trophoblast tissue from a previous pregnancy or conversion of one of the products of conception in a multiple pregnancy have been postulated [3].

Clinical presentation varies widely. Women may be asymptomatic or can present with abnormal vaginal bleeding, hemoptysis, dyspnea, headache, visual disturbances or jaundice. The last are suggestive of distant metastases. All cases are associated with significantly elevated β -HCG (beta human chorionic gonadotropin) levels [4].

Due to its high chemosensitivity, the treatment of choriocarcinoma is based on chemotherapy. The drug regime used is established according to the stage and risk score of the disease at the time of diagnosis. It is calculated from a combination of the International Federation of Gynecology and Obstetrics (FIGO) staging system and the World Health Organization

(WHO) prognostic scoring system. The first differentiates 4 stages based on the extent of the disease. The second gives a numerical score that takes into account the patient's and the tumor's characteristics [5].

Low-risk patients (FIGO stage I or stage II and III with a WHO risk score below 7) are treated with a single-agent chemotherapy regime (methotrexate or actinomycin-D) in order to maximize success rates while minimizing toxicity [6]. In contrast, first-line treatment in high-risk groups (FIGO stage IV or stage II and III with a WHO risk score over 6) is a multi-agent chemotherapy regime because of the risk of resistance to single-agent chemotherapy. The regime of choice is the combination of etoposide, methotrexate, actinomycin-D, cyclophosphamide and vincristine (EMA-CO) [7].

In low-risk groups, rates of complete remission after single-agent chemotherapy reach 80%, and an overall survival rate of almost 100% can be achieved by adding multi-agent therapy. Recurrence rates are less than 5%.

In high-risk groups, around 85% of stage II and 75% of stage III patients reach full remission after primary multi-agent chemotherapy. Overall cure rates reach 95–100% after secondary therapy. In stage IV groups, up to 80% of patients are ultimately cured with intensive multi-agent therapy and radiation or surgical adjuvant therapy when needed. Recurrence rates are 8–10%, depending on the initial stage [8].

We present the case of a 22-year-old woman with a stage III high-risk choriocarcinoma in the third trimester of pregnancy who presented with hemoptysis as her first symptom.

* Corresponding author.

E-mail address: leticiaalvarezsarrado@gmail.com (L. Álvarez-Sarrado).

2. Case Presentation

A 22-year-old woman in her so-far uncomplicated second pregnancy was admitted at 31 + 6 weeks of gestation with dyspnea and hemoptysis that had developed in the past week. Her first pregnancy had resulted in a spontaneous first-trimester abortion.

The hemoptysis was associated with coughing fits and pulse oximetry peripheral oxygen saturation was 95%. She also had painless vaginal bleeding. A purplish friable nodular lesion of 1 cm in the back wall of the vagina close to the introitus was found on pelvic examination. She was hemodynamically stable and the CTV was normal. An abdominal ultrasound scan (Fig. 1) showed a posterior fundal placenta with many large venous lakes. Her blood β -HCG level was elevated at 267789.41 mIU/ml, while the level in the pleural fluid was 149,584 mIU/ml. Chest radiography (Fig. 2) showed various bilateral pulmonary nodes of up to 20 mm, suggestive of metastases, as well as bilateral pleural effusions. A brain-chest-abdominal-pelvic CT scan (Fig. 3) confirmed bilateral pulmonary metastases and pleural effusions. It also showed a heterogeneous posterior placenta with nodular growth.

Diagnosis of a high-risk stage III gestational trophoblastic neoplasm was made. After fetal pulmonary maturation with 2 doses of 12 mg of intramuscular betamethasone 24 h apart, an elective caesarean section at t32 + 1 weeks of gestation was performed. A 1400-gram girl was delivered, with Apgar scores of 9 after 1 min and 10 after 5 min, and venous pH 7.40. The placenta was removed manually; the neoplasm measured 4 × 3 cm (Fig. 4).

The next day, chemotherapy treatment with EMA-CO was started, which resulted in progressive improvement. The vaginal lesion disappeared after the first cycle of chemotherapy. Remission of the disease (defined as 3 blood tests with undetectable β -HCG levels one week apart) was achieved after 3 cycles of chemotherapy (51 days after the start of treatment). Consolidation therapy comprised three additional cycles.

Placental histopathology (Fig. 5) confirmed the presence of a gestational choriocarcinoma. One year after diagnosis, with continuing monthly β -HCG monitoring, the patient remained in complete remission.

3. Discussion

When diagnosing gestational trophoblastic neoplasia, differential diagnoses include invasive hydatidiform mole, choriocarcinoma,

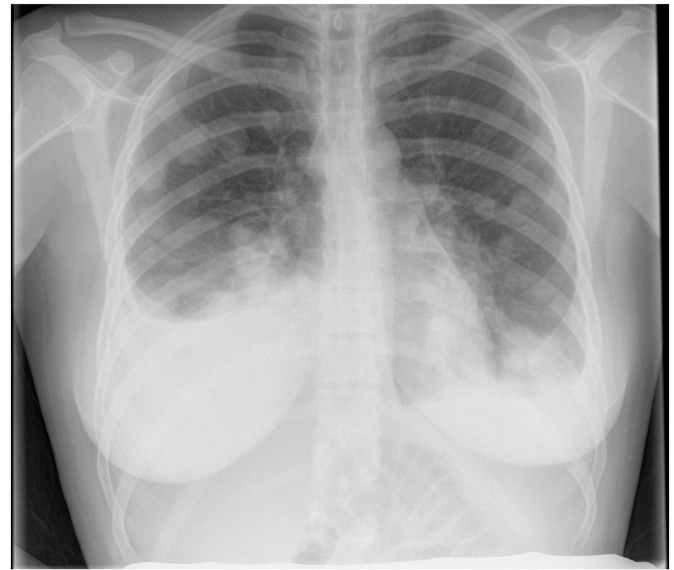


Fig. 2. Chest radiograph: bilateral pulmonary nodes of up to 20 mm suggestive of metastases and bilateral pleural effusion.

placental site trophoblastic tumor and epithelioid trophoblastic tumor. In contrast to other tumors, gestational trophoblastic neoplasia is a clinical diagnosis and no tissue for a definitive histopathologic confirmation is needed prior to treatment. A persistent or abnormal elevation of β -HCG levels along with the identification of clinical or radiological evidence of distant metastases support the diagnosis. Biopsies of distant lesions should not be performed because of the risk of hemorrhage due to their significant vascularisation.

For this reason, pre-treatment evaluation is vital to ascertain the nature of the tumor and assess stage and risk score of the disease to guide the most appropriate treatment.

Invasive hydatidiform mole is the most frequent trophoblastic tumor. It is characterized by an invasion of the myometrium together with the presence of distant metastases. Diagnosis is confirmed by imaging and β -HCG levels, and chemotherapy is the treatment of choice. Placental site trophoblastic tumor and epithelioid trophoblastic tumor represent less than 1% of all gestational trophoblastic tumors. Blood β -HCG levels are low and they metastasise late. Surgery is the first-line treatment, while chemotherapy is reserved for disseminated disease [9].

Among all gestational trophoblastic tumors, choriocarcinoma is the most aggressive histologic type, presenting the highest rate of metastasis at the time of diagnosis, the most common being lung metastases (80%), followed by vaginal (30%), brain (10%) and hepatic metastases (10%) [10]. Because of its high vascularity, abnormal bleeding at those locations could be the first clinical manifestation.

In our case, the patient presented with painless vaginal bleeding and hemoptysis. The differential diagnosis of third-trimester vaginal bleeding includes, apart from trophoblastic tumors, abruptio placentae, placenta praevia, vasa previa and uterine rupture. She was hemodynamically stable. No uterine activity or fetal heart rate abnormalities were present. Hemoptysis can be the first symptom in many diseases, including lung cancer, infectious disease such as tuberculosis or pulmonary thromboembolism. The X-ray image along with the pleural fluid cytology, culture and biochemical analysis allowed these pathologies to be excluded in our patient.

After the presence of lung metastases, high β -HCG levels in pleural fluid and a nodular growth in the placenta, a high-risk gestational

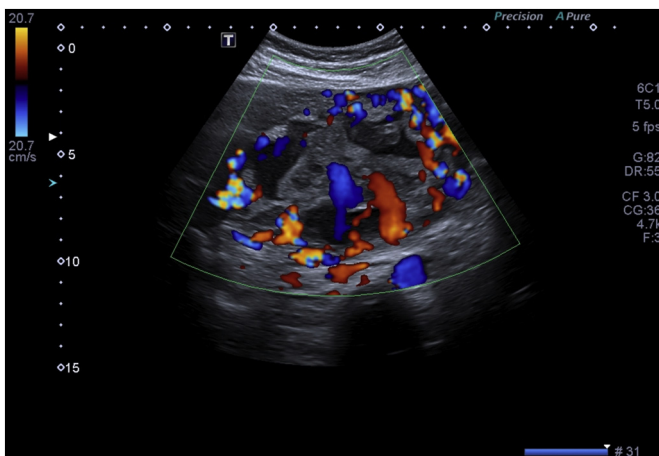


Fig. 1. Abdominal ultrasound: fund posterior placenta with many large venous lakes shown with doppler colour.

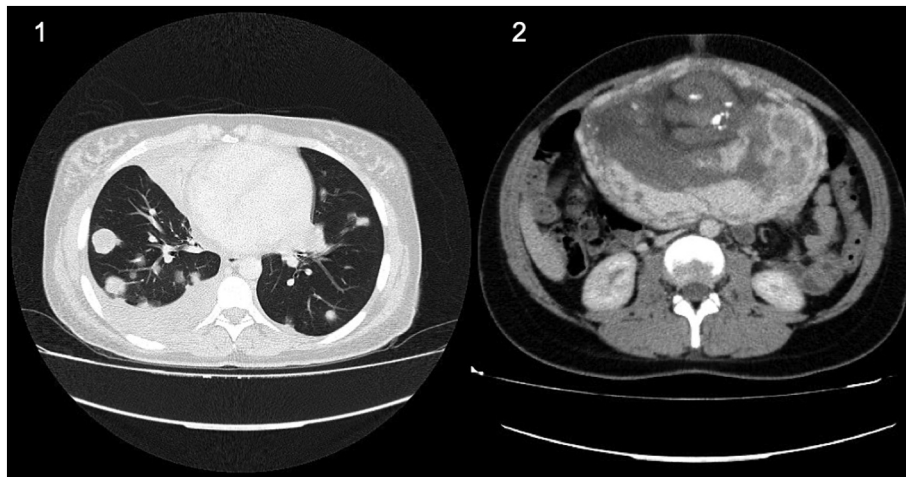


Fig. 3. Full-body CT scan: (1) bilateral pulmonary metastases and bilateral pleural effusion. (2) heterogeneous posterior placenta with mamelons and nodular growth.

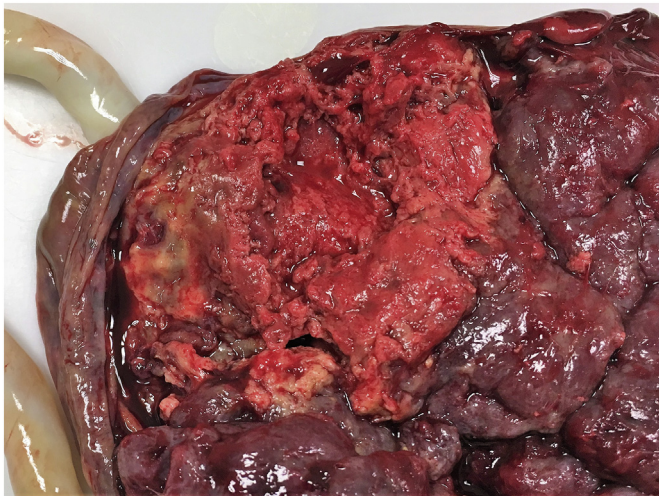


Fig. 4. Placental node measuring 4 × 3 centimeters surrounded by necrotic tissue.

trophoblastic tumor was diagnosed, FIGO stage III (lung metastases with or without genital tract involvement) with a risk score of 10 points in the WHO prognostic scoring system [11].

In high-risk patients, the combination regime that has shown the best cure rate is EMA-CO (Etoposide, Methotrexate, Actinomycin D, Cyclophosphamide and Vincristine) [12]. It is administered every

two weeks until β -HCG levels become undetectable for three consecutive weeks, at which point remission is considered to have been achieved. Subsequently, at least three courses of EMA-CO must be administered (known as consolidation therapy) [13]. In our patient, remission was reached after 3 courses of chemotherapy, and 3 additional courses were given to complete consolidation therapy.

In high-grade gestational trophoblastic tumors, follow-up is undertaken by monitoring blood β -HCG levels. Monthly determinations over at least 18 months, and then semi-annually for 2 years and yearly for up to 5 years are required [14].

The 5-year survival rate in high-risk stage III trophoblastic tumors is high (up to 95%) [15]. After a year, our patient was continuing with monthly β -HCG determinations, which had thus far proven negative.

In conclusion, choriocarcinoma in a viable pregnancy is rare. Due to its aggressiveness and capacity to produce distant metastases, abnormal bleeding from different organs in pregnant women alert the clinician to this kind of pathology.

Contributors

Leticia Álvarez-Sarrado contributed to design and drafting of the article.

Isabel González-Ballano contributed to design and drafting of the article.

Rebeca Herrero-Serrano contributed to acquisition of data.

Claudia Giménez-Molina contributed to acquisition of data.

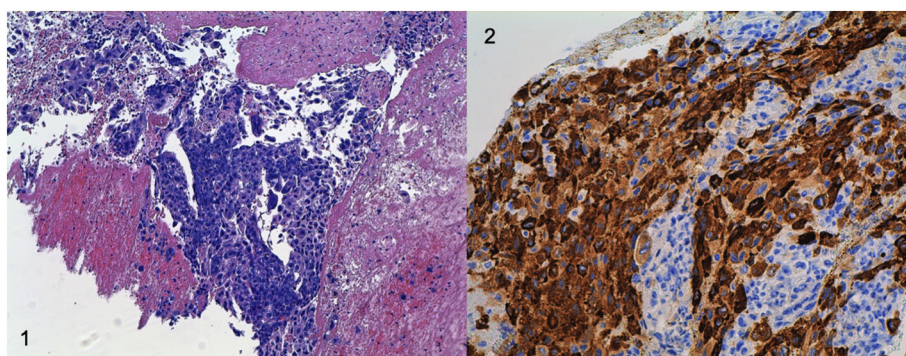


Fig. 5. (1) H&E (Hematoxylin and eosin) ×10: choriocarcinoma showing malignant cytotrophoblast and syncytiotrophoblast cells with normal chorionic villi. (2) HPL (human placental lactogen) ×20: malignant cytotrophoblast and syncytiotrophoblast cells positive for β -HCG by immunostaining.

Belén Rodríguez-Solanilla was responsible for critical manuscript revision.

José-Manuel Campillos-Maza was responsible for final approval of the version to be submitted.

Conflict of Interest

The authors declare that they have no conflict of interest regarding the publication of this case report.

Funding

No specific grant from funding agencies in the public, commercial, or not-for-profit sectors supported the publication of this case report.

Patient Consent

Obtained.

Provenance and Peer Review

This case report was peer reviewed.

References

- [1] A. Braga, V. Campos, J.R. Filho, L.H. Lin, S.Y. Sun, C.B. de Souza, et al., Is chemotherapy always necessary for patients with nonmetastatic gestational trophoblastic neoplasia with histopathological diagnosis of choriocarcinoma? *Gynecol. Oncol.* 148 (2) (2018 Feb) 239–246.
- [2] J.T. Soper, D.G. Mutch, J.C. Schink, American College of Obstetricians and Gynecologists, Diagnosis and treatment of gestational trophoblastic disease: ACOG Practice Bulletin No. 53, *Gynecol. Oncol.* 93 (3) (2004 Jun) 575–585.
- [3] P. Yu, W. Diao, X. Jiang, A successfully treated metastatic choriocarcinoma coexistent with pregnancy: a case report of a 4-year follow-up, *Medicine (Baltimore)* 95 (21) (2016 May), e3505.
- [4] L. Jiao, E. Ghorani, N.J. Sebire, M.J. Seckl, Intraplacentar choriocarcinoma: systematic review and management guidance, *Gynecol. Oncol.* 141 (3) (2016 Jun) 624–631.
- [5] H.Y.S. Ngan, M.J. Seckl, R.S. Berkowitz, Y. Xiang, F. Golfier, P.K. Sekharan, et al., Update on the diagnosis and management of gestational trophoblastic disease, *Int. J. Gynaecol. Obstet.* 143 (Suppl. 2) (2018 Oct) 79–85.
- [6] S. Dhanda, S. Ramani, M. Thakur, Gestational trophoblastic disease: a multimodality imaging approach with impact on diagnosis and management, *Radiol. Res. Pract.* 2014 (2014) 842751.
- [7] M.S. Cagayan, High-risk metastatic gestational trophoblastic neoplasia. Primary management with EMA-CO (etoposide, methotrexate, actinomycin D, cyclophosphamide and vincristine) chemotherapy, *J. Reprod. Med.* 57 (2012) 231.
- [8] T. May, D.P. Goldstein, R.S. Berkowitz, Current chemotherapeutic management of patients with gestational trophoblastic neoplasia, *Chemother. Res. Pract.* 2011 (2011) 806256, <https://doi.org/10.1155/2011/806256>.
- [9] I. Niemann, L.O. Vejerslev, L. Frøding, J. Blaakær, L.L. Maroun, E.S. Hansen, et al., Gestational trophoblastic diseases – clinical guidelines for diagnosis, treatment, follow-up, and counselling, *Dan. Med. J.* 62 (11) (2015 Nov) A5082.
- [10] P. Wreczycka-Cegiely, T. Cegiely, M. Oplawski, W. Sawicki, Z. Kojs, Current treatment options for advanced choriocarcinoma on the basis of own case and review of the literature, *Ginekol. Pol.* 89 (12) (2018) 711–715.
- [11] Z. Ren, L. Yu, M. Xie, Y. Liang, F. Zhu, R. Huang, et al., Successful treatment of multi-site hemorrhage by several methods in brain metastasis of choriocarcinoma: a case report, *Medicine (Baltimore)* 97 (21) (2018 May), e10794.
- [12] T. Turan, O. Karacay, G. Tulunay, et al., Results with EMA/CO (etoposide, methotrexate, actinomycin D, cyclophosphamide, vincristine) chemotherapy in gestational trophoblastic neoplasia, *Int. J. Gynecol. Cancer* 16 (2006) 1432.
- [13] J. Brown, R.W. Naumann, M.J. Seckl, J. Schink, 15years of progress in gestational trophoblastic disease: scoring, standardization, and salvage, *Gynecol. Oncol.* 144 (1) (2017 Jan) 200–207.
- [14] A. Santaballa, Y. García, A. Herrero, N. Laínez, J. Fuentes, A. De Juan, et al., SEOM clinical guidelines in gestational trophoblastic disease (2017), *Clin. Transl. Oncol.* 20 (1) (2018 Jan) 38–46.
- [15] M.J. Seckl, N.J. Sebire, R.S. Berkowitz, Gestational trophoblastic disease, *Lancet* 376 (9742) (2010 Aug 28) 717–729.