

REVIEW

Pigmented Purpuric Dermatitis: A Review of the Literature[☆]



I. Martínez Pallás,^{*} R. Conejero del Mazo, V. Lezcano Biosca

Servicio de Dermatología y Venereología, Hospital Clínico Lozano Blesa, Zaragoza, Spain

Received 21 October 2018; accepted 24 February 2019

Available online 20 March 2020

KEYWORDS

Purpuric pigmented dermatosis;
Review;
Clinical presentation;
Treatment

PALABRAS CLAVE

Dermatitis purpúrica pigmentada;
Revisión;
Presentación clínica;
Tratamiento

Abstract The pigmented purpuric dermatoses (PPDs) are a group of benign, chronic diseases. The variants described to date represent different clinical presentations of the same entity, all having similar histopathologic characteristics. We provide an overview of the most common PPDs and describe their clinical, dermatopathologic, and epiluminescence features. PPDs are both rare and benign, and this, together with an as yet poor understanding of the pathogenic mechanisms involved, means that no standardized treatments exist. We review the treatments described to date. However, because most of the descriptions are based on isolated cases or small series, there is insufficient evidence to support the use of any of these treatments as first-line therapy.

© 2019 AEDV. Published by Elsevier España, S.L.U. This is an open access article under the CC BY-NC-ND license (<http://creativecommons.org/licenses/by-nc-nd/4.0/>).

Dermatitis purpúricas pigmentadas. Revisión de la literatura científica

Resumen Las dermatosis purpúricas pigmentadas (DPP) son un grupo de enfermedades benignas y de curso crónico. Las variantes descritas representan distintas formas clínicas de una misma entidad con unas características histopatológicas comunes para todas ellas. Exponemos a continuación un resumen de las variedades más frecuentes, sus características clínicas, dermatopatológicas y de epiluminiscencia. Al tratarse de una entidad clínica poco frecuente, benigna, y no conocerse claramente los mecanismos patogénicos de la misma, no existen tratamientos estandarizados. Se revisan los tratamientos publicados hasta el momento, la mayoría de ellos basados en casos aislados o pequeñas series de casos, sin poder establecer un nivel de evidencia suficiente como para ser recomendado ninguno de ellos como tratamiento de elección.

© 2019 AEDV. Publicado por Elsevier España, S.L.U. Este es un artículo Open Access bajo la licencia CC BY-NC-ND (<http://creativecommons.org/licenses/by-nc-nd/4.0/>).

[☆] Please cite this article as: Martínez Pallás I, Conejero del Mazo R, Lezcano Biosca V. Dermatitis purpúricas pigmentadas. Revisión de la literatura científica. Actas Dermosifiliogr.2020;111:196–204.

^{*} Corresponding author.

E-mail address: isabel_mp91@hotmail.com (I. Martínez Pallás).

Table 1 Drugs Associated With the Pigmented Purpuric Dermatoses.

Sedatives	Phenobarbital, chlorthalidone, meprobamate
Vitamins	Thiamine (B ₁)
Diuretics	Furosemide
Cardiovascular drugs	Nitroglycerine, bezafibrate, hydralazine, dipyridamole, sildenafil
Antibiotics	Ampicillin
Analgesics	Nonsteroidal anti-inflammatory drugs, aspirin, acetaminophen
Stimulants	Pseudoephedrine
Hormones	Medroxyprogesterone acetate
Antidiabetic drugs	Glipizide
Chemotherapy agents	Topical 5-fluorouracil
Antivirals	Interferon α
Retinoids	Isotretinoin

Source: Kaplan et al.⁸

Introduction

The pigmented purpuric dermatoses (PPDs) are a rare group of chronic, benign diseases characterized by multiple petechiae on hyperpigmented, yellowish-brown macules.¹ The different variants are distinct clinical forms of the same entity with similar histopathologic features.^{2,3}

There are 5 classic variants: Schamberg disease (progressive PPD), eczematoid purpura of Doucas and Kapetanakis (pruritic purpura), pigmented purpuric lichenoid dermatosis of Gougerot and Blum, lichen aureus (lichen purpuricus), and Majocchi disease (purpura annularis telangiectodes).¹ Less common variants are granulomatous PPD, itching purpura of Loewenthal, linear PPD, transitory PPD, and familial PPD.²

Epidemiology

PPDs are rare and predominantly affect adults,¹ although cases have been reported in children.⁴ The most common variant in both adults and children is Schamberg disease. PPDs, and linear forms in particular,⁶ are generally more common in men.¹ Majocchi disease is more common in women.

Etiology and Pathogenesis

Although the causes of the PPDs are unknown, a range of triggering factors have been proposed, including exercise, venous hypertension, diabetes mellitus, infections,^{2,7} and various medications (Table 1).⁸ An association with dyslipidemia and autoimmune diseases has been reported for granulomatous PPD.⁹ In most cases, however, no cause is identified.¹⁰

Capillary dilation and fragility have been attributed a possible pathogenic role in PPDs.¹⁰ It has been hypothesized that the cells responsible for these disorders are cells involved in blood vessel structure, such as fibroblasts and endothelial cells. Whether through activation (e.g., high

intravascular pressure) or spontaneously, the function of these cells may be altered, causing red blood cells (RBCs) to leak through the vessel walls,¹¹ triggering a cell-mediated hypersensitivity reaction. Cell-mediated immune response would therefore appear to have a fundamental role in the pathogenesis of PPDs.^{12,13} The perivascular inflammatory infiltrate is made up of CD4⁺ T cells¹⁴ (with reduced CD7 expression¹⁵) and CD1a⁺ dendritic cells.¹²

The pathogenic role of cell adhesion molecules in PPDs has also been analyzed in several studies. CAMs are membrane proteins that interact with specific ligands that provide and maintain contact between different cells and between cells and extracellular matrix proteins. High expression levels have been observed for adhesion molecules LFA-1 (lymphocyte function antigen-1) and ICAM-1 (intercellular adhesion molecule-1) in inflammatory cells and for ICAM-1 and ELAM-1 (endothelial leukocyte adhesion molecule-1)¹² in endothelial cells. T cells activated by an antigenic stimulus would thus adhere to endothelial cells, fibroblasts, and keratinocytes.¹⁶ Cytokines produced by leukocytes (e.g., tumor necrosis factor α) can trigger the expression of these adhesion molecules (Fig. 1).

The above cytokines may also result in a decreased release of the endothelial plasminogen activator and/or an excessive increase in the plasminogen activator inhibitor,¹⁷ leading to the reduced fibrinolytic activity and intraperivascular deposition of fibrin observed in PPDs.¹⁸

Direct immunofluorescence may show fibrinogen, immunoglobulin M, and/or C3 deposition in the superficial dermal vessels.¹⁰

Another hypothesis that has emerged in recent years is that PPDs may represent an insidious epitheliotropic T-cell alteration. This theory is supported by the observation of epidermotropism or a monoclonal pattern in the inflammatory infiltrate.^{15,19} There have even been some reports of progression to mycosis fungoides.²⁰⁻²² As it is difficult to distinguish between purpuric mycosis fungoides and monoclonal PPD, it is essential to integrate clinical, molecular, and histopathologic findings.^{15,20,23} Poikiloderma, pruritus, coalescing plaques, a duration of more than 1 year, a monoclonal pattern, and decreased CD7 and CD62L expression in the infiltrate should all raise suspicion of disease progression, even in the absence of overt lymphocytic atypia.^{15,24} Some authors opt to treat disseminated and monoclonal DPP as early-stage mycosis fungoides.

Clinical Variants

Progressive PPD or Schamberg Disease^{1,2}

In progressive PPD or Schamberg disease, lesions usually appear on both lower extremities, but they can also affect the trunk, arms, thighs, or buttocks. They present as orange-red macules with peripheral purpuric spots resembling grains of cayenne pepper (Fig. 2A and B); these spots acquire a yellowish-brown color as they progress. The lesions are generally asymptomatic, although some patients describe pruritus. They follow a chronic course with numerous relapses and remissions.

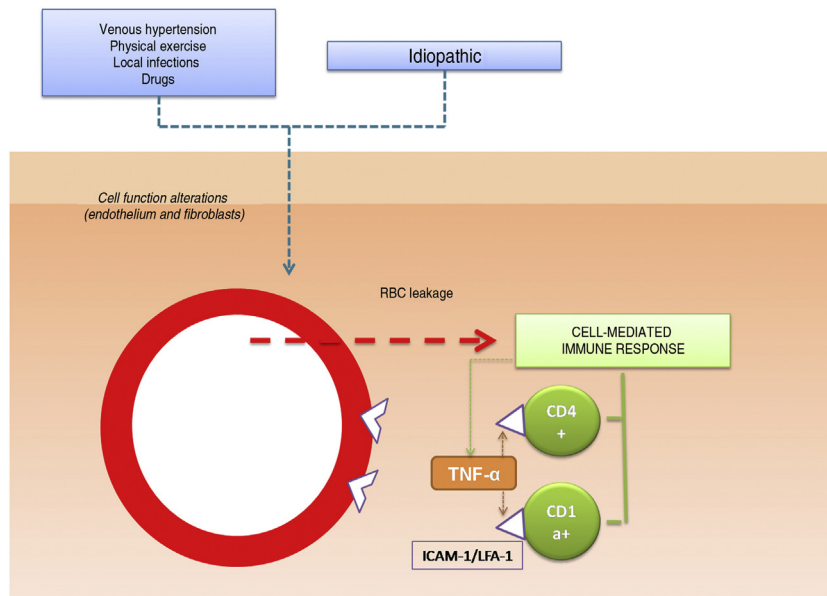


Figure 1 Etiologic and pathogenic mechanism. One of the most widely accepted hypotheses is that T cells are activated by an antigenic stimulus and bind to endothelial cells, fibroblasts, and keratinocytes through the expression of adhesion molecules. TNF- α indicates tumor necrosis factor α ; ICAM-1, intercellular adhesion molecule-1; LFA-1, lymphocyte function antigen-1.

Pruritic Purpura or Eczematoid Purpura of Doucas And Kapetanakis^{1,25}

Pruritic purpura or eczematoid purpura of Doucas and Kapetanakis is the most extensive and pruritic variant of the PPDs. It mostly affects the lower extremities and is clinically similar to Schamberg disease, with purpuric or petechial macules but with a scaling surface. Eczematoid purpura of Doucas and Kapetanakis has been associated with allergic contact dermatitis to rubber and clothing. Onset is rapid (15–30 days) and the lesions can last for months or years.

Pigmented Purpuric Lichenoid Dermatitis of Gougerot and Blum^{1,2,26}

Lichenoid pigmented purpuric dermatosis of Gougerot and Blum is characterized by violaceous lichenoid papules that tend to merge, forming large plaques that are usually located on the legs but may affect the trunk. The condition follows a chronic course and usually affects elderly men. It should be distinguished from Kaposi sarcoma.

Lichen Aureus or Lichen Purpuricus^{1,2,27}

Lichen aureus or lichen purpuricus is a more localized variant of PPD. Lesions are persistent and are typically solitary or small in number. Lichen aureus is characterized by the sudden appearance of small yellow-orangish papules with a lichenoid appearance and a tendency to coalesce into plaques measuring between 1 and 20 cm associated with millimetric purpuric lesions (Fig. 3). The condition mostly affects the lower extremities, but lesions can occur on any part of the body. They are usually asymptomatic. Zosteriform²⁸ and segmental variants along the lines of Blaschko²⁹ or following the course of the saphenous³⁰ or

cephalic veins³¹ have been described in children and adolescents.

Purpura Annularis Telangiectodes or Majocchi Disease^{1,2,25}

Purpura annularis telangiectodes or Majocchi disease presents with annular red-violaceous macules (Fig. 4), followed by darker red telangiectatic puncta. The lesions extend peripherally and their center gradually fades and may acquire an atrophic appearance. The eruption begins in the lower extremities and then spreads to the trunk and arms; it is characterized by large numbers of lesions. A variant known as *arciform purpura annularis telangiectodes* featuring fewer but larger lesions with a characteristic arched morphology has been described.³²

Other Variants

Hersch and Schwyder³³ described what is considered to be a rare linear, unilateral form that must be differentiated from linear forms of Schamberg disease and lichen aureus. Higgins and Cox³⁴ described a quadrant form they attributed to a vascular obstruction in the pelvis.

There have also been reports of a transitory variant³⁵ including entities such as angioma serpiginosum,³⁶ which is an uncommon vascular disorder that usually begins in childhood, is more common in females, and shows evidence of estrogen dependence. Angioma serpiginosum is characterized by multiple asymptomatic red-purpuric macules arranged in small groups following a serpiginosum pattern along the extremities.

Itching purpura of Loewenthal,³⁷ which has only been described in adults, is considered a more symptomatic variant of Schamberg disease.

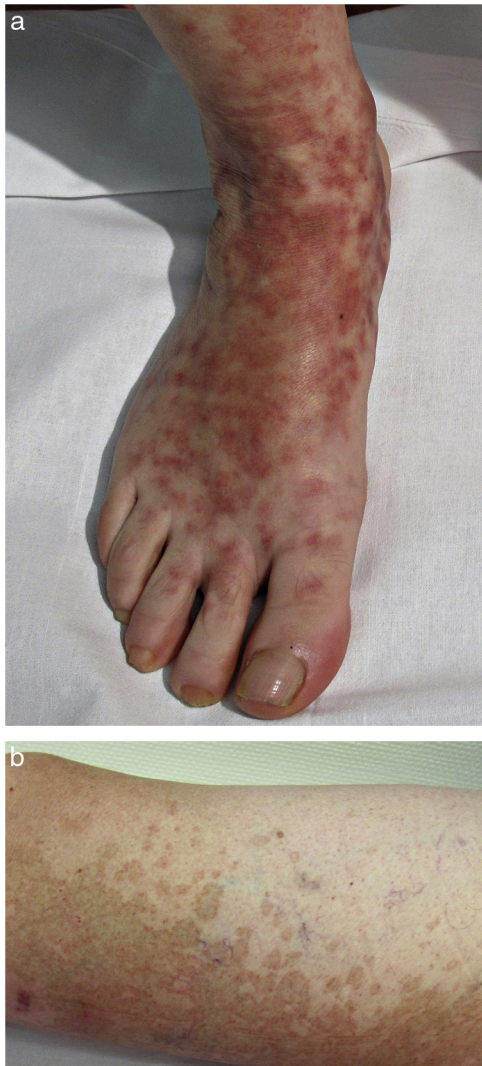

Figure 2 Schamberg disease. A, Orange-red macules that tend to coalesce, forming large plaques. B, Peripheral cayenne pepper spots.

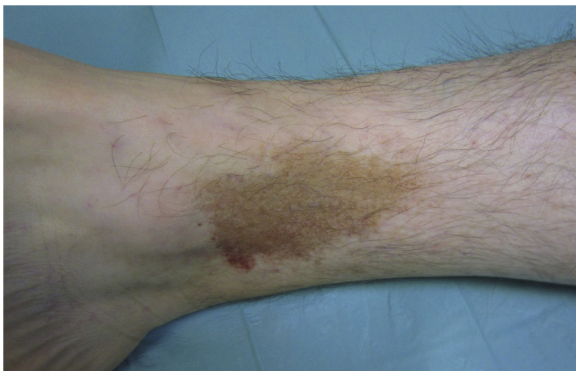

Figure 3 Lichen aureus. Solitary plaque comprising small coalescing yellow-orange macules on the leg.

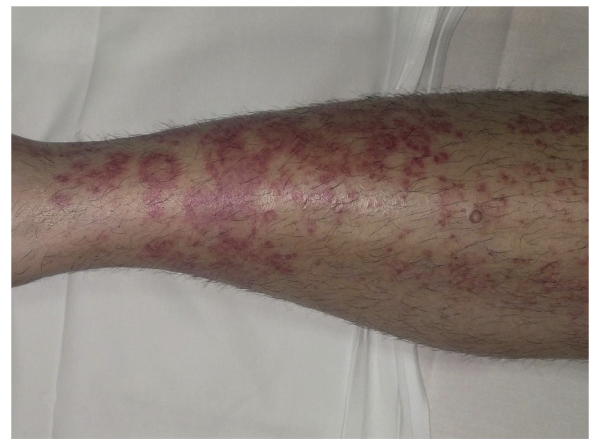

Figure 4 Majocchi disease. Annular red-violaceous lesions on the leg.

Granulomatous PPD, described by Saito,³⁸ is a histopathologic form that is more common in women and is clinically indistinguishable from other DPPs.

Finally, there have been reports of autosomal dominant familial forms of Schamberg disease and purpura annularis telangiectoides.³⁹

Histopathology

Histopathologically, PPDs are characterized by a perivascular lymphocytic infiltrate centered on the superficial small vessels. Other typical findings are endothelial swelling, luminal narrowing,¹⁰ extravasated RBCs, and hemosiderin-laden macrophages (Fig. 5 A and B). Perls and Fontana-Masson staining shows hemosiderin (iron) deposits in the superficial dermis, setting DPP apart from stasis dermatitis, which has deeper deposits.²

A characteristic finding of lichen aureus is an intact epidermis separated from a band-like dermal infiltrate by an area of spared connective tissue (Grenz area)²⁷ (Fig. 6). This infiltrate is also typical in pigmented purpuric lichenoid dermatosis of Gougerot and Blum.²⁶ Eczematoid purpura of Doucas and Kapetanakis, by contrast, features epidermal spongiosis and neutrophils in the infiltrate.²⁵ Granulomatous PPD is characterized by a perivascular granulomatous infiltrate overlying typical features.³⁸ A comparison of clinical features, location, and histopathologic findings for the most common variants of PPD is provided in Table 2.

While some authors^{1,13} consider capillaritis to be a defining feature of DPPs, Ackerman⁴⁰ does not believe this to be the case as there is an absence of fibrin in the luminal wall and thrombi in the lumina.

Diagnosis

In addition to skin biopsy, a blood test is recommended to rule out thrombocytopenia, clotting or autoimmune disorders (antinuclear antibodies, rheumatoid factor), and chronic infections (anti-HCV and anti-HBsAg).²

Table 2 Clinical and Histopathologic Characteristics of the Pigmented Purpuric Dermatoses.

Variant	Clinical Presentation	Location	Histopathologic Findings
Schamberg disease	Red-orange macules with peripheral spots resembling grains of cayenne pepper	Lower limbs and occasionally trunk, arms, thighs, and buttocks	Lymphocytic infiltrate involving the superficial small vessels, extravasated red blood cells, and hemosiderin-laden macrophages
Ecematoid purpura of Doucas and Kapetanakis	Similar to manifestations of Schamberg disease but with scaling and intense itching	Lower limbs	Infiltrate with higher number of neutrophils and epidermal spongiosis
Pigmented purpuric lichenoid dermatosis of Gougerot and Blum	Violaceous lichenoid papules that merge to form plaques	Lower limbs	Band-like dermal infiltrate
Lichen aureus	Isolated persistent red-orange plaque and purpuric lesions	Lower limbs	Unchanged epidermis and band-like dermal infiltrate with Grenz area
Majocchi disease	Peripherally extending plaques with telangiectatic punta at edges and fading in the central area	Lower limbs and trunk	Identical to Schamberg disease

Table 3 Differential Diagnosis for the Pigmented Purpuric Dermatoses.

Clinical Entities	Main characteristics
<i>Drug-hypersensitivity reactions</i> Carbamazepine, meprobamate, chlordiazepoxide, furosemide, nitroglycerine, vitamin B ₁ , and topical 5-fluorouracil	Recent use of causative drug
<i>Purpuric contact dermatitis to clothing</i> Wool, coloring agents	Lesions confined to areas of the skin in contact with clothing; intense itching
<i>Venous stasis purpura</i>	Signs of chronic venous insufficiency: swelling, varicose veins, feeling of heaviness, venous ulcers Hemosiderin deposition in deep dermis
<i>Purpura due to thrombocytopenia</i> <i>Senile purpura</i>	Associated with platelet count < 100–150000/ μ L In elderly patients, purpura can be associated with antiplatelet, anticoagulant, or corticosteroid use
<i>Purpuric exanthema due to viral infection</i> <i>Leukocytoclastic vasculitis</i>	Other signs of infection Palpable purpuric lesions On histology: fibrinoid necrosis, endothelial swelling, and leukocytoclasia
<i>Schönlein-Henoch purpura</i>	Age, 3–15 years; symmetric purpura affecting legs and buttocks; joint and abdominal pain
<i>Kaposi sarcoma</i>	Affects elderly or immunosuppressed patients On histology: spindle cells in the dermis forming irregular vascular lumina
<i>Purpuric mycosis fungoides</i>	Onset > 1 year; disseminated, monoclonal profile in infiltrate and loss of CD7

Source: Sardana et al.², Kim et al.,²⁵ and Risikesan et al.²⁶

Differential Diagnosis

The differential diagnosis should include other conditions featuring purpuric manifestations involving the lower extremities. These entities and their main characteristics are summarized in Table 3.

Dermoscopy

The most common dermoscopic finding is a diffuse coppery-red background that histopathologically corresponds to the lymphocytic dermal infiltrate, extravasated RBCs, and hemosiderin-laden macrophages.⁴¹ Other findings include

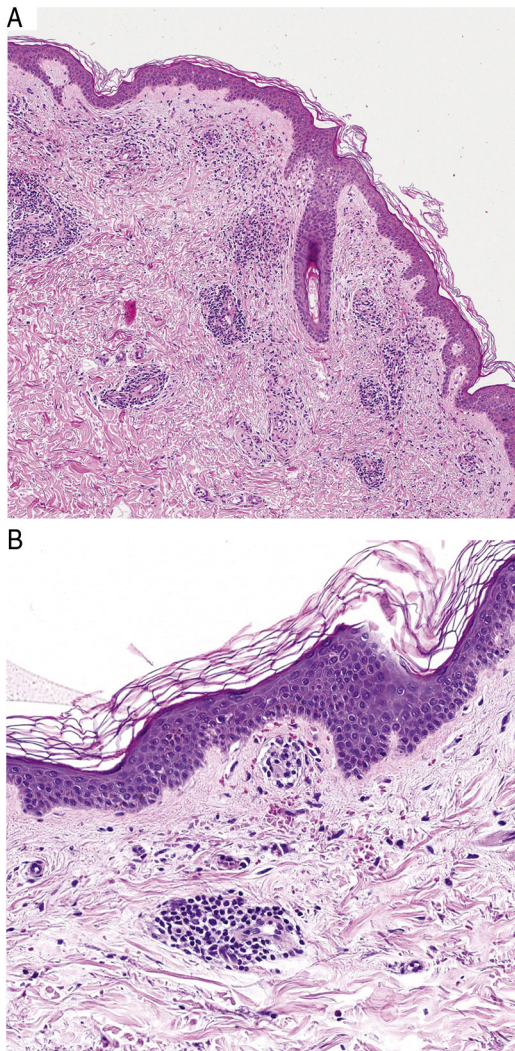


Figure 5 Histopathological features of Schamberg disease. A, Infiltrate involving small vessels in the superficial dermis. B, Lymphocytic infiltrate, with luminal narrowing and extravasated red blood cells.

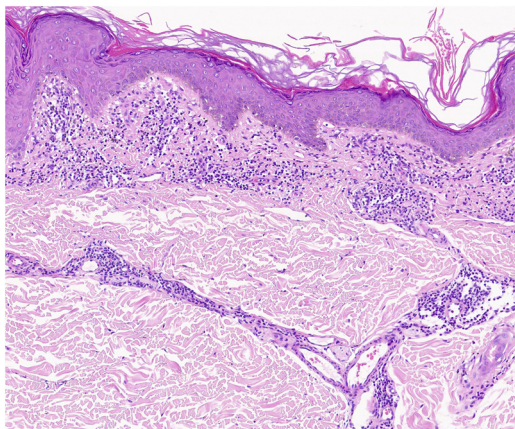


Figure 6 Histopathologic features of lichen aureus. Band-like infiltrate in the papillary dermis and superficial perivascular infiltrate.

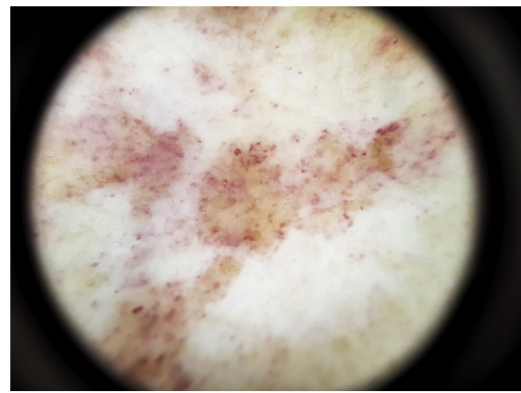


Figure 7 Dermoscopic features of Schamberg disease. Coppery-red background and red globules.

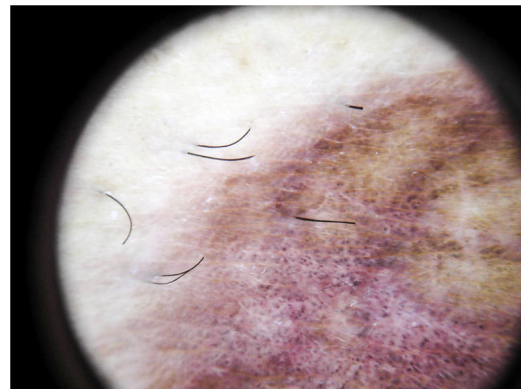


Figure 8 Dermoscopic features of lichen aureus. Brownish-red background with gray dots and a pigmented pseudo-network.

red globules and dots, which can be explained by the extravasated RBCs, the increased number of blood vessels, and the dilation of these vessels⁴² (Fig. 7). Brown dots are observed in almost 50% of patients and correspond to the spherical or elliptical arrangement of melanocytes and melanophages at the dermoepidermal junction. In a third of cases, dermoscopy shows a pigmented pseudo-network that corresponds to the hyperpigmented basal cell layer and incontinentia pigmenti in the papillary dermis. Specific dermoscopic findings reported for lichen aureus include a coppery-red background with brown and red dots and globules, gray dots, and a pseudo-network comprising interconnected pigmented lines⁴³ (Fig. 8).

Treatment

Considering that DPPs are benign and no standardized treatments with proven effectiveness exist, the risks and benefits of any treatment should be carefully weighed up.

Due to the benign, largely asymptomatic nature of the DPPs, no treatment is an option.⁴ Treatment, however, is often called for because of the chronic nature of the disease, its physical and psychological impacts, and the presence of extensive lesions or itching.

Most of the treatment recommendations are based on small case series, and none of them are backed by sufficient evidence to be considered a universal treatment.

A range of topical and systemic treatments, detailed below, have been described in small series and case reports.

Topical Treatments

Topical Corticosteroids

Topical corticosteroids are the most common treatments described and have been observed to reduce itching and in some cases clear lesions.^{2,4}

The most widely used agents are medium- and high-potency corticosteroids (clobetasol and methylprednisolone aceponate)

Topical Calcineurin Inhibitors

Topical application of tacrolimus⁴⁴ and pimecrolimus⁴⁵ for several months has been found to resolve lichen aureus.

Given the chronic nature of PPD lesions and the need for long-term treatment, calcineurin inhibitors can be considered a good alternative to topical corticosteroids for clearing or resolving lesions.

Phototherapy

Phototherapy is a good option for treating extensive disease or PPD that does not respond to topical corticosteroids or calcineurin inhibitors.

It has been postulated that phototherapy may be effective because it produces an immunomodulatory effect that modifies T-cell activity and reduces the production of interleukin 2, resulting in improvement.⁴⁶

Psoralen and UV-A (PUVA) treatment has been used successfully in patients with Schamberg disease, lichenoid purpuric dermatosis, and lichen aureus. In the series published to date, between 7 and 29 sessions with cumulative doses ranging from 16 to 49 J/cm² have been needed to achieve remission. Retreatment has also proven effective, and in some cases maintenance treatment over several months has been necessary to prolong response.^{2,47–49}

Narrowband UV-B phototherapy with cumulative doses of between 11 and 49 J/cm² administered in 24 to 60 sessions has produced favorable responses in patients with different clinical variants of DPP. As with PUVA treatment, there have been reports of recurrence after treatment discontinuation but good response to retreatment.^{46,50,51}

Narrowband UV-B therapy is considered to be a good option because of its few adverse effects and good tolerability profile. It should therefore be borne in mind as an option for pediatric patients, patients with extensive lesions, and patients resistant to topical treatments.^{5,52}

Systemic Treatments

Pentoxifylline

There have been reports of PPD responding to oral pentoxifylline. It has been suggested that pentoxifylline may be effective because it inhibits T-cell adherence to the vascular endothelium by interaction with ICAM-1.^{53,54}

Pentoxifylline has been used alone, at a dose of 400 mg twice or three times daily for 2 to 3 months,^{42,43} or in combination with other drugs such as prostacyclins (prostaglandin I₁)⁵⁵ and oral corticosteroids.⁵⁶ Pentoxifylline has also been found to be ineffective in the treatment of DPPs.⁵⁷

Ascorbic Acid and Bioflavonoids (Rutin/Rutoside)

As ascorbic acid and bioflavonoids increase collagen production, thereby reducing vascular permeability and improving the vascular endothelial barrier function, high doses of vitamin C combined with a flavonoid glycoside (like rutoside/rutin), present in citrus fruits, administered over several months have resulted in clinical improvements and in some cases resolution.⁵⁸

Other Treatments

There have been isolated reports of response to various systemic treatments, such as griseofulvin,⁵⁹ colchicine,⁶⁰ methotrexate,⁶¹ and ciclosporin.⁶²

Conclusions

The DPPs are a common dermatological condition and have a major impact on patient quality of life due to both symptoms and cosmetic concerns. Although the different variants are clinically very similar, there are a number of clinical, histopathologic, and dermoscopic characteristics that help to establish a more specific diagnosis.

Finally, while there is insufficient evidence in the literature to recommend any treatment as a first-line treatment, numerous options exist that can achieve considerable improvements.

Conflicts of Interest

The authors declare that they have no conflicts of interest.

Acknowledgments

We would like to thank Dr. Valero Torres from the Pathology Laboratory of Hospital Clínico Lozano Blesa for his help with the histopathologic analysis.

References

1. Leslie TA. Purpura. In: Griffiths CE, Barker J, Bleiker T, Chalmers R, Creamer D, editors. *Rook's Textbook of Dermatology*, 101, 9th edn. Oxford: John Wiley&Sons; 2016. p. 1–27.
2. Sardana K, Sarkar R, Sehgal VN. Pigmented purpuric dermatoses: an overview. *Int J Dermatol*. 2004;43:482–8.
3. Huang Y-K, Lin C-K, Wu Y-H. The pathological spectrum and clinical correlation of pigmented purpuric dermatosis—A retrospective review of 107 cases. *J CutanPathol*. 2018;45:325–32.
4. Coulombe J, Jean SE, Hatami A, Powell J, Marcoux D, Kokta V, et al. Pigmented purpuric dermatosis: clinicopathologic characterization in a pediatric series. *Pediatr Dermatol*. 2015;32:358–62.
5. Tristani-Firouzi P, Meadows KP, Vanderhooft S. Pigmented purpuric eruptions of childhood: a series of cases and review of literature. *Pediatr Dermatol*. 2001;18:299–304.

6. Taketuchi Y, Chinen T, Ichikawa Y, Ito M. Two cases of unilateral pigmented purpuric dermatosis. *J Dermatol.* 2001;28:493–8.
7. Cho JH, Lee JD, Kang H, Cho SH. The clinical manifestations and etiologic factors of patients with pigmented purpuric dermatoses. *Korean J Dermatol.* 2005;43:45–52.
8. Kaplan R, Meehan SA, Leger M. A case of isotretinoin-induced purpura annularis telangiectodes of Majocchi and review of substance-induced pigmented purpuric dermatosis. *JAMA Dermatol.* 2014;150:182–4.
9. García-Rodiño S, Rodríguez-Granados MT, Seoane-Pose MJ, Espasandín-Arias M, Barbeito-Castiñeiras G, Suárez-Peñaranda JM, et al. Granulomatous variant of pigmented purpuric dermatosis: report of two cases and review of the literature. *J Dtsch Dermatol Ges.* 2017;15:565–9.
10. Ratnam KV, Su WP, Peters MS. Purpura simplex (inflammatory purpura without vasculitis): a clinicopathologic study of 174 cases. *J Am Acad Dermatol.* 1991;25:642–7.
11. Torchio D. Segmental manifestation: a clue to explain the nature of pigmented purpuric dermatoses. *Australas J Dermatol.* 2011;52(3):235.
12. Ghersetich I, Lotti T, Bacci S, Comacchi C, Campanile G, Romagnoli P. Cell infiltrate in progressive pigmented purpura (Schamberg's disease): immunophenotype, adhesion receptors and intercellular relationships. *Int J Dermatol.* 1995;34:846–50.
13. Burrows NP, Jones RR. Cell adhesion molecule expression in capillaritis. *J Am Acad Dermatol.* 1994;31 Pt 1:826.
14. Smoller BR, Kamel OW. Pigmented purpuric eruptions: immunopathologic studies supportive of a common immunophenotype. *J Cutan Pathol.* 1991;18:423–7.
15. Magro CM, Schaefer JT, Crowson AN, Li J, Morrison C. Pigmented purpuric dermatosis: classification by phenotypic and molecular profiles. *Am J Clin Pathol.* 2007;128:218–29.
16. von den Driesch P, Simon M Jr. Cellular adhesion antigen modulation in purpura pigmentosa chronica. *J Am Acad Dermatol.* 1994;30 Pt 1:193–200.
17. Walsh LJ, Trinchieri G, Waldorf HA. Human dermal mast cells contain and release tumor necrosis factor α , which induces endothelial leukocyte adhesion molecule 1. *Proc Natl Acad Sci USA.* 1991;88:4220–4.
18. Glaudy AL, Mirshahi M, Soria G, Soria J. Detection of under-graded fibrin and tumor necrosis factor α in venous leg ulcers. *J Am Acad Dermatol.* 1991;25:623–7.
19. Georgala S, Katoulis AC, Symeonidou S, Georgala C, Vayopoulos G. Persistent pigmented purpuric eruption associated with mycosis fungoides: a case report and review of the literature. *J Eur Acad Dermatol Venereol.* 2001;15:62–4.
20. Ladrigan MK, Poligone B. The spectrum of pigmented purpuric dermatosis and mycosis fungoides: atypical T-cell dyscrasia. *Cutis.* 2014;94:297–300.
21. Guitart J, Magro C. Cutaneous T-cell lymphoid dyscrasia: a unifying term for idiopathic chronic dermatoses with persistent T-cell clones. *Arch Dermatol.* 2007;143:921–32.
22. Viseux V, Schoenlaub P, Cnudde F, Le Roux P, Leroy JP, Plantin P. Pigmented purpuric dermatitis preceding the diagnosis of mycosis fungoides by 24 years. *Dermatology.* 2003;207:331–2.
23. Lipsker D. The pigmented and purpuric dermatitis and the many faces of mycosis fungoides [editorial]. *Dermatology.* 2003;207:246–7.
24. Hanna S, Walsh N, D'Intino Y, Langley RG. Mycosis fungoides presenting as pigmented purpuric dermatitis. *Pediatr Dermatol.* 2006;23:350–4.
25. Kim DH, Seo SH, Ahn HH, Kye YC, Choi JE. Characteristics and clinical manifestations of pigmented purpuric dermatosis. *Ann Dermatol.* 2015;27:404–10.
26. Risikesan J, Sommerlund M, Ramsing M, Kristensen M, Koppelhus U. Successful topical treatment of pigmented purpuric lichenoid dermatitis of Gougerot-Blum in a young patient: a case report and summary of the most common pigmented purpuric dermatoses. *Case Rep Dermatol.* 2017;9:169–76.
27. Zeng YP, Fang K, Ma DL. Lichen aureus: clinicopathological features in a Chinese series. *Eur J Dermatol.* 2016;26:290–4.
28. Rivera-Rodríguez Á, Hernández Ostiz S, Morales-Moya AL, Prieto-Torres L, Álvarez-Salafranca M, Ara Martín M. Zosteriform lichen aureus. Pediatric clinical case. *Arch Argent Pediatr.* 2017;115:e82–4.
29. Moche J, Glassman S, Modi D, Grayson W. Segmental lichen aureus: a report of two cases treated with methylprednisolone aceponate. *Australas J Dermatol.* 2011;52:e15–8.
30. Mishra D, Maheshwari V. Segmental lichen aureus in a child. *Int J Dermatol.* 1991;30:654–5.
31. Lee H, Lee D, Chang S, Lee M, Choi J, Moon K, et al. Segmental lichen aureus: combination therapy with pentoxifylline and prostacyclin. *J Eur Acad Dermatol Venereol.* 2006;20:1378–80.
32. Hoesly FJ, Huerter CJ, Shehan JM. Purpura annularisteliangiectodes of Majocchi: case report and review of the literature. *Int J Dermatol.* 2009;48:1129–33.
33. Hersh CS, Shwayder TA. Unilateral progressive pigmentary purpura (Schamberg's disease) in a 15-year-old boy. *J Am Acad Dermatol.* 1991;24:651.
34. Higgins EM, Cox NH. A case of quadranticapillaropathy. *Dermatologica.* 1990;180:93–5.
35. Abe M, Syuto T, Ishibuchi H, Yokoyama Y, Ishikawa O. Transitory pigmented purpuric dermatoses in a young Japanese female. *J Dermatol.* 2008;35:525–8.
36. Freitas-Martinez A, Martinez-Sanchez D, Moreno-Torres A, Huerta-Brogeras M, Núñez AH, Borbujo J. Angioma serpiginosum: report of an unusual acral case and review of the literature. *Anais Brasileiros de Dermatologia.* 2015;90 3 Suppl 1:26–8.
37. Sangüeza P, Valda L. Eczematide-like purpura (itching purpura-angiodermatitis pruriginosa disseminata). *Med CutanIbero Lat Am.* 1980;8:73–80.
38. Saito R, Matsuoka Y. Granulomatous pigmented purpuric dermatosis. *J Dermatol.* 1996;23:551–5.
39. Sethuraman G, Sugandhan S, Bansal A, DAS AK, Sharma VK. Familial pigmented purpuric dermatoses. *J Dermatol.* 2006;33:639–41.
40. Ackerman AB. Persistent pigmented purpuric dermatitis. In: Ackerman AB, editor. *Histologic Diagnosis of Inflammatory Skin Diseases.* 2nd edn. Blatimore: Williams & Wilkins; 1997. p. 609–13.
41. Zaballos P, Puig S, Malvey J. Dermoscopy of pigmented purpuric dermatoses (lichen aureus): a useful tool for clinical diagnosis. *Arch Dermatol.* 2004;140:1290–1.
42. Ozkaya DB, Emiroglu N, Su O, Cengiz FP, Bahali AG, Yildiz P, et al. Dermoscopic findings of pigmented purpuric dermatosis. *An Bras Dermatol.* 2016;91:584–7.
43. de Giorgi V, Stante M, Massi D, Mavilia L, Cappugi P, Carli P. Possible histopathologic correlates of dermoscopic features in pigmented melanocytic lesions identified by means of optical coherence tomography. *Exp Dermatol.* 2005;14:56–9.
44. Murota H, Katayama I. Lichen aureus responding to topical tacrolimus. *J Cutan Patol.* 2011;38:984–9.
45. Bohm M, Bonsmann G, Luger TA. Resolution of lichen aureus in a 10 year-old child after topical pimecrolimus. *Br J Dermatol.* 2004;151:519–20.
46. Ciudad C, Cano N, Suarez R. Respuesta satisfactoria de la dermatosis purpurica pigmentada al tratamiento con fototerapia. *Actas Dermosifiliogr.* 2013;104:439–49.
47. Seckin D, Yazici Z, Senol A, Demircay Z. A case of Schamberg's disease responding dramatically to PUVA treatment. *Photodermatol Photoimmunol Photomed.* 2008;24:95–6.

48. Milea M, Dimov H-A, Cribier B. Generalized Schamberg's disease treated with PUVA in a child. *Ann Dermatol Venereol*. 2007;134:378–80.
49. Ling TC, Goulden V, Goodfield MJ. PUVA therapy in lichen aureus. *J Am Acad Dermatol*. 2001;45:145–6.
50. Fathy H, Abdelgaber S. Treatment of pigmented purpuric dermatoses with narrow-band UVB: a report of six cases. *J Eur Acad Dermatol Vnereol*. 2011;25:603–6.
51. Karadag AS, Bilgili SG, Onder S, Calka O. Two cases of eczematid-like purpura of Ducas and Kapetanakis responsive to narrow band ultraviolet B treatment. *Photodermatol Photoinmunol Photomed*. 2013;29:97–9.
52. Can B, Turkoglu Z, Kavala M, Zindanci I, Kural E. Successful treatment of generalized childhood Schamberg's disease with narrowband ultraviolet B therapy. *Photodermatol Photoinmunol Photomed*. 2011;27:216–8.
53. Wahba-Yahav AV. Schamberg's purpura: association with persistent hepatitis B surface antigenemia and treatment with pentoxifylline. *Cutis*. 1994;54:205–6.
54. Mun JH, Jwa SW, Song M, Kim HS, Ko HC, Kim BS, et al. Extensive pigmented purpuric dermatosis successfully treated with pentoxifylline. *Ann Dermatol*. 2012;24:363–5.
55. Lee HW, Lee DK, Lee MW, Choi JH, Moon KC, et al. Segmental lichen aureus: combination therapy with pentoxifylline and prostacyclin. *J Eur Acad Dermatol Venereol*. 2006;20:1378–80.
56. Park JH, Kang HY. Generalized Schamberg disease in a child. *Ann Dermatol*. 2013;25:524–5.
57. Basak PY, Erguin S. Should pentoxifylline be regarded as an effective treatment for Schamberg's disease? *J Am Acad Dermatol*. 2001;44:548–9.
58. Schober SM, Peitsch WK, Bonsmann G, Metze D, Thomas K, Goerge T, et al. Early treatment with rutoside and ascorbic acid is highly effective for progressive pigmented purpuric dermatosis. *J Dtsch Dermatol Ges*. 2014;12:1112–9.
59. Tamaki K, Yasaka N, Osada A, Shibagaki N, Furue M. Successful treatment of pigmented purpuric dermatosis with griseofulvin. *Br J Dermatol*. 1996;134:180–1.
60. Geller M. Benefit of colchicine in the treatment of Schamberg's disease. *Ann Allergy Asthma Immunol*. 2000;85, 246-246.
61. Hoesly FJ, Huerter CJ, Shehan JM. Purpura annularis telangiectoides of Majocchi: case report and review of the literature. *Int J Dermatol*. 2009;48:1129–33.
62. Rallis E, Verros C, Moussatou V, Sambaziotis D, Papadakis P. Generalized purpuric lichen nitidus. Report of a case and review of the literature. *Dermatol Online J*. 2007;13:5.