


Prospective Study



Occipital Nerve Stimulation for Refractory Chronic Migraine: Results of a Long-Term Prospective Study

Dolores Rodrigo, PhD, Pilar Acín, PhD, and Pedro Bermejo, PhD

From: Hospital Clinico
Universitario Lozano
Blesa, Zaragoza,
Zaragoza Spain

Address

Correspondence:
Dolores Rodrigo, PhD
hospital Clinico
Universitario Lozano
Blesa, Pain Clinic
Avenida San Juan
Bosco 15
Zaragoza, Spain 50009
E-mail: mdrodrigo@
salud.aragon.es

Disclaimer: There was
no external funding in
the preparation of this
manuscript.

Conflict of interest:
Each author certifies
that he or she, or a
member of his or her
immediate family, has no
commercial association
(i.e., consultancies,
stock ownership, equity
interest, patent/licensing
arrangements, etc.) that
might pose a conflict of
interest in connection
with the submitted
manuscript.

Manuscript received:
03-22-2016

Revised manuscript
received: 06-02-2016

Accepted for publication:
06-14-2016

Free full manuscript:
www.
painphysicianjournal.
com

Background: Refractory chronic migraine affects approximately 4% of the population worldwide and results in severe pain, lifestyle limitations, and decreased quality of life. Occipital nerve stimulation (ONS) refers to the electric stimulation of the distal branches of greater and lesser occipital nerves; the surgical technique has previously been described and has demonstrated efficacy in the treatment of a wide variety of headache disorders.

Objectives: The aim of this study is to evaluate the long-term efficacy and tolerability of ONS for medically intractable chronic migraine.

Study Design: Prospective, long-term, open-label, uncontrolled observational study.

Setting: Single public university hospital.

Methods: Patients who met the International Headache Society criteria for chronic migraine, all of them having been previously treated with other therapeutic alternatives, and who met all inclusion and exclusion criteria for neurostimulation, received the implantation of an ONS system after a positive psychological evaluation and a positive response to a preliminary occipital nerve blockage. The implantation was performed in 2 phases: a 10 day trial with implanted occipital leads connected to an external stimulator and, if more than 50% pain relief was obtained, permanent pulse generator implantation and connection to the previously implanted leads. After the surgery, the patients were thoroughly evaluated annually using different scales: pain Visual Analogue Scale (VAS), number of migraine attacks per month, sleep quality, functionality in social and labor activities, reduction in pain medication, patient satisfaction, tolerability, and reasons for termination. The average follow-up time was 9.4 ± 6.1 years, and 31 patients completed a 7-year follow-up period.

Results: Thirty-seven patients were enrolled and classified according to the location and quality of their pain, accompanying symptoms, work status, and psychological effects. Substantial pain reduction was obtained in most patients, and the VAS decreased by 4.9 ± 2.0 points. These results remained stable over the follow-up period. Five of the 35 permanently implanted patients with migraine attacks at baseline were free from these attacks at their last visits, whereas the pain severity decreased 3.8 ± 2.5 (according to the VAS) in the remaining patients. Seven of the 35 permanent implanted devices were definitively removed: 2 devices because of treatment inefficacy, and 5 devices because the patients were asymptomatic and considered to be cured from their pain, even with the stimulation off. Systemic side effects were not observed.

Limitations: Limitations of the current study include its uncontrolled and open-label design. Additionally, not all patients completed the 7-year follow-up period.

Conclusions: We consider that the trigemino-cervical autonomous and cervical connection may explain why ONS might relieve chronic migraine pain, but this is just a theoretical explanation which should be demonstrated in future studies. The results achieved in this study suggest that ONS may provide long-term benefits for patients with medically intractable chronic migraine. These outcomes are slightly better than previous reports and were maintained over the 7-year follow-up. We believe that an accurate selection of patients, realization of diagnostic occipital nerve blocks, psychological evaluations, rigorous surgical technique, and appropriate parameter programming helped us achieve these outcomes.

Key words: Refractory chronic migraine, headache, occipital nerve stimulation, peripheral nerve stimulation, occipital nerve block

Pain Physician 2017; 20:E151-E159

Refractory chronic migraine (RCM) affects approximately 4% of the population worldwide and results in severe pain, lifestyle limitations, and decreased quality of life. It also affects the quality and quantity of an individual's work and results in a significant economic burden (1,2). Although a number of treatments have been approved to treat chronic migraine, there are still many patients suffering from RCM; thus, other treatments are warranted.

Occipital nerve stimulation (ONS) was initially introduced in 1999 as a therapeutic option to treat pain in refractory patients (3). Although its utility was first described in several small studies, larger studies have been published, and ONS has demonstrated efficacy in the treatment of a wide variety of headache disorders, such as chronic and episodic migraine, cluster headache, occipital neuralgia, trigeminal neuralgia, hemi-crania continua, and posttraumatic headache (4-6). Furthermore, this technique appears to be safe and well tolerated by patients; therefore, the number of treated patients is rapidly increasing. ONS refers to the electric stimulation of the distal branches of greater and lesser occipital nerves by means of fixed-frequency electric pulses; the surgical technique has previously been described (7-9).

Recently, other neurostimulation techniques have emerged as promising treatments for patients with disabling and intractable headaches. An increasing number of studies have suggested that several nerves could be used as a therapeutic target to treat headache disorders, such as the occipital, vagus, sphenopalatine ganglion, and supraorbital nerves (10-12). New non-invasive devices that target these peripheral structures are under development, and the initial experiences have been described. However, long-term studies remain scarce.

The aim of this study is to evaluate the long-term efficacy and tolerability of ONS for medically intractable chronic migraine.

METHODS

After having been diagnosed and referred to our unit by the hospital's Neurology Service, patients who met the International Headache Society criteria (13) for chronic migraine were included in this study. Although these criteria were published in 2004, all of them were also valid for patients previously enrolled in our study. All patients had been previously treated with other therapeutic alternatives, such as pharmacological drugs, denervation, or physiotherapy, with

poor responses (i.e., an absence of efficacy or the presence of important adverse events). The exclusion criteria included pregnancy, age younger than 18 years or older than 80 years, structural lesions (identified by brain imaging), underlying disorders capable of causing headache, medication overuse, and informed consent refusal. Additionally, all patients met the following inclusion criteria: integrity of the nerve structures that require stimulation, willingness and ability to manage the neurostimulation devices, and absence of other implanted electrical stimulation devices. All patients underwent a psychological evaluation to rule out other psychiatric disorders and to confirm that they would be able to accept the device implantation. All procedures were performed with ethical approval from our institutional review board, and written consent was obtained from all patients.

Prior to the ONS implantation, a preliminary occipital nerve blockage was performed with a local anesthetic (lidocaine 1%, svedocain 0.25%), and only the patients who demonstrated good responses (at least 50% relief according to the visual analogue scale [VAS]) were selected for permanent ONS.

The first phase included subcutaneous electrode placement at the cervical/occipital junction at the extracranial exit of the greater and lesser occipital nerves, according to the technique first described by Popeney and Aló in 2003 (14). A 15 G Tuohy needle was introduced in a subcutaneous plane above the muscular fascia from the midline of C1 in the direction of the mastoid. The electrode was inserted, and an intraoperative external stimulation test was performed in order to achieve pleasant paresthesia spreading at least 10 cm along the occipital nerve(s). In order to avoid discomfort or pain commonly associated with lead anchoring elements implanted at high dorsal or cervical levels, leads were fixated to the muscular fascia with silk suture by means of several crosses and knots applied around the lead, in the same way as with Redon drains (Fig. 1). In all patients, electrode placements were radiologically controlled (Fig. 2).

Patients were evaluated after an average period of 10 days, and only those with a greater than 50% decrease in VAS were selected for the permanent implant. Since 2007, all patients have been implanted with double sets of leads, regardless of their uni- or bilateral pain distribution, after the potential complications of single occipital lead use were described (15).

The permanent system implantation was performed in a second surgical phase. The leads were kept

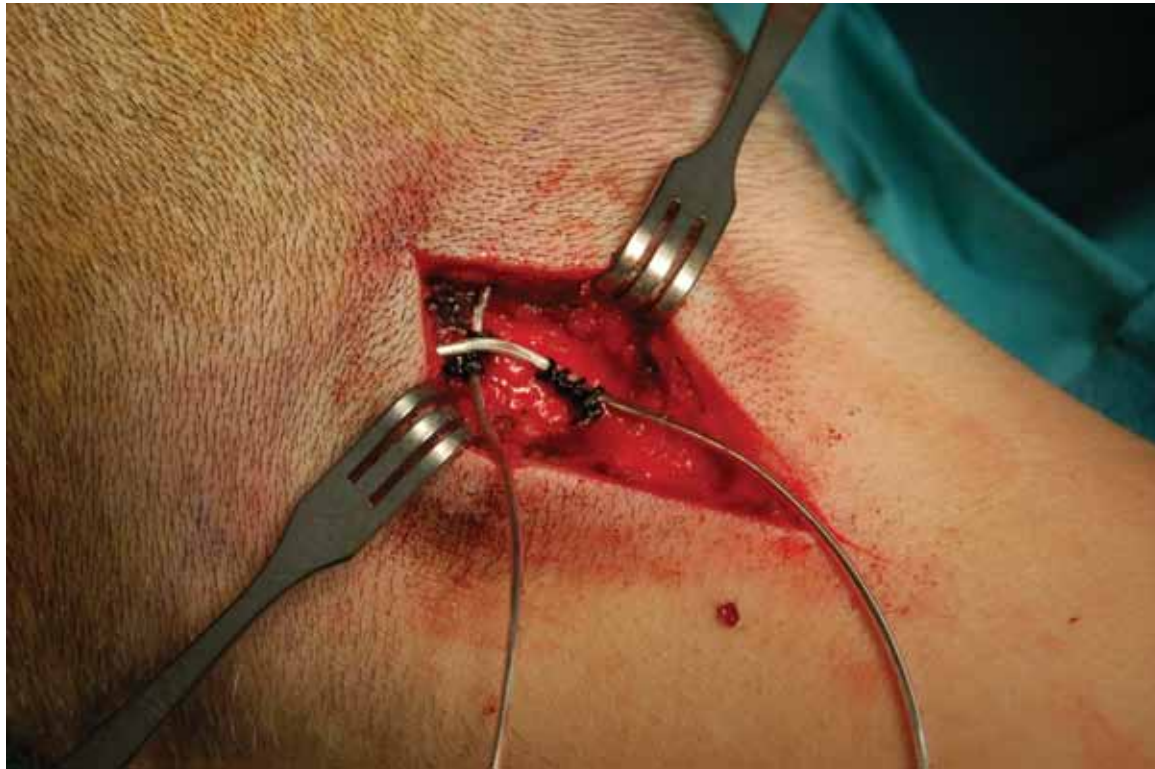

Fig. 1. *Anchoring technique.*

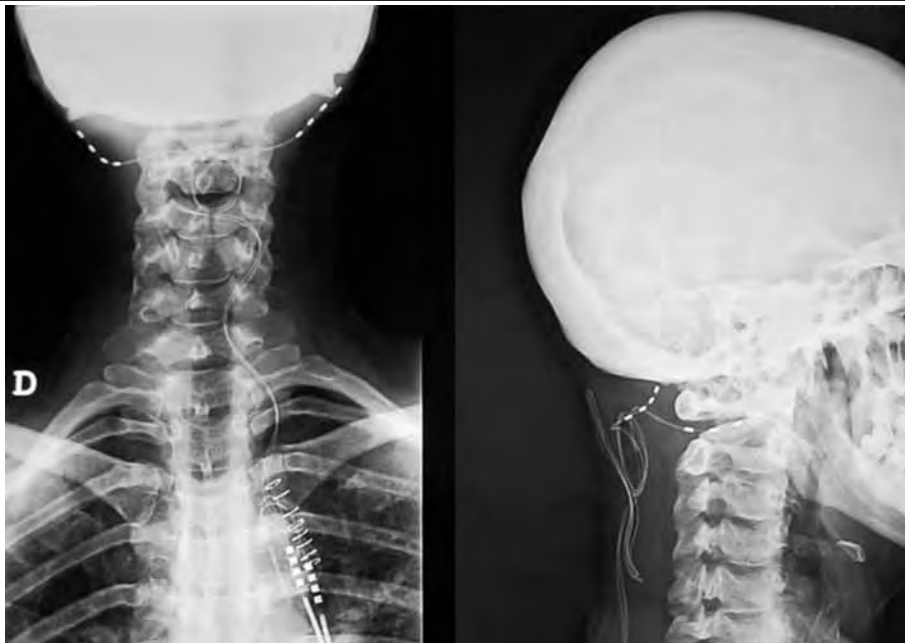


Fig. 2. *Suboccipital subcutaneous placement of the bilateral four-pole leads.*

in place after the trial, and only the intermediate extension was replaced during the final implantation of the pulse generator.

The following stimulation devices were used, with the corresponding extension cables: Pisces Quad and Octad percutaneous leads and Itriel 3, Synergy, Synergy Versitrel, and Prime Advanced pulse generators (all from Medtronic Inc., Minneapolis, MN, USA). One patient was initially implanted with a surgical quadripolar plate lead (Resume, Medtronic); however, effective paresthesia could not be attained, and the lead was replaced by a percutaneous lead. The patients were allowed to continue analgesics and other medications for migraine, including abortive and preventive therapies.

The stimulator was programmed to create a pleasant paresthetic sensation spreading throughout the occipital region. After seeking the best polarity combination (usually one or 2 bipoles in each stimulation lead), initial parameter programming was performed at 40 Hz pulse frequency and 250 μ s pulse width. Perception and discomfort pulse amplitude limits were fixed and the patients were taught to handle their patient programmers. Regardless of the uni- or bilateral migraine symptoms, since 2007 all patients were stimulated bilaterally, either with a single stimulation program or – if left and right stimulation thresholds differed significantly – independent stimulation by means of 2 simultaneous programs. During the follow-up, voltage values were modified when necessary to adapt to threshold changes, and pulse frequencies and widths were set to regulate the paresthesia quality and coverage respectively.

After the ONS surgery, the patients were thoroughly evaluated annually using different scales: the VAS, number of migraine attacks per month, sleep quality (normal, bad, very bad), functionality in social and labor activities (%), reduction in pain medication (including abortive and preventive drugs), patient satisfaction (very satisfied, satisfied, neither satisfied nor unsatisfied, unsatisfied, very unsatisfied), tolerability, and reasons for termination.

RESULTS

Forty-one consecutive patients diagnosed with CRM by our hospital's Neurology Service and referred to our pain unit were initially selected for ONS. In 4 patients (one man, 3 women) the diagnostic nerve block did not produce significant relief so they were excluded from the study.

Thirty-seven patients (4 men and 33 women) were finally enrolled. All surgical and follow-up procedures

were performed in Zaragoza University Hospital between June 2002 and June 2013. The average patient age was 46.9 ± 10.4 years (range, 27 – 74 years); the pain primarily affected different areas: frontal (86%), parietal (83%), temporal (80%), retroocular and facial (58%), and supraclavicular (14%). Thirty-five patients (95%) suffered continuous pain (mean VAS, 5.5 ± 1.8), whereas 36 patients had sporadic migraine seizures (mean VAS, 9.1 ± 0.64). The only 2 patients without continuous pain suffered from severe migraine attacks (mean VAS, 10.0 ± 0.0). The only patient without migraine seizures scored 7 on the VAS. The patients described pain as oppressive (92%) and pulsating (68%), and some patients also reported photophobia or phonophobia (71%), nausea (68%), vascular symptoms (46%), dysesthesia (30%), allodynia (30%), itching (24%) and paresthesia (22%), swelling (22%), vertigo (16%), and trigeminal pain (5%). Twenty-four of the 37 patients were working, and 17 patients (72%) reported decreased productivity. Twenty-seven patients (73%) were depressed.

Only one of the 37 patients selected for ONS did not demonstrate a good response in the first phase of the study; thus, he did not undergo the permanent implantation. This patient had unilateral right pain without an extra-cranial component and had been implanted with a single quadripolar percutaneous lead. The other 36 patients were implanted with permanent systems (Table 1).

The average follow-up time was 9.4 ± 6.1 years, and 31 patients completed a 7-year follow-up period.

Substantial pain reduction was obtained in most patients, and the VAS decreased by 4.9 ± 2.0 points. These results remained stable over the entire follow-up period (Fig. 3). Five of the 35 permanently implanted patients with migraine attacks at baseline were free from these attacks at their last visits, whereas the pain severity decreased 3.8 ± 2.5 (according to the VAS) in the remaining patients.

The number of migraine days per month also decreased from 17.9 ± 0.1 at baseline to 7.3 ± 7.2 at the last visit, and no important differences were identified throughout the 7-year follow-up period.

Thirty-one of the 35 patients experienced a greater than 50% reduction in migraine frequency, whereas this decrease was less than 50% in 3 patients; only one of the 35 patients did not obtain any relief. Three patients with limited responses in migraine severity obtained an important decrease in migraine frequency.

Other symptoms also improved after the ONS

Table 1. Pain distribution and type of permanent implants.

Pain Distribution	N	Lead Configuration	Permanent Generator
Unilateral, Right	4	1 Double Quadripolar 3 Double Octapolar	1 Versitrel 3 Prime Advanced
Unilateral, Left	4	1 Single Quadripolar 2 Single Octapolar 1 Double Octapolar	1 Itrel 3 2 Versitrel 1 Prime Advanced
Bilateral	28	8 Double Quadripolar 19 Double Octapolar	1 Synergy 7 Versitrel 20 Prime Advanced

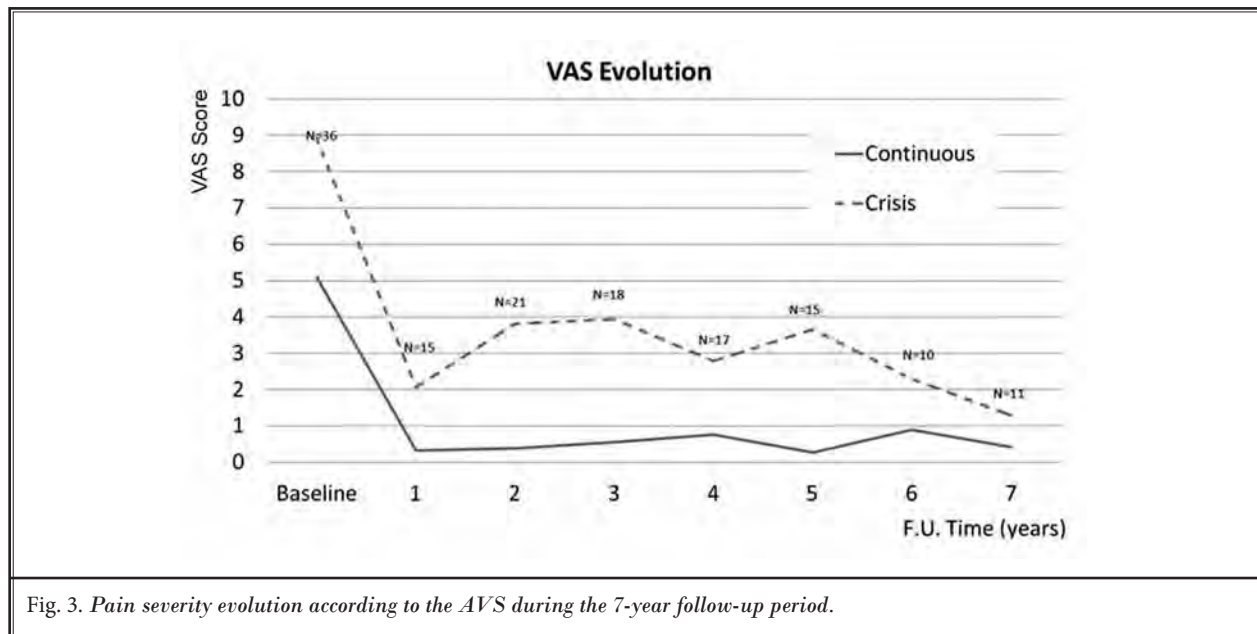


Fig. 3. Pain severity evolution according to the AVS during the 7-year follow-up period.

treatment (Fig. 4). Vertigo disappeared in 6 of 6 patients who suffered from it at baseline, and vascular symptoms also disappeared in 15 of 16 patients. The only patient who reported continued edema during his seizures was the same patient who demonstrated no response after the ONS treatment.

Family and social activities also substantially improved after treatment and remained stable over the 7-year follow-up period. Social activities changed from 64.4 ± 21.6% at baseline to 95.3 ± 12.3%, whereas 31 patients scored 100%. Following on from this subject, 4 patients changed from 37.5% to 65% (average values), and one patient did not demonstrate any improvement in this respect. In terms of work, 14 of 17 patients returned to their jobs.

Sleep quality also improved and remained stable over the 7-year follow-up period. At baseline, the sleep

quality was considered normal for only 3 patients, bad for 25 patients (71%), and very bad for 7 patients (20%). However, at the last visit, the sleep quality changed to normal in 32 patients (91%), and only 3 patients continued to report bad or very bad sleep quality.

Concomitant oral medication use was also reduced. The average number of concomitant drugs was reduced from 4.4 ± 1.7 at baseline to 1.3 ± 1.6 at the last follow-up visit. Fourteen patients (40%) did not take any analgesic medications.

The ONS treatment was generally well tolerated. Two patients complained of painful stimulation, which was solved by reprogramming. There were 4 cases of lead externalization. In one case, the explanted lead was contralateral to the pain, and it was not re-implanted because the patient continued to significantly improve. In the other 3 patients, the whole system was

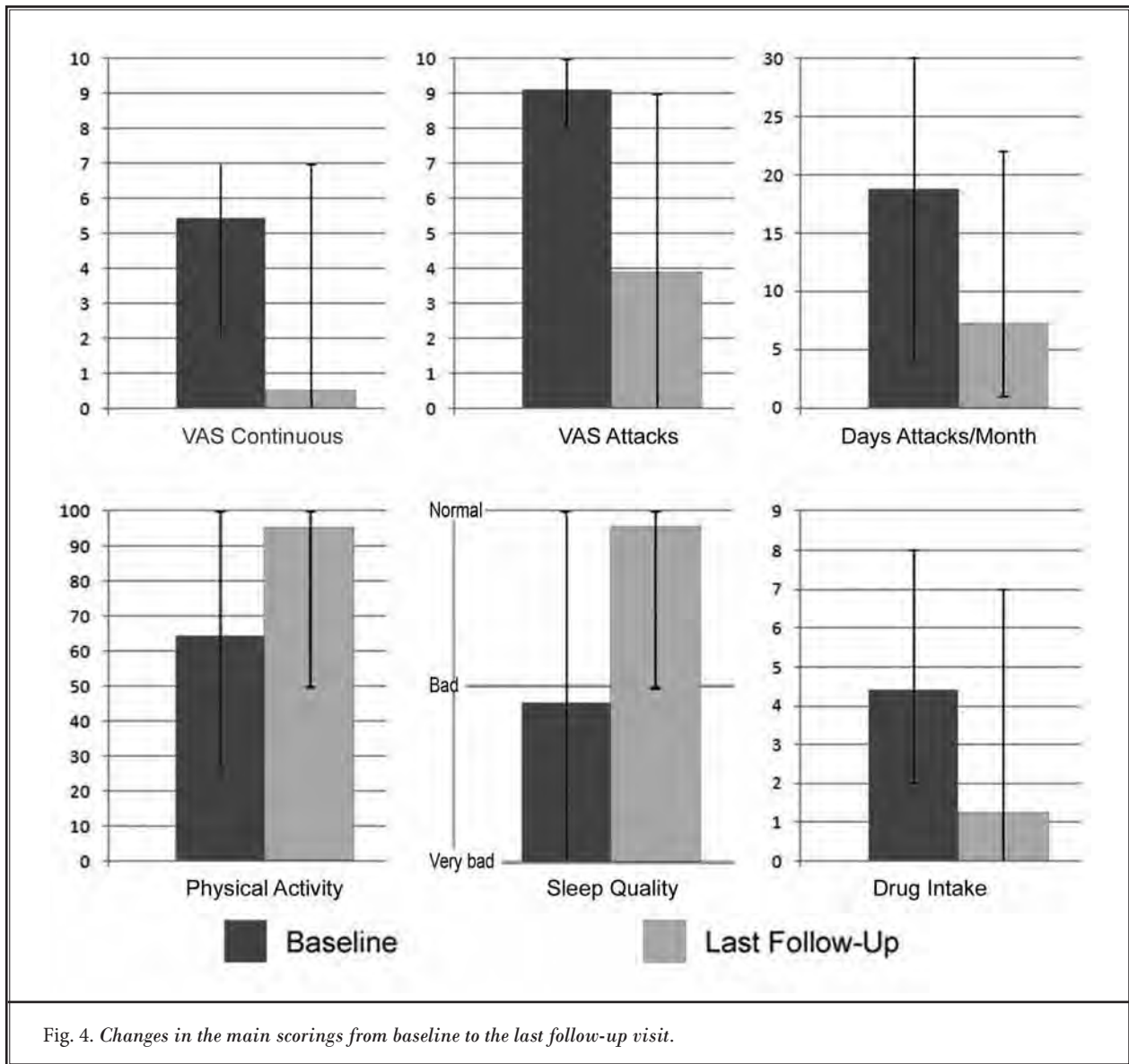


Fig. 4. Changes in the main scorings from baseline to the last follow-up visit.

explanted, one because of inefficacy and 2 because the patients were asymptomatic and reported significant pain relief without stimulation after 4 and 8 years of treatment. In one patient, there was a lead migration during the test phase, and the lead was surgically relocated during the permanent implantation.

There were 3 cases of infection, which all occurred in the generator pocket. One lead was surgically replaced; in the other 2 cases, the complete system was explanted because the patients were considered to be cured after 4 and 8 years of treatment.

Seven of the 35 permanent implanted devices were

definitively removed: 2 devices were removed because of treatment inefficacy, and 5 devices were removed because the patients were asymptomatic and considered to be cured from their pain, even with the stimulation off. Systemic side effects were not observed.

During the entire follow-up, 2 implanted generators reached their end-of-life and required replacement: one Synergy was replaced after 8 years, and one Versitrel was replaced after 3 years of lifetime service. This unusually long service lifetime is likely because of the low energy requirements, particularly the daily usage time of the system. See Table 2 for programming

and usage details.

Discussion

The results of this study suggest that ONS may provide long-term benefits for patients with medically intractable chronic migraine. Most patients experienced important improvements in some of the studied areas, such as migraine severity, frequency, sleep quality, concomitant medication intake, or social or work activities. These long-term outcomes are noteworthy, particularly because at our institution, only severe and refractory patients are referred for ONS, and the results remained stable for the entire 7-year follow-up period.

Since this technique was first reported by Weiner and Reed in 1999 (3), an increasing number of publications have confirmed and continue to confirm its usefulness in the treatment of chronic migraine and other medically intractable headaches. Therefore, the tendency of this treatment modality is towards a progressive increase, both in the number of cases treated and its therapeutic possibilities.

Popeney and Aló (14) confirmed the role of ONS in the treatment of medically intractable chronic migraine in a study of 25 patients over an 18.3-month follow-up period; 64% of the patients in the study improved by at least 50%. Other studies have also demonstrated the efficacy and good tolerability of ONS for chronic migraine (16-23).

However, there are few long-term reports of ONS. Brewer et al (24) conducted a retrospective review of the medical records of 14 patients who were implanted, followed by phone interviews. According to their results, ONS was successful in 5 of the 12 migraine patients, 4 of the 5 patients with cluster headaches, and 5 of the 8 miscellaneous headache patients. Palmisani et al (25) published a 6-year retrospective review of ONS for the treatment of different refractory headache syndromes in 25 patients. They also confirmed the long-term ONS success rate in refractory chronic headaches and suggested that some types of headaches may respond better to ONS than other types. To the best of our knowledge, our study is the largest study to investigate the long-term efficacy and tolerability of ONS for medically intractable chronic migraine. Our results support the use of ONS as a long-term treatment for these patients, as well as the idea that treatment efficacy remains stable throughout the 7-year follow-up period.

The mechanisms of action of peripheral nerve stimulation in the treatment of chronic migraine re-

Table 2. Average, minimum and maximum program settings and the patient's use of the system.

Settings/Parameters	Average	Min	Max
N° Simultaneous Programs	1.45	1	2
Pulse Amplitude (V)	1.89	0.8	3.7
# of Active Cathodes	1.91	1	6
# of Active Anodes	1.36	1	6
Pulse Width (μ s)	286.4	210	450
Pulse Frequency (Hz)	43.1	30	60
Daily Usage Time Initial (h)	12.0	2.0	24.0
Daily Usage Time Final (h)	4.4	0.0	8.0

main unknown; the functional trigeminal-cervical connection proposed by Bartsch et al and Bartsch and Goadsby's findings (26,27) (Fig. 5) has been described as a potential explanation for the pain relief achieved by ONS in chronic migraine patients, although of course this theory must be proven by other studies. Stimuli on trigeminal nociceptors that produce clinical trigeminal and cervical responses (and vice versa) may characterize the mechanisms of trigemino-cervical convergence (28-30).

Another point for discussion is the 2-phase surgery. Some studies have reported that a positive response to occipital nerve block administered prior to ONS predicts a positive response to ONS. However, other studies concerned with proper patient selection have claimed no predictive value in blocking the occipital nerve (31,32). Although this issue requires further investigation, in our study, a prognostic block with a local anesthetic was performed in all patients prior to electrode implantation. Therefore, it remains unknown whether occipital nerve block helped us to better select the patients and obtain better results.

The authors of the study are aware that the results here described are better than other previously published ones. In our opinion, possible causes for this high success rate may include a thorough diagnosis made by the Neurology Service, psychological evaluation ensuring the patients' commitment and ability to operate the system, diagnostic block to discard non-feasible patients, midline technique without anchoring devices, and proper programming, discarding when possible multipolar configurations and focusing on efficient bipole and tripole combinations.

Limitations of the current study include its uncontrolled and open-label design. Additionally, not all patients completed the 7-year follow-up period. Despite

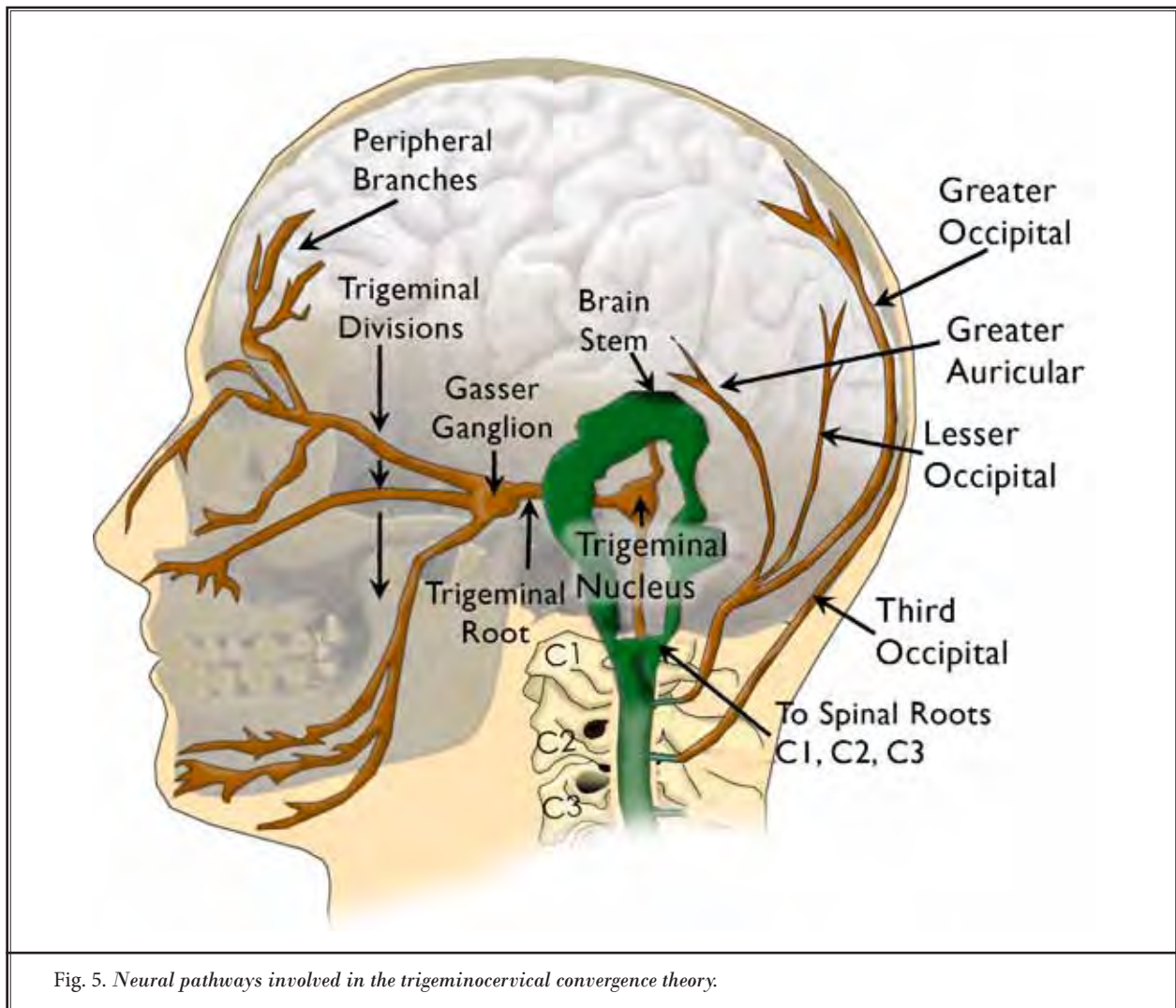


Fig. 5. Neural pathways involved in the trigeminocervical convergence theory.

these limitations, the findings suggest that ONS could be an effective, well-tolerated, long-term treatment for medically RCM. Controlled and larger studies are warranted to confirm these results.

CONCLUSION

Although its mechanisms of action still remain unclear, the outcomes of this study suggest that ONS

might be a safe, effective, and sustainable treatment for refractory chronic migraine.

Conflict of Interest Statement:

The authors of this publication declare that there are no conflicts of interest and that they have not received any funding from any external source for this study.

REFERENCES

1. Lu SR, Fuh JL, Chen WT, Juang KD, Wang SJ. Chronic daily headache in Taipei, Taiwan: Prevalence, follow-up and outcome predictors. *Cephalalgia* 2001; 21:980-986.
2. Wang SJ, Fuh JL, Lu SR, Liu CY, Hsu LC, Wang PN, Liu HC. Chronic daily headache in Chinese elderly: Prevalence, risk factors, and biannual follow-up. *Neurology* 2000; 54:314-319.
3. Weiner RL, Reed KL. Peripheral neurostimulation for the control of intractable occipital neuralgia. *Neuromodulation* 1999; 2:217-221.
4. Magis D, Allena M, Bolla M, De Pasqua V, Remacle JM, Schoenen J. Occipital nerve stimulation for drug-resistant chronic cluster headache: A prospective pilot study. *Lancet Neurol* 2007; 6:314-321.
5. Burns B, Watkins L, Goadsby PJ. Treatment of medically intractable cluster headache by occipital nerve stimulation: Long-term follow-up of eight patients. *Lancet* 2007; 369:1099-1106.
6. Slavin KV, Nersesyan H, Wess C. Peripheral neurostimulation for treatment of intractable occipital neuralgia. *Neurosurgery* 2006; 58:112-119.
7. Rogers LL, Swidan S. Stimulation of the occipital nerve for the treatment of migraine: Current state and future prospects. *Acta Neurochir Suppl* 2007; 97:121-128.
8. Trentman TL, Zimmerman RS. Occipital nerve stimulation: Technical and surgical aspects of implantation. *Headache* 2008; 48:319-327.
9. Rodrigo MD, Quero J, Cía P, Escartín R, Acín P, Bono C, Polo C. Estimulación eléctrica invasiva de C2-C3 en el tratamiento del dolor cefálico y facial: Neuralgia occipital. Migraña transformada. Cefalea en racimos. Algas faciales. *Rev Soc Esp Dolor* 2008; 6:382-391.
10. Lambru G, Matharu MS. Peripheral neurostimulation in primary headaches. *Neurol Sci* 2014; 35:77-81.
11. Goadsby PJ. Neurostimulation in primary headache syndromes. *Expert Rev Neurother* 2007; 7:1785-1789.
12. Goadsby PJ. Neuromodulatory approaches to the treatment of trigeminal autonomic cephalalgias. *Acta Neurochir Suppl* 2007; 97:99-110.
13. Headache Classification Committee. The International Classification of Headache Disorders. 2nd ed. *Cephalalgia* 2004; 24:9-160.
14. Popeney CA, Aló KM. Peripheral neurostimulation for the treatment of chronic, disabling transformed migraine. *Headache* 2003; 43:369-375.
15. Burns B, Watkins L, Goadsby PJ. Treatment of medically intractable cluster headache by occipital nerve stimulation: Long-term follow-up of eight patients. *Lancet* 2007; 369:1099-1106.
16. Schwedt TJ. Occipital nerve stimulation for medically intractable headache. *Curr Pain Headache Rep* 2008; 12:62-66.
17. Schwedt TJ, Dodick DW, Hentz J, Trentman TL, Zimmerman RS. Occipital nerve stimulation for chronic headache – long-term safety and efficacy. *Cephalalgia* 2007; 27:153-157.
18. Saper JR, Dodick DW, Silberstein SD, McCarville S, Sun M, Goadsby PJ. Occipital nerve stimulation for the treatment of intractable chronic migraine headache: ONSTIM feasibility study. *Cephalalgia* 2011; 31:271-285.
19. Trentman TL, Rosenfeld DM, Vargas BB, Schwedt TJ, Zimmerman RS, Dodick DW. Greater occipital nerve stimulation via the Bion microstimulator: Implantation technique and stimulation parameters. Clinical trial: NCT00205894. *Pain Physician* 2009; 12:621-628.
20. Ashkan K, Dowson A. Peripheral occipital nerve stimulation to treat chronic refractory migraine. *Br J Hosp Med (Lond)* 2013; 74:85-89.
21. Silberstein SD, Dodick DW, Saper J, Huh B, Slavin KV, Sharan A, Reed K, Narouze S, Mogilner A, Goldstein J, Trentman T, Vaisman J, Ordia J, Weber P, Deer T, Levy R, Diaz RL, Washburn SN, Mekhail N. Safety and efficacy of peripheral nerve stimulation of the occipital nerves for the management of chronic migraine: Results from a randomized, multicenter, double-blinded, controlled study. *Cephalalgia* 2012; 32:1165-1179.
22. Serra G, Marchioretto F. Occipital nerve stimulation for chronic migraine: A randomized trial. *Pain Physician* 2012; 15:245-253.
23. Dodick DW, Silberstein SD, Reed KL, Deer TR, Slavin KV, Huh B, Sharan AD, Narouze S, Mogilner AY, Trentman TL, Ordia J, Vaisman J, Goldstein J, Mekhail N. Safety and efficacy of peripheral nerve stimulation of the occipital nerves for the management of chronic migraine: Long-term results from a randomized, multicenter, double-blinded, controlled study. *Cephalalgia* 2015; 35:344-358.
24. Brewer AC, Trentman TL, Ivancic MG, Vargas BB, Rebecca AM, Zimmerman RS, Rosenfeld DM, Dodick DW. Long-term outcome in occipital nerve stimulation patients with medically intractable primary headache disorders. *Neuromodulation* 2013; 16:557-562.
25. Palmisani S, Al-Kaisy A, Arcioni R, Smith T, Negro A, Lambru G, Bandikatla V, Carson E, Martelletti P. A six year retrospective review of occipital nerve stimulation practice – controversies and challenges of an emerging technique for treating refractory headache syndromes. *J Headache Pain* 2013; 14:67.
26. Busch V, Frese A, Bartsch T. The trigemino-cervical complex. Integration of peripheral and central pain mechanisms in primary headache syndromes. *Schmerz* 2004; 18:404-410.
27. Bartsch T, Goadsby PJ. The trigemino-cervical complex and migraine: Current concepts and synthesis. *Curr Pain Headache Rep* 2003; 7:371-376.
28. Afridi SK, Shields KG, Bhola R, Goadsby PJ. Greater occipital nerve injection in primary headache syndromes: Prolonged effects from a single injection. *Pain* 2006; 122:126-129.
29. Villanueva L, Le Bars D. The activation of bulbo-spinal controls by peripheral nociceptive inputs: Diffuse noxious inhibitory controls. *Biol Res* 1995; 28:113-125.
30. Piovesan EJ, Di Stani F, Kowacs PA, Mulinari RA, Radunz VH, Utiumi M, Muranka EB, Giublin ML, Werneck LC. Massaging over the greater occipital nerve reduces the intensity of migraine attacks: Evidence for inhibitory trigemino-cervical convergence mechanisms. *Arq Neuropsiquiatr* 2007; 65:599-604.
31. Kapural L, Stillman M, Kapural M, McIntyre P, Guirgus M, Mekhail N. Botulinum toxin occipital nerve block for the treatment of severe occipital neuralgia: A case series. *Pain Pract* 2007; 7:337-340.
32. Kinfe TM, Schuss P, Vatter H. Occipital nerve block prior to occipital nerve stimulation for refractory chronic migraine and chronic cluster headache: Myth or prediction? *Cephalalgia* 2015; 35:359-362.

